

Inflammatory Infiltrate, Microvessel Density, Nitric Oxide Synthase Expression, Vascular Endothelial Growth Factor Expression, and Proliferative Activity in Peri-Implant Soft Tissues Around Titanium and Zirconium Oxide Healing Caps

Marco Degidi,*† Luciano Artese,‡ Antonio Scarano,† Vittoria Perrotti,† Peter Gehrke,§ and Adriano Piattelli‡

Background: The aim of the present study in humans was to conduct a comparative immunohistochemical evaluation of vascular endothelial growth factor (VEGF) and nitric oxide synthase (NOS) expression, inflammatory infiltrate, proliferative activity expression, and microvessel density (MVD) in peri-implant soft tissues of titanium and zirconium oxide healing caps.

Methods: Five patients, three men and two women (aged 30 to 66 years; mean: 49 years), participated in this study. All patients received dental implants that were 3.8 mm in diameter and 11 mm in length. All implants were left to heal in a non-submerged (single-stage) mode. Healing caps (3.8 mm in diameter and 3.0 mm in height) were inserted in all implants. Half of the implants were supplied with standard, pre-fabricated caps of commercially pure titanium, whereas the other half were provided with test zirconium oxide caps. After a 6-month healing period, a gingival biopsy was performed with a circular scalpel (5.5 mm in diameter) around the healing caps of both groups, without unscrewing or removing the healing caps. The dimensions of the gingival biopsies were 1.7 mm (5.5 – 3.8 mm) in thickness and 3 mm in height.

Results: Statistically significant differences were found in the microvessel density between titanium and zirconium oxide healing caps and group II ($P \leq 0.0001$). Statistically significant differences were likewise found in the low and high intensities of NOS1, NOS3, and VEGF ($P \leq 0.0001$). In conclusion, the high intensity of NOS1, NOS3, and VEGF were mostly expressed in the titanium group, whereas the low intensity of NOS1, NOS3, and VEGF were mostly expressed in the zirconium oxide group.

Conclusions: In our specimens, the inflammatory infiltrate was mostly present in the titanium specimens. Their extension was much larger than that of the zirconium oxide specimens. Higher values of MVD were observed in the titanium specimens (29.1 versus 15.8). In addition, a higher expression of VEGF intensity was observed in the peri-implant tissues of titanium healing caps, whereas predominantly lower expressions of VEGF intensity were noted around the zirconium oxide healing caps. The Ki-67 expression was higher in the titanium specimens. All these data revealed that the tissues around titanium healing caps underwent a higher rate of inflammation-associated processes, most probably correlated to the higher inflammation processes observed in these tissues. A higher intensity expression of NOS1 and NOS3 was recorded in the tissues around titanium, whereas, on the contrary, a lower intensity of expression was found in the tissues around zirconium oxide specimens. These latter data indicate that the higher expression of these two mediators could be correlated to the higher amount of bacteria present around the titanium samples. *J Periodontol* 2006;77:73-80.

KEY WORDS

Nitric oxide synthase; vascular endothelial growth factor.

* Private practice, Bologna, Italy.

† Dental School, University of Chieti-Pescara.

‡ Department of Oral Pathology and Medicine, Dental School, University of Chieti-Pescara.

§ Private practice, Ludwigshafen, Germany.

A correlation between plaque accumulation and progressive bone loss around implants has been reported in experimental and clinical studies.¹ Plaque accumulation on implant surfaces or abutments induces an inflammatory reaction within the gingiva and alveolar mucosa in the same manner as around teeth.²⁻⁴ Bacterial infection has also been reported to be one of the possible reasons for implant failure.⁵⁻⁸ The long-term success of oral implants can be jeopardized by either peri-implantitis or occlusal overload.¹ Peri-implantitis is a site-specific, plaque-induced infection leading to progressive bone (hard and soft tissue) loss.⁹⁻¹¹ Pocket formation, radiographic bone destruction, suppuration, swelling, color changes, and bleeding on gentle probing were observed in cases of peri-implantitis.⁹⁻¹¹ Different adhesion affinities of bacteria have been reported for different materials, such as titanium and titanium alloys.¹² Consequently, new ceramic implant abutments have been introduced to improve smile design and long-term esthetic results.¹³⁻¹⁶ Zirconium dioxide abutments and implants are bioinert and display an extremely high component strength, extraordinary bending and tensile strength, and fracture and wear resistance.¹³⁻¹⁶ Zirconium has no cytotoxic effects on fibroblasts. The results of *in vitro* carcinogenicity and teratogenicity tests (cellular chromosome aberrations) were negative. Genotoxicity tests exhibited the absence of aberrations in chromosomal patterns in cells cultured on zirconium plates.¹⁵

The formation of new capillaries due to the budding of endothelial cells is called angiogenesis.¹⁷⁻²⁵ It is a complex process that involves epithelial cell division, selective degradation of vascular basement membranes, surrounding extracellular matrix, and endothelial cell migration.¹⁷⁻²⁵ Angiogenesis is physiologically important for organ development, inflammation, and wound healing. Its role in the development, progression, or healing of periodontal lesions has not been elucidated yet.¹⁷⁻²⁵ In periodontal tissues, angiogenesis seems to be important both for the maintenance of tissue health and in chronic inflammatory periodontal diseases.^{17,19-23} Inflamed tissues seem to enhance the expression of inflammatory mediators, which in turn may promote angiogenesis.¹⁷ Vascular endothelial growth factor (VEGF) has been detected in vascular endothelial cells; inflammatory cells; and junctional, sulcular, and gingival epithelium. It is also implicated in inflammation-associated processes.^{17,20} Ki-67 antigen expression has been detected in the nuclei of proliferating cells in the G1, S, G2, and M phases of the cell cycle, but is absent in quiescent cells (G0 phase).²⁶ Nitric oxide (NO) is a free radical, produced from L-arginine via

isoenzymes named NO synthase (NOS).²⁷ Three different isoforms of NOS are known; the endothelial NOS (eNOS or NOS1) and the neuronal NOS (nNOS or NOS3) are called constitutive because they are expressed essentially and modulated continuously and functionally.²⁷⁻³⁸ The third form is an inducible isoenzyme (iNOS or NOS2). NOS2 is a mediator of the tumoricidal and bactericidal action of macrophages.²⁷⁻³⁸

The aim of the present study in humans was to conduct a comparative immunohistochemical evaluation of VEGF and NOS expression, inflammatory infiltrate, proliferative activity expression, and microvessel density (MVD) in peri-implant soft tissues of titanium and zirconium oxide healing caps.

MATERIALS AND METHODS

Five patients, three men and two women (aged 30 to 66 years; mean: 49 years), participated in the study. The patients were enrolled consecutively from January 2004 to December 2005. The protocol was approved by the Ethics Committee of the University of Chieti-Pescara, Chieti, Italy, and all patients signed an informed written consent. The inclusion criteria were as follows: controlled oral hygiene, absence of any lesions in the oral cavity, sufficient residual bone volume to receive implants of at least 3.8 mm in diameter and 9.5 mm in length, and a wide band of keratinized tissue. In addition, the patients had to agree to participate in a postoperative control program.


The exclusion criteria were as follows: insufficient bone volume, bone quality type 4, high degree of bruxism, smoking more than 20 cigarettes per day, excessive consumption of alcohol, localized radiation therapy of the oral cavity, antitumor chemotherapy, liver diseases, blood diseases, kidney diseases, immunosuppressed patients, patients taking corticosteroids, pregnancy, inflammatory and autoimmune diseases of the oral cavity, and poor oral hygiene. All patients received dental implants[¶] that were 3.8 mm in diameter and 11 mm in length. All implants were left to heal in a non-submerged (single-stage) mode (Fig. 1). Healing caps (3.8 mm in diameter and 3.0 mm in height) were inserted in all implants. Half of the implants were supplied with standard, prefabricated caps of commercially pure titanium,[#] whereas the other half were provided with test zirconium oxide caps** (Fig. 2). The soft tissues were then sutured around the healing caps (Fig. 3).

Patients underwent oral hygiene sessions of scaling and root planing and were enrolled in a strict maintenance program. An additional 10 healing caps (five test and five control) were analyzed with regard to

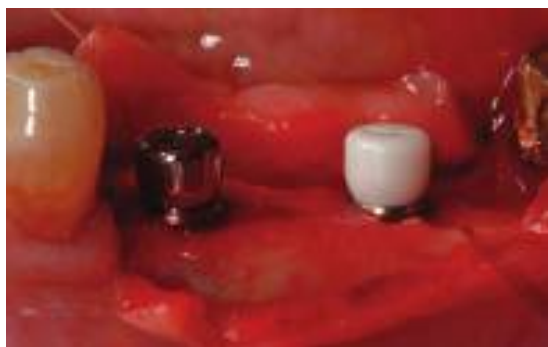¶ XiVE plus, Dentsply Friadent, Mannheim, Germany.

Friadent Gingiva Former, Dentsply Friadent.

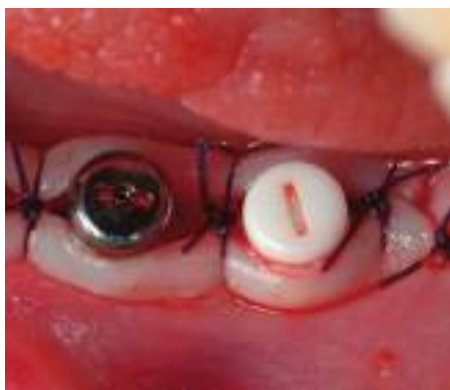** Cercon, Dentsply Friadent.

**Figure 1.**

The implants healed in a non-submerged (single-stage) mode.

**Figure 2.**

Titanium and zirconium healing caps inserted.

**Figure 3.**

The soft tissues sutured around healing caps.

surface characteristics. The surface roughness was evaluated with a scanning electron microscope^{††} and a profilometer.^{‡‡} On average, three readings were performed for each type of surface. The arithmetical mean of surface roughness of every measurement within the total distance (roughness average = R_a)

was assessed. Two areas of 200 μm in diameter were evaluated for each healing cap surface. In each patient, peri-implant crestal bone levels were evaluated by calibrated examination of periapical x-rays. Measurements were recorded after surgery and 6 months after implant placement. They were carried out mesially and distally of each implant, calculating the distance between the edge of the implant and the most coronal point of contact between the bone and the implant. The bone level recorded immediately after implant placement served as a reference point for the subsequent measurements. The values obtained were rounded off to the nearest 0.1 mm. A peak scale loupe with a seven-fold magnifying factor and a scale graduated in 0.1 mm was used. All measurements were made by the same examiner (MD).

After a 6-month healing period, a gingival biopsy was performed with a circular scalpel (5.5 mm in diameter) around the healing caps of both groups, without unscrewing or removing the healing caps (Fig. 4). The dimensions of the gingival biopsies were 1.7 mm (5.5 – 3.8 mm) in thickness and 3 mm in height.

All specimens were immediately fixed in 10% neutral buffered formalin and accordingly embedded in paraffin. Three micron sections were subsequently obtained with a microtome^{§§} and stained with hematoxylin and eosin (H&E).

The immunohistochemical staining of VEGF, factor VIII, NOS1, NOS3, leukocyte common antigen (LCA), CD3, CD20, and Ki-67 was performed.^{|||} Three micron sections were cut and mounted on poly-L-lysine-coated slides. Paraffin sections were dewaxed by xylene, rehydrated, and finally washed in phosphate buffered saline (PBS; pH: 7.4) for 10 minutes. To unmask the antigens, a microwave oven and a 2.1% content of citric acid were related to the antibodies CD3, Ki-67, NOS1, NOS3. It was not necessary to submit the sections to prior treatment. The subsequent steps were optimized by automatic staining.^{¶¶} Sections were incubated with primary antibody for 30 minutes at room temperature. Slides were rinsed in buffer, and immunoreaction was completed^{###**} using a multilink as a secondary biotinylated antibody. After incubation with a chromogen,^{†††} the specimens were counterstained with Mayer's hematoxylin and coverslipped. The VEGF was evaluated in vessels and cells of the inflammatory infiltrate (mainly lymphocytes, plasma cells, and neutrophils) and in stromal cells (fibroblasts). The

†† Leo 435 VP, Leo, Cambridge, U.K.

‡‡ Mitutoyo SurfTest 211, Mitutoyo, Tokyo, Japan.

§§ Leitz 1512 Profilometer, Leitz, Wetzlar, Germany.

||| Streptavidine-Biotine-Peroxidase method, LSAB Kit K675, DakoCytomation, Glostrup, Denmark.

¶¶ Optimax, BioGenex, San Ramon, CA.

Strep-ABC-Peroxidase method, DakoCytomation.

** "Super sensitive immunodetection" kit, BioGenex, San Ramon, CA.

††† Liquid DAB substrate pack, BioGenex.

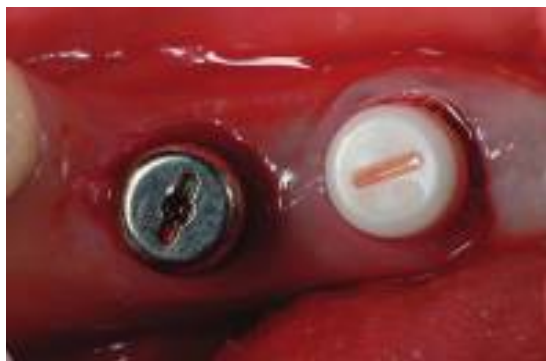

Figure 4.

After 6 months a gingival biopsy was performed.

inflammatory infiltrate, factor VIII, and Ki-67 expressions were evaluated using a semiquantitative analysis: low = +; intermediate = ++; high = +++. The value was considered low (+) in cases less than 10%, intermediate (++) in cases 10% to 50%; and high (+++) in cases where >50% of the cells were positive for the investigated factors. The antibody against the human factor VIII-related antigen was used to highlight the blood microvessels. All the morphologic structures with a lumen surrounded by factor VIII-positive endothelial cells were considered blood microvessels. For the evaluation, counting of the microvessels was performed by a pathologist (LA) in a blind manner. A 200-fold magnification was used, and the individual microvessel profiles were circled to prevent the duplicates or omit counting. For each case, five high power fields (HPF), corresponding to 1.1 mm², were measured. The values were expressed as number of microvessels per square millimeter of peri-implant soft tissues (MVD).

Quantitative analysis was performed for VEGF, NOS1, and NOS3. VEGF was evaluated employing a light microscope^{†††} connected to a high resolution video camera and interfaced to a monitor and PC. This optical system was linked to a digitizing pad and a histometry software package with image capturing capacity.^{§§§} The assessment was carried out at the level of the endothelial cells lining the vessels. Five random fields were chosen for each specimen. After having distinguished two different intensities of the expression of VEGF, low and high, the evaluation was conducted in each field. The intensities were recognized by the PC software as red and yellow, respectively.

Statistical Evaluation

The differences of low and high intensity of NOS1, NOS2, and VEGF were evaluated by analysis of variance (ANOVA) within the four groups of titanium and zirconium. The percentages were expressed as a mean ± SD and SE. Statistically significant differences were set at $P < 0.05$.

RESULTS

In both groups, no clinically visible plaque accumulation, suppuration, or bleeding on probing was present. Probing depth was <3 mm. The surface roughness (Ra) was 0.73 μm for the titanium healing caps and 0.75 μm for the zirconium oxide healing caps. The differences were not statistically significant.

Inflammatory Infiltrate

Titanium. The inflammatory infiltrate mainly consisted of lymphocytes, plasma cells, and histiocytes. Infrequently, granulocytes were observed. The submucosa was widely penetrated by inflammatory infiltrate (Fig. 5A). In some areas, this infiltrate extended above the mucosa, producing microulcerations. Rarely, a few inflammatory cells were present in the muscular tissue. The inflammatory infiltrate was evaluated as +++.

Zirconium oxide. Only a few lymphocytes, plasma cells, and histiocytes were present in the submucosa (Fig. 5B). The inflammatory infiltrate was evaluated as +.

Microvessel Density

Titanium. Many microvessels were present within the submucosa, mainly located in areas with a wider inflammatory infiltrate. The mean number of vessels was 29.1 ± 5.216 (Table 1).

Zirconium oxide. Only a few microvessels were present within the submucosa. The mean number of vessels was 15.8 ± 2.44 (Table 1).

NOS1

NOS1 was expressed in the tissues around titanium and zirconium healing caps. The intensity of the expression, however, was different within the two groups. NOS1 was expressed at the level of superficial epithelium and endothelial vascular cells.

Titanium. It was observed that cells presented a higher intensity of expression (36.5 ± 17.3) than a lower intensity of expression (15.7 ± 9.1) (Fig. 6A; Table 2). This difference was statistically significant ($P = 0.0001$).

Zirconium oxide. Cells presented a prevalently lower intensity of expression (22.1 ± 14.4) than a higher intensity of expression (5.03 ± 5.69) (Fig. 6B; Table 2). This difference was statistically significant ($P = 0.0001$).

NOS3

NOS1 was expressed both in the tissues around titanium and zirconium healing caps, even though the intensity of the expression was different within the two groups. NOS3 was expressed at the level of superficial epithelium and endothelial vascular cells. The

††† Laborlux S, Leitz.

§§§ Image-Pro Plus 4.5, Media Cybernetics, Immagini & Computer, Milan, Italy.

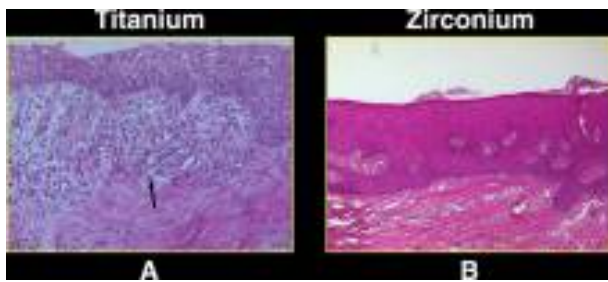


Figure 5. **A)** A severe inflammatory infiltrate is present in the peri-implant soft tissues around titanium healing caps (arrow). **B)** Only a small inflammatory infiltrate is observed around zirconium healing caps. (H&E; original magnification $\times 10$.)

Table 1.
Microvessel Density*

	Mean (mm)	SD	SE
Group I (titanium)	29.1	5.216	1.65
Group II (zirconium)	15.8	2.44	0.7717

* Statistically significant difference between groups ($P \leq 0.0001$).

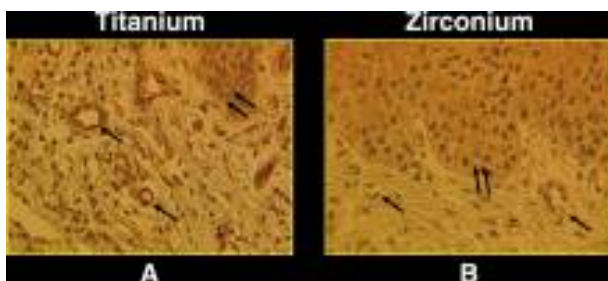


Figure 6. **A)** High positivity of NOS 1 expression at the level of superficial epithelium (double arrows) and vascular endothelial cells (single arrows) in the peri-implant tissues around titanium healing caps. **B)** Low positivity of NOS 1 expression at the level of superficial epithelium (double arrows) and vascular endothelial cells (single arrows) around zirconium healing caps. (Peroxidase-anti-peroxidase [PAP]; original magnification $\times 20$.)

evaluation was performed at the level of the endothelial vascular cells.

Titanium. Cells presented a higher intensity of expression (44.3 ± 8.1) than a lower intensity of expression (8.41 ± 1.0) (Fig. 7A; Table 2). This difference was statistically significant ($P = 0.0001$).

Zirconium oxide. Cells presented a lower intensity of expression (11.2 ± 4.4) than a higher intensity of expression (1.13 ± 0.34) (Fig. 7B; Table 2). This difference was statistically significant ($P = 0.0001$).

Table 2.
Intensity of Expression*

	NOS1	NOS3	VEGF
Group I (titanium) high intensity	36.5 ± 17.3	44.3 ± 8.1	48.9 ± 11.5
Group II (titanium) low intensity	15.7 ± 9.1	8.41 ± 1.1	30.2 ± 8.6
Group III (zirconium) high intensity	5.03 ± 5.69	1.13 ± 0.34	17.1 ± 3.9
Group IV (zirconium) low intensity	22.1 ± 14.4	11.2 ± 4.4	27.8 ± 4.9

* Statistically significant difference between groups ($P = 0.0001$).

VEGF

VEGF was expressed in the tissues around titanium and zirconium healing caps. However, the intensity of the expression differed in the two groups. VEGF was positive in vascular endothelial cells, stromal cells, and inflammatory cells. The evaluation was performed at the level of the endothelial vascular cells.

Titanium. Cells presented a higher intensity of expression (48.9 ± 11.5) than a lower intensity of expression (30.2 ± 8.6) (Figs. 8A and 9A; Table 2). This difference was statistically significant ($P = 0.0001$).

Zirconium oxide. Cells presented a lower intensity of expression (27.8 ± 4.9) than a higher intensity of expression (17.1 ± 3.9) (Figs. 8B and 9B; Table 2). This difference was statistically significant ($P = 0.0001$).

Proliferative Activity

The positivity to Ki-67 was nuclear. The positivity was expressed at the level of the basal and superficial epithelial layers.

Titanium. About 80% of the cells in the basal layer were positive. A Ki-67 positivity was observed also in many cells of the superior epithelial layers (Fig. 10A).

Zirconium oxide. About 20% of the cells of the basal layer were positive to Ki-67. No positivity was observed in the superior layers of the epithelium (Fig. 10B).

Statistical Evaluation

Statistically significant differences were found in the microvessel density between group I and group II ($P \leq 0.0001$; Table 1). Statistically significant differences were likewise found in the low and high intensities of NOS1, NOS3, and VEGF ($P \leq 0.0001$; Table 2). In conclusion, the high intensity of NOS1, NOS3, and VEGF were mostly expressed in the titanium group, whereas the low intensity of NOS1, NOS3, and VEGF were mostly expressed in the zirconium oxide group.

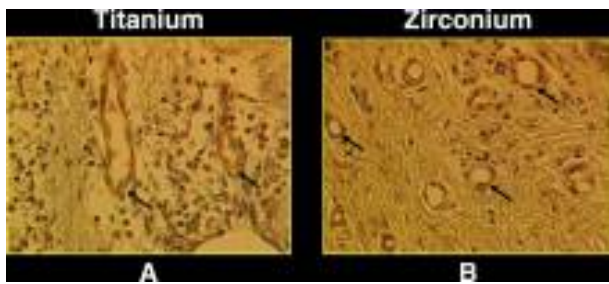


Figure 7.

A) High positivity of NOS3 expression at the level of vascular endothelial cells (arrows) in the peri-implant tissues around titanium healing caps. **B)** Low positivity of NOS3 expression at the level of vascular endothelial cells (arrows) around zirconium healing caps. (PAP; original magnification $\times 20$.)

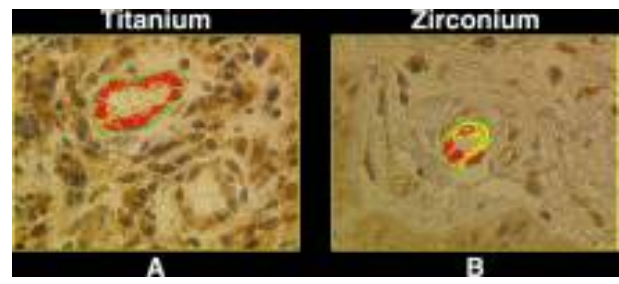


Figure 9.

A) Vascular endothelial cells showing a high intensity of VEGF expression (red) around titanium healing caps. **B)** Vascular endothelial cells showing mainly low intensity of VEGF expression (yellow) around zirconium healing caps. (PAP; original magnification $\times 40$.)

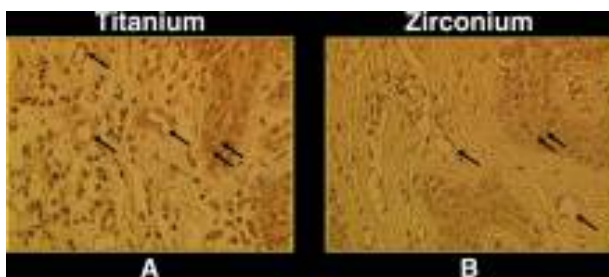


Figure 8.

A) High positivity of VEGF expression at the level of superficial epithelium (double arrows) and vascular endothelial cells (single arrows) in the peri-implant tissues around titanium healing caps. **B)** Low positivity of VEGF expression at the level of superficial epithelium (double arrows) and vascular endothelial cells (single arrows) in zirconium healing caps. (PAP; original magnification $\times 20$.)

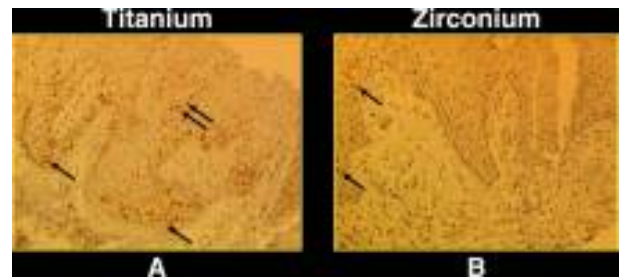


Figure 10.

A) Several Ki-67+ cells present at the level of superficial epithelium in the peri-implant tissues around titanium healing caps, not only in the basal cells (single arrows), but also in the cells of superior layers (double arrows). **B)** Few Ki-67+ cells present at the level of superficial epithelium around zirconium healing caps (only in the basal cells [single arrows]). (PAP; original magnification $\times 10$.)

DISCUSSION

In the study specimens, the inflammatory infiltrate was mostly present in the titanium specimens. Their extension was much larger than that of the zirconium oxide specimens. The inflammatory infiltrate consisted of lymphocytes, plasma cells, and histiocytes. No differences occurred in the number of B-lymphocytes (CD20+) and T-lymphocytes (CD3+).

In all the titanium specimens, the inflammatory infiltrate ulcerated the mucosa. Higher values of MVD were observed in the titanium specimens (29.1 versus 15.8). In addition, a higher expression of VEGF intensity was observed in the peri-implant tissues of titanium healing caps, whereas predominantly lower expressions of the VEGF intensity were noted around the zirconium oxide healing caps. The Ki-67 expression was higher in the titanium specimens. Ki-67+ cells were found in these samples, even in the more superficial epithelial layers. All these data revealed that the tissues around titanium healing caps underwent a higher rate of inflammation-associated pro-

cesses, most probably correlated to the higher inflammation processes observed in these tissues. A higher intensity expression of NOS1 and NOS3 was recorded in the tissues around titanium, whereas, on the contrary, a lower intensity of expression was found in the tissues around zirconium oxide specimens. These latter data indicate that the higher expression of these two mediators could be correlated to the higher amount of bacteria present around the titanium samples.

Surface properties of transgingival implant components are important determinants in bacterial adhesion. The long-term survival of dental implants depends, in part, on the control of bacterial infection in the peri-implant region.³⁹ Bacterial adhesion to implant or abutment surfaces is a critical issue.⁴⁰⁻⁴⁵ It is considered a first stage of peri-implant mucositis and peri-implantitis. A positive correlation has been confirmed between oral hygiene and peri-implant marginal bone loss in the edentulous mandible.^{4,12} Crestal bone loss has been reported to occur within the first year after implant placement. The proximate

cause of this bone loss is unknown, and several hypotheses have been suggested: surgical trauma, overload, peri-implantitis, microgap, reformation of the biologic width, and implant crestal module.^{1,46} Occlusal overload and peri-implantitis are two of the main causative factors for implant failure in later stages.^{1,46} Moreover, a correlation between plaque accumulation and progressive bone loss around implants has been reported in experimental and clinical studies.^{1,46} Surface modifications or the use of different materials have been shown to play a relevant role in the bacterial adhesion of implant surfaces. Grössner-Schreiber et al.⁴⁴ found lower amounts of bacteria on zirconium nitride-coated materials. Rimondini et al.⁴⁵ demonstrated that yttrium-stabilized tetragonal zirconium polycrystals (Y-TZP) accumulated significantly fewer bacteria compared to titanium. Titanium surfaces appeared to be coated uniformly with a structured biofilm, whereas zirconium surfaces were colonized by clusters of bacteria.⁴⁵ In a previous study, the authors demonstrated a statistically significant difference of bacterial adhesion on zirconium oxide and titanium surfaces.⁴⁷ This is considered to be of decisive importance for peri-implant soft tissue health. Zirconium ceramics appears to be a suitable material for manufacturing implant abutments with a low colonization potential. Besides biocompatibility, durability and color conformity are prerequisites for highly esthetic implant restorations. Improved material characteristics, complying with clinicians' and patients' increased demands for highly esthetic results, have contributed significantly to the development of zirconium-dioxide implant abutments (Y-TZP). Zirconium abutments have been noted for their tooth-analog color and excellent light dynamics.¹⁴ The phenomenon of transformation toughening of zirconium results in extremely high component strength, extraordinary bending and tensile strength, and fracture and chemical resistance. Its polymorphism provides three different crystal conditions, even if the chemical composition is identical. For this reason, zirconium has been reported to have "self-repairing" properties, preventing crack propagation.¹⁵

Angiogenesis is a process in which new blood vessels are produced by sprouting from established vessels.¹⁷ An enhanced expression of inflammatory mediators, many of which can promote angiogenesis, were found in inflamed tissues.¹⁷ Angiogenesis also influences the severity of the inflammation as the result of the ability of new blood vessels to transport proinflammatory cells to the lesion and supply nutrients and oxygen to the inflamed tissues.^{15,17}

VEGF is probably involved in the etiology of gingivitis and its progression to periodontitis by an expansion of the vascular network, an increase in tissue edema, and a decrease in the rate of blood flow.^{17,18}

VEGF also seems to be involved in tissue inflammation-associated processes. Yuan et al.⁴⁸ suggested that a lack of VEGF is associated with the regression of pregnancy pyogenic granuloma.

ACKNOWLEDGMENTS

This work was partially supported by the National Research Council (CNR), Rome, Italy, by the Ministry of Education, University, and Research (MIUR), Rome, Italy, and by Research Association for Dentistry and Dermatology (AROD), Chieti, Italy.

REFERENCES

1. Oh TJ, Yoon J, Misch CE, Wang HL. The causes of early implant bone loss: Myth or science. *J Periodontol* 2002;73:322-333.
2. Rasperini G, Maglione M, Cocconcelli P, Simion M. In vivo early plaque formation on pure titanium and ceramic abutments: A comparative microbiological and SEM analysis. *Clin Oral Implants Res* 1998;9:357-364.
3. Bollen CM, Papaioannou W, van Eldere J, Schepers E, Quirynen M, van Steenberghe D. The influence of abutment surface roughness on plaque accumulation and peri-implant mucositis. *Clin Oral Implants Res* 1996;7:201-211.
4. Bollen CM, Lambrechts P, Quirynen M. Comparison of surface roughness of oral hard materials to the threshold surface of bacterial plaque retention: A review of the literature. *Dent Mater* 1997;13:258-269.
5. Becker W, Becker BE, Newman MG, Nyman S. Clinical and microbiologic findings that may contribute to dental implant failure. *Int J Oral Maxillofac Implants* 1990;5:31-38.
6. Piattelli A, Scarano A, Piattelli M. Histologic observations on 230 retrieved dental implants: An 8-year experience (1989-1996). *J Periodontol* 1998;69:178-184.
7. O'Mahony A, MacNeill SR, Cobb CM. Design features that may influence bacterial plaque retention: A retrospective analysis of failed implants. *Quintessence Int* 2000;31:249-256.
8. Drake DR, Paul J, Keller JC. Primary bacterial colonization of implant surfaces. *Int J Oral Maxillofac Implants* 1999;14:226-232.
9. Mombelli A, Lang NP. Microbial aspects of implant dentistry. *Periodontol* 2000 1994;4:74-80.
10. Quirynen M, de Soete M, van Steenberghe D. Infectious risks for oral implants: A review of the literature. *Clin Oral Implants Res* 2002;13:1-19.
11. Esposito M, Hirsch JM, Lekholm U, Thomsen P. Biological factors contributing to failures of osseointegrated oral implants. (II). *Etiopathogenesis. Eur J Oral Sci* 1998;106:721-764.
12. Steinberg D, Sela MN, Klinger A, Kohavi D. Adhesion of periodontal bacteria to titanium and titanium alloy powders. *Clin Oral Implants Res* 1998;9:67-72.
13. Ichikawa Y, Akagawa Y, Nikai H, Tsuru H. Tissue compatibility and stability of a new zirconia ceramic in vivo. *J Prosthet Dent* 1992;68:322-326.
14. Ahmad I. Yttrium-partially stabilized zirconium dioxide posts: An approach to restoring coronally compromised nonvital teeth. *Int J Periodontics Restorative Dent* 1998;18:454-465.
15. Piconi C, Maccauro G. Zirconia as a ceramic biomaterial. *Biomaterials* 1999;20:1-25.

16. Kohal RJ, Weng D, Baechle M, Strub RJ. Loaded custom-made zirconia and titanium implants show similar osseointegration: An animal experiment. *J Periodontol* 2004;75:1262-1268.
17. Unlu F, Guneri PG, Hekimgil M, Yesilbek B, Boyacioglu H. Expression of vascular endothelial growth factor in human periodontal tissues: Comparison of healthy and diabetic patients. *J Periodontol* 2003;74:181-187.
18. Kohno S, Kaku M, Tsutsui K, et al. Expression of vascular endothelial growth factor and the effects on bone remodeling during experimental tooth movement. *J Dent Res* 2003;82:177-182.
19. Yoshino H, Morita I, Murota SI, Ishikawa I. Mechanical stress induces production of angiogenic regulators in cultured human gingival and periodontal ligament fibroblasts. *J Periodontol Res* 2003;38:405-410.
20. Momose M, Murata M, Kato Y, et al. Vascular endothelial growth factor and transforming growth factor- α and - β 1 are released from human cultured gingival epithelial sheets. *J Periodontol* 2002;73:748-753.
21. Johnson RB, Serio FG. Leptin within healthy and diseased human gingiva. *J Periodontol* 2001;72:1254-1257.
22. Oyama T, Sakuda T, Matsushita K, Maruyama I, Nagaoka S, Torii M. Effects of roxithromycin on tumor necrosis factor-alpha-induced vascular endothelial growth factor expression in human periodontal ligament cells in culture. *J Periodontol* 2000;71:1546-1553.
23. Suthin K, Matsushita K, Machigashira M, et al. Enhanced expression of vascular endothelial growth factor by periodontal pathogens in gingival fibroblasts. *J Periodontol Res* 2003;38:90-96.
24. Leonardi R, Caltabiano M, Pagano M, Pezzuto V, Loreto C, Palestro G. Detection of vascular endothelial growth factor/vascular permeability factor in periapical lesions. *J Endod* 2003;29:180-183.
25. Uchida S, Sakai A, Kudo H, et al. Vascular endothelial growth factor is expressed along with its receptors during the healing process of bone and bone marrow after drill-hole injury in rats. *Bone* 2003;32:491-501.
26. Mesa F, Aguilar M, Gonzalez-Moles MA, et al. Vagabatin-induced modification of Ki-67 expression in gingival epithelium: Immunohistochemical study of a short series. *J Periodontol Res* 2004;39:66-71.
27. Batista AC, Silva TA, Chun JH, Lara VS. Nitric oxide synthesis and severity of human periodontal disease. *Oral Dis* 2002;8:254-260.
28. Brennan PA, Thomas GJ, Langdon JD. The role of nitric oxide in oral diseases. *Arch Oral Biol* 2003;48:93-100.
29. Connelly ST, Macabeo-Ong M, Dekker N, Jordan RC, Schmidt BL. Increased nitric oxide levels and iNOS over-expression in oral squamous cell carcinoma. *Oral Oncol* 2005;41:261-267.
30. Kendall HK, Marshall RI, Bartold PM. Nitric oxide and tissue destruction. *Oral Dis* 2001;7:2-10.
31. Kikuri T, Hasegawa T, Yoshimura Y, Shirakawa T, Oguchi H. Cyclic tension force activates nitric oxide production in cultured human periodontal ligament cells. *J Periodontol* 2000;71:533-539.
32. Kim SJ, Ha MS, Choi EY, Chi JI, Choi IS. Nitric oxide production and inducible nitric oxide synthase expression induced by *Prevotella nigrescens* lipopolysaccharide. *FEMS Immunol Med Microbiol* 2005;43:51-58.
33. Daghigh F, Borghaei RC, Thornton RD, Bee JH. Human gingival fibroblasts produce nitric oxide in response to proinflammatory cytokines. *J Periodontol* 2002;73:392-400.
34. Hirose M, Ishihara K, Saito A, Nakagawa T, Yamada S, Okuda K. Expression of cytokines and inducible nitric oxide synthase in inflamed gingival tissue. *J Periodontol* 2001;72:590-597.
35. Kim SJ, Ha MS, Choi EY, Choi JI, Choi IS. Prevotella intermedia lipopolysaccharide stimulates release of nitric oxide by inducing expression of inducible nitric oxide synthase. *J Periodontol Res* 2004;39:424-431.
36. Leitaof RF, Rocha FA, Chaves HV, et al. Locally applied isosorbide decreases bone resorption in experimental periodontitis in rats. *J Periodontol* 2004;75:1227-1232.
37. Lappin DF, Kjeldsen M, Sander L, Kinane DF. Inducible nitric oxide synthase expression in periodontitis. *J Periodontol Res* 2000;35:369-373.
38. Shang ZJ, Li JR. Expression of endothelial nitric oxide synthase and vascular endothelial growth factor in oral squamous cell carcinoma: Its correlation with angiogenesis and disease progression. *J Oral Pathol Med* 2005;34:134-9.
39. Rimondini L, Fare S, Brambilla E, et al. The effect of surface roughness on early *in vivo* plaque colonization on titanium. *J Periodontol* 1997;68:556-562.
40. Quirynen M, Bollen CM. The influence of surface roughness and surface-free energy on supra- and subgingival plaque formation in man. A review of the literature. *J Clin Periodontol* 1995;22:1-14.
41. Quirynen M, van der Mei HC, Bollen CM, et al. An *in vivo* study of the influence of the surface roughness of implants on the microbiology of supra- and subgingival plaque. *J Dent Res* 1993;72:1304-1309.
42. Heydenrijk K, Meijer HJA, van der Reijden WA, Raghoobar GM, Vissink A, Stegenga B. Microbiota around root-form endosseous implants: A review of the literature. *Int J Oral Maxillofac Implants* 2002;17:829-838.
43. Quirynen M, Bollen CML, Papaioannou W, van Eldere J, van Steenberghe D. The influence of titanium abutments surface roughness on plaque accumulation and gingivitis: Short-term observations. *Int J Oral Maxillofac Implants* 1996;11:169-178.
44. Grössner-Schreiber B, Griepentrog M, Haustein I, et al. Plaque formation on surface modified dental implants: An *in vitro* and *in vivo* study. *Clin Oral Implants Res* 2001;12:543-551.
45. Rimondini L, Cerroni L, Carrassi A, Torricelli P. Bacterial colonization of zirconia ceramic surfaces: An *in vitro* and *in vivo* study. *Int J Oral Maxillofac Implants* 2002;17:793-798.
46. Oh TJ, Yoon J, Misch CE, Wang HL. The causes of early implant bone loss: myth or science? *J Periodontol* 2002;73:322-333.
47. Scarano A, Piattelli M, Caputi S, Favero GA, Piattelli A. Bacterial adhesion on c.p. titanium and zirconium oxide discs: An *in vivo* human study. *J Periodontol* 2004;75:292-296.
48. Yuan K, Jin YT, Lin MT. The detection and comparison of angiogenesis-associated factors in pyogenic granuloma by immunohistochemistry. *J Periodontol* 2000;71:701-709.

Correspondence: Dr. Adriano Piattelli, Via F. Sciucchi 63, 66100 Chieti, Italy. Fax: 39-0871-3554076; e-mail: apiattelli@unich.it.

Accepted for publication June 8, 2005.