

Turnover flap variations in the reconstruction of full-thickness nasal ala defects

Paola Monari,¹ Alessandra Petruzzellis,² Sara Mezzana,¹ Simone Soglia,¹ Pier Giacomo Calzavara-Pinton,¹ Luca Bianchi,² Giulio Gualdi³

¹Department of Dermatology, ASST Spedali Civili di Brescia, University of Brescia; ²Dermatology Unit, Policlinico Tor Vergata, University of Rome Tor Vergata; ³Dermatologic Clinic, Department of Medicine and Aging Science, University G. D'Annunzio Chieti-Pescara, Pescara, Italy

Abstract

The nose is a vital organ and an important aesthetic unit, being placed in the middle of the face. It is also one of the most frequent site involved by skin cancer, and surgical reconstruction can be sometimes challenging. We present two cases of full thickness nasal ala defects, managed with turnover flaps with and without earlobe cartilage graft.

Correspondence: Paola Monari, Department of Dermatology, ASST Spedali Civili di Brescia, University of Brescia, Italy.
Tel.: +39.0303995302.
E-mail: paola.monari@libero.it

Key words: turnover flap; nasal ala defect; dermatologic surgery.

Contributions: all the authors contributed equally.

Conflict of interest: the authors declare no potential conflict of interest.

Ethics approval and consent to participate: No ethical committee approval was required for this case report by the Department, because this article does not contain any studies with human participants or animals. Informed consent was obtained from the patient included in this study.

Consent for publication: the patients gave their written consent to use their personal data for the publication of this case report and any accompanying images.

Availability of data and materials: all data underlying the findings are fully available.

Received: 9 September 2023.

Accepted: 5 October 2023.

This work is licensed under a Creative Commons Attribution-NonCommercial 4.0 International License (CC BY-NC 4.0).

©Copyright: the Author(s), 2024
Licensee PAGEPress, Italy
Dermatology Reports 2024; 16:9848
doi:10.4081/dr.2024.9848

Publisher's note: all claims expressed in this article are solely those of the authors and do not necessarily represent those of their affiliated organizations, or those of the publisher, the editors and the reviewers. Any product that may be evaluated in this article or claim that may be made by its manufacturer is not guaranteed or endorsed by the publisher.

Introduction

The nose is a vital organ for breathing, smelling, and speaking. It is made up of several subunits, including the dorsum, tip, alae, sidewalls, and soft triangles, each separated by convex and concave surfaces. The nasal wing consists of three-layers: the innermost mucosal layer, the outermost skin layer, and the intervening cartilage layer.¹

A retrospective study conducted at Spedali Civili of Brescia revealed that 12.69% of the excised cases of basal cell carcinoma were sited on the nose.² Repairing full-thickness defects of the nasal ala, after tumor removal, requires achieving both functional and aesthetic results, which can be accomplished with various reconstructive methods ranging from skin grafts to locoregional flaps.³ Locoregional flaps are generally preferred for their better aesthetic outcomes. Chondrus grafts extracted from the anterior root of the helix, the helical rim, or the concha are viable options for three-layer alar reconstructions. Among the aspects of alar reconstruction, the replacement of the nasal lining stands out as both the most crucial and challenging. The nasal lining should ideally be thin and exhibit a smooth surface to maintain the unobstructed flow of air through the nasal passage. Optimal outcomes are achieved by using tissues of comparable thickness for replacement.⁴ According to the algorithm proposed by Moolenburgh et al., surgical approaches involving forehead or nasolabial flaps are recommended for full-thickness alar defects larger than 1.5 cm in size.⁵ This algorithm provides a valuable framework for decision-making in cases involving larger defects, in which failure to provide sufficient mucosal support can result in cicatricial contraction and/or the failure of external flaps or grafts when mucosal reconstruction is lacking.¹

A variety of reconstructive options for nasal lining are available, though most are specific to each defect's size and location. These include turnover paramedian forehead flaps, Spear flap and their variants, nasal mucosal flaps, nasolabial transposition flap and nasolabial turnover flap.¹

Case Report

We present two cases in which a full thickness removal was needed for a large basal cell carcinoma and for lentigo maligna melanoma. For the full-thickness nasal ala defect reconstruction we decided to use a nasolabial turnover flap, approached in two distinct methods: the first patient without a cartilage graft and the second one with it.

Case #1

A 91-year-old man presented with a 2.1 cm nodular basal cell carcinoma on the right nasal ala (Figure 1). We performed a single-

stage reconstruction using a nasolabial folded flap without cartilage graft. Following the administration of local anesthesia, a full thickness excision of the tumor was carried out, maintaining a 5-mm clear margin. This excision led to the removal of the entire aesthetic subunit. The measurement of the nasolabial flap on the same side as the surgical area was determined by the dimensions of the resulting defect. Subsequent to making the incision, the flap was raised while being connected to a slender superior pedicle, thus ensuring sufficient blood circulation and defatted. The flap was folded twice: in the superior part the skin was rotated to reconstruct the mucous layer of the ala, so that the flap's fat resulted visible in the external part of the new ala. We suture was with resorbable threads; then the distal part of the flap was folded again to reconstruct the skin layer, fat to fat layer, and sutured in an appropriate position using non-resorbable threads. The nearby medial cheek was gently lifted and moved forward to directly seal the donor site.

A week after the surgical procedure, the flap exhibited robust viability and proper blood supply. No instances were documented of nasal complications such as collapse of the nasal wall, airflow obstruction, hypertrophic scarring affecting the nares, or any signs of infection. Suture removal took place two weeks post-surgery. Histological examination confirmed the thorough removal of a nodular basal cell carcinoma with surgical margins of 4.8 mm clearance. During the three-month follow-up, airway patency remained optimal, and the aesthetic results were deemed satisfactory.

Case #2

A 65-year-old woman presented with an atypical pigmented lesion located on the right nasal wing. A diagnostic skin biopsy was conducted, revealing lentigo maligna melanoma in situ. Subsequently, a two-step excision and reconstruction procedure

was scheduled. In the first procedure, following the administration of a local anesthetic, a complete surgical excision of a 1.5x2 cm lesion situated on the right nasal wing was carried out. The excision included a 5 mm border of unaffected skin. The histological report confirmed melanoma in situ on an intradermal melanocytic nevus with involved posterolateral margin. Two weeks later, a procedure involving 5 mm radicalization and reconstruction was performed. This entailed the utilization of a turnover flap, coupled with a cartilage graft sourced from the corresponding auricular concha.

During the second surgery time, radicalization of the lesion and enlargement of the surgical breach were performed in the posterolateral area of the right nasal wing. The cartilage graft was obtained through a book-like incision on the skin of the right auricle. This incision allowed for the removal of a segment of cartilage measuring 3x0.4 cm. Subsequently, the skin was sutured using a non-absorbable thread. The defect was reconstructed by dissecting the nasolabial flap, defatting, reversing and suturing it with absorbable thread to recreate the mucous layer. The cartilage graft was placed for preserving the shape of the nostril valve, and the flap was then reversed again and sutured with non-absorbable thread to recreate the skin layer.

There were no complications, and the flap was well vascularized and vital during the one-week check. The stitches were removed after two weeks. During the one-month follow-up, it was found that the airway remained unobstructed and the aesthetic results were satisfactory.

Discussion

Nasolabial turnover flap stands as a viable alternative for the reconstruction of full-thickness defects located on the nasal wings: it is composed by layers of epidermis, dermis, and subcutaneous

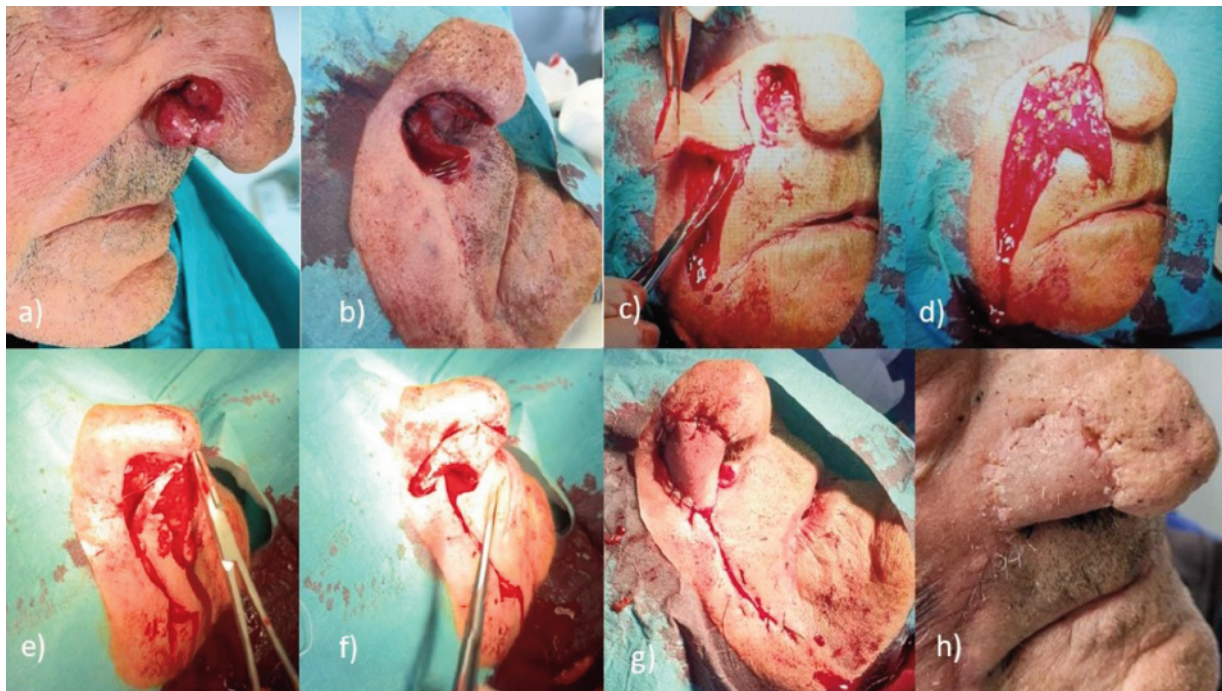


Figure 1. a) Case #1: particular of the right nasal wing basal cell carcinoma. b) Case #1: Surgical breach after full thickness excision. c) Case #1: design and incision of the flap till the subcutaneous layer. d) Case #1: first movement of the flap, folded in order to reconstruct the mucous layer. e) Case #2: variation with cartilaneous graft inserted in the flap- see the arrow. f) Case #2: second folding of the distal portion of the flap to reconstruct external skin layer. g) Case #1: final result at the end of surgery. h) Case #1: one-month follow-up.

fat, benefiting from a robust blood supply originating from the angular artery.⁵ This vascular support minimizes the risk of flap necrosis even after several adjustments. Furthermore, the flap's inherent stiffness contributes to preventing nostril collapse. Notably, this approach avoids leaving noticeable scars in the upper nasal region, except for the scar along the nasolabial fold.

When addressing full-thickness alar defects through reconstruction, it becomes crucial to effectively restore the internal lining. A turnover flap does not necessarily demand cartilage graft support because the multiple folding provides enhanced support for the nasal valve. Nevertheless, it's imperative to carefully evaluate the potential risk of nostril collapse to preempt this possibility, the application of an additional cartilage graft sourced from the ear, complete with its surrounding perichondrium, can be employed to avert alar collapse.⁵

Based on our experience, both reconstruction methods, with or without cartilage, prove to be good options. Incorporating cartilage ensures heightened structural support, although it does come with the drawback of increased flap thickness and necessitates an additional surgical incision for procurement. Several factors that might impact the decision include: the patient's age, with a preference for cartilage grafts in younger patients with longer life expectancies; the thickness of the skin, leaning towards the cartilage-free flap for individuals with notably thick and phymatous skin; and the patient's overall health status and compliance.

Conclusions

In conclusion, our observations indicate that the single-stage nasolabial turnover flap, with or without cartilage graft, presents a secure, dependable, and economically efficient reconstructive option for full-thickness nasal ala defect. It enables the restoration of the nose's three-dimensional integrity via a straightforward procedure that presents no functional or aesthetic complications.

References

1. Lane JE, Bob Hsia LL, Merritt BG. Reconstruction of Large Transmural Nasal Defects With a Nasolabial Turnover Interpolation Flap. *Dermatol Surg.* 2020;46:899-903.
2. Gualdi G, Monari P, Crotti S, et al. Matter of margins. *J Eur Acad Dermatol Venereol.* 2015;29:255-261.
3. Monari P, Damiani C, Ariasi C, et al. Dermatochirurgie - Tricks of the Trade / Dermatosurgery - Tricks of the Trade: Nasolabial folded flap for reconstruction of full-thickness alar defect of the nose. *J Dtsch Dermatol Ges.* 2023;21:1246-48
4. Unlü RE, Orbay H, Yılmaz AD, et al. A new approach to alar rim defects: mucocartilaginous turnover flap. *J Craniofac Surg.* 2007;18:661-4.
5. Kim HS, Kim WS, Kim HK, et al. Reconstruction of a full-thickness lateral alar defect using a superiorly based folded nasolabial flap without a cartilage graft: a single-stage operation. *J Craniofac Surg.* 2021;32:e162-e165.