

Original Research

Peri-Implant Mucositis Treatment with a Chlorhexidine Gel with A.D.S. 0.5%, PVP-VA and Sodium DNA vs a Placebo Gel: A Randomized Controlled Pilot Clinical Trial

Felice Lorusso¹, Gianluca Tartaglia², Francesco Inchingolo³, Antonio Scarano^{1,4,*}¹Department of Innovative Technologies in Medicine and Dentistry, University of Chieti-Pescara, 66100 Chieti, Italy²Department of Biomedical, Surgical and Dental Sciences, School of Dentistry, University of Milan, 20122 Milan, Italy³Department of Interdisciplinary Medicine, University of Medicine Aldo Moro, 70124 Bari, Italy⁴Department of Oral Implantology, Dental Research Division, Colledge Ingà, UNINGÁ, 29312 Cachoeiro de Itapemirim, Espírito Santo, Brazil*Correspondence: ascarano@unich.it (Antonio Scarano)

Academic Editor: Luca Testarelli

Submitted: 1 June 2022 Revised: 30 June 2022 Accepted: 6 July 2022 Published: 31 October 2022

Abstract

Background: Peri-implant mucositis is a bacterial and inflammatory disease of implant surrounding soft tissues. Chlorhexidine (CHX) associated with PVP-VA (Polyvinylpyrrolidone/vinyl acetate) has an adjuvant function in the antibacterial activity: it protects the film-forming layer, due to polymer, from microbial contamination or over-infection, and prolongs its permanence, without a direct action on the tissues and wounds. Sodium DNA is able to improve gingival trophism. The aim of the study was to compare a gel with CHX and antidiscoloration system (A.D.S.) 0.5% with the addition of PVP-VA and sodium DNA with a placebo gel without chlorhexidine in peri-implant mucositis treatment. **Methods:** Trial design: A single center randomized controlled pilot clinical trial was conducted on a total of 24 patients with mucositis, randomly allocated into two groups. In the group (A) (n = 12) patients were treated with a gel with CHX + A.D.S. 0.5% while a placebo gel was used in the group (B) (n = 12). Outcome: Plaque Index (PI) (primary outcome), Bleeding on probing (BOP) and Gingival Index (GI) (secondary outcomes) were assessed at baseline and at 2 weeks after treatment period. **Results:** Mean PI score recorded at baseline was 2.4 ± 0.4 [95% CI: -2.682/7.482] in the group (A) and 2.2 ± 0.5 [95% CI: -4.153/8.553] in the group (B) ($p > 0.05$) while mean PI score at 2 weeks was 0.5 ± 0.4 [95% CI: -4.582/5.582] and 1.7 ± 1.9 [95% CI: -9.736/13.14] in the group and in the group respectively ($p < 0.05$). Mean BOP value at baseline was $57.1 \pm 15.2\%$ [95% CI: -136.0/250.2] in the group (A) and $55.3\% \pm 11.7\%$ [95% CI: -93.36/204.0] ($p > 0.05$) while mean BOP value at 2 weeks follow-up was $14.3\% \pm 6.6\%$ [95% CI: -69.56/98.16] (A) and $45.4\% \pm 9.8\%$ [95% CI: -79.12/169.9] (B) respectively ($p < 0.05$). **Conclusions:** A significant reduction in gingival inflammation indexes was found at 2 weeks in patients with peri-implant mucositis treated with a gel with CHX + A.D.S. 0.5% with the addition of PVP-VA and sodium DNA compared to those treated with a placebo gel. **Clinical Trial Registration:** 2019-004976-20.

Keywords: peri-implant disease; mucositis; bacterial biofilms; plaque; oral hygiene; dental implants

1. Introduction

The peri-implant mucositis is a dental implant-associated inflammatory state of the soft tissues characterized by the presence of bleeding on probing, in the absence of bone resorption. There may be other signs of inflammation such as swelling, redness, suppuration. Histologically, the peri-implant tissues have been studied mainly in many different animal models, and subsequently confirmed in human studies. The peri-implant mucosa in physiological conditions has a height of 3–4 mm and is made up of connective tissue relatively poor in fibroblasts (3%) covered in part by keratinized epithelium mucosa and in part by non-keratinized epithelium lining mucosa [1]. The main differences with the periodontal tissues are the absence of the cementum and periodontal ligament, and therefore the absence of fibers [2,3]. The peri-implant tissues are also less vascularized in the area between the bone crest and the junctional epithelium than the corresponding connective tissue surrounding the natural tooth [4,5]. The implant

sites also have a longer epithelium [6].

An increased probing depth is not decisive in formulating the diagnosis of peri-implant mucositis, as it can be determined both by edema and by the reduced resistance to probing of the inflamed tissues. Oral peri-implant mucositis is defined as a reversible multifactorial inflammation of the peri-implant soft tissues with up to 64% prevalence among individuals with implants [7,8]. This condition affects only the soft marginal peri-implant tissues, not including alveolar bone loss. However it could be an early stage of a subsequent peri-implantitis, which has an incidence between 5–10% [9].

The diagnostic definition of peri-implant mucositis is based on following criteria: (1) presence of peri-implant signs of inflammation (redness, swelling, line or drop of bleeding within 30 seconds following probing), (2) no additional bone loss following initial healing [10].

In literature, the treatment of peri-implant mucositis normally includes mechanical calculus removal by the sur-



face of the implant by cures, ultrasonic tips, air-abrasives or laser devices [11]. In this way the adjunctive administration of local antibiotics or antiseptics seems to provide a increase of the treatments response, in order to prevent biofilms and calculus adhesion around the implant surfaces [12].

The chlorhexidine (CHX) is now known for its optimal antimicrobial and antiplaque properties and its use is considered the Gold Standard for antibacterial action in the oral hygiene [13]. The CHX inhibits the formation of new bacterial plaque and disrupts the already stratified one by acting on its matrix thanks to the competition with Calcium ions [13]. The most common side effect is represented by brownish pigmentations that occur on dental surfaces, restorations, dental prostheses and tongue. This effect, undermining the compliance of the patient, often limits its use [14]. The A.D.S., allows to combine antiplaque with aesthetic action, reducing the the formation of pigmentation on tooth enamel without reducing the CHX effectiveness [15]. The film-forming property of PVP-VA allows the formation of a protective film that shields the underlying tissues from bacterial or chemical attacks. These polymers are able to protect dental surfaces or oral mucosal membranes for several hours with a slow degradation with the release of active ingredients embedded [16]. The layer of PVP-VA blocks the initial aggregation of the plaque, slowing down the creation of the bacterial biofilm and, consequently, the aggression on the tissues and their inflammation [16]. A recent study analyzed the ability of the film-forming layer of PVP-VA contained in a mouthwash compared to a placebo. The results show the effectiveness of PVP-VA in inhibiting bacterial plaque alone compared to placebo, in absence of other antiseptic active substances in the mouthwash [17]. Chlorhexidine, in presence of PVP or PVP-VA, fails to act on oral tissues because its action is shielded by the presence of the film-forming layer of polymers that limit the antiseptic action. For this reason clinical studies that have investigated this association reporting a less effective action of CHX alone [18]. However, it should be noted that the high inhibition to plaque formation offered by the mechanical obstacle of the film-forming layer of PVP and PVP-VA copolymer is to be considered the antiseptic effect offered by the association chlorhexidine-PVP (or PVP-VA) [18–20]. In fact, if the plaque fails to adhere to the tissues and mature, it cannot exert its own inflammatory action, because it is unable to aggregate in the biofilm and to generate an inflammatory state. The role of chlorhexidine in a PVP-VA association has an adjuvant function: it protects the film-forming layer from contamination or bacterial overinfection, and prolongs its permanence, not acting directly on tissues and wounds, as limited by the mechanical film layer barrier [21]. Therefore, the presence of PVP-VA in a mouthwash or in a periodontal gel is able, alone, to ensure antibacterial protection [22]. Sodium DNA is a natural molecule widely used in cosmetics as an anti-aging product

[22]. The using of DNA-sodium has been proved to decrease *in vitro* the oxidative stress action on the oral tissues and the inflammatory response in a wide spectrum of coltures [23,24]. This effect has been demonstrated *in vivo* in a in periodontitis control in association with CHX/PVP-PA mouthwash formulation compared to the placebo [25]. The most frequent side effect of the CHX formulation in form of mouthwash and gels is characterized by brownish pigmentations on dental surfaces, restorations, dental prostheses and tongue [15]. In addition, others side effects are taste alteration, higher tartar formation especially in case of prolonged administration over 14 days [26–29]. This effects are able to decrease consistently the patient compliance and often could limits its administration [14]. The Anti Discoloration System (ADS) is able to combine the antiplaque activity with aesthetic effect, reducing the tooth pigmentation with no reducing of the CHX action [18].

The aim of this study was therefore to evaluate the effect of a gel with CHX and A.D.S. 0.5% with the addition of PVP-VA and sodium DNA and to compare it with a placebo gel in patients with peri-implant mucositis, that is presence of bleeding on probing in the absence of bone loss and pathological pockets (<3 mm).

2. Materials and Methods

The protocol for this study was designed in accordance with the Helsinki Declaration, with the Good Clinical Practice Guidelines for clinical trials on medicinal products (GCP E6 R2:2017) and UNI EN ISO 14155:2017 and approved by the Ethical Committee for Biomedical Research of Chieti and Pescara (Prot. N. 1776/5.12.2019). The adult patients have been recruited at the Department of Innovative Technologies in Medicine and Dentistry of the University “G.D’Annunzio” of Chieti-Pescara and signed the informed consent.

2.1 Study Design

The study was designed as a randomized single-center controlled, triple-blind trial with two parallel groups (Fig. 1, Ref. [30]).

Twenty-four adult patients were enrolled in this trial, they were equally and randomly divided into two groups: group A (n = 12) treated using a gel with CHX + A.D.S. 0.5% with the addition of PVP-VA and sodium DNA and group B (n = 12) administered a placebo, an aqueous inert free of chlorhexidine gel. All patients fulfilled these inclusion criteria: (1) good general health in absence of relevant systemic diseases such as diabetes, immune diseases, haematological diseases; cancer; severe infectious diseases such as HIV or viral hepatitis with signs and/or symptoms of liver failure; cognitive difficulties; intellectual difficulties; motorial deficits, (2) adult age (over 18 years), (3) presence of one implant with mucositis, defined as bleeding on probing with no evidence of peri-implant bone loss, (4) no implant mobility, (5) presence of at least 2 mm of

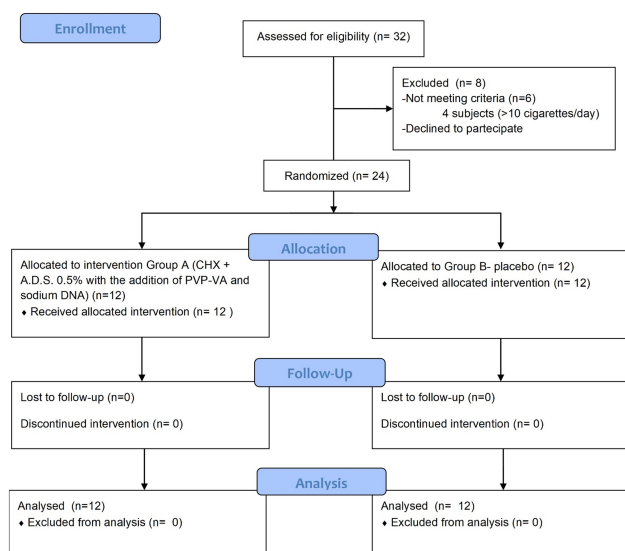


Fig. 1. CONSORT Flowchart of the study design [30].

peri-implant keratinized gingiva, (6) implant with a single crown or bridge pillars with a maximum of 3 elements, (7) no overload or occlusal trauma signs.

Exclusion criteria were as follows: pregnant subjects, strong smokers (more than 10 cigarettes/day); fully edentulous patients with exclusively implant rehabilitations; allergy to chlorhexidine gluconate or to other components of the gel formulation and of the placebo.

All patients agreed to adhere to the trial and signed an informed consent.

2.2 Randomization, Allocation Concealment and Blinding

Simple randomization was conducted at the Department of Innovative Technologies in Medicine and Dentistry of the University “G.D’Annunzio” of Chieti-Pescara, using computer-generated random numbers with an allocation ratio of 1:1. Allocation sequence was concealed using sequentially numbered, opaque, sealed envelopes, which were opened only after the professional hygiene. Blinding of participants, data collectors and data analysts were applied. Operators and patients were not informed about the gel content: the blinded gel had a similar packaging, with no signs or references that could indicate the formulation of the gel.

2.3 Clinical Assessment

The enrolled patients with peri-implantitis mucositis, were properly visited and they were subjected to professional oral hygiene session targeted to these sites. Implant sites with mucositis have been cleaned with the aid of titanium or carbon currettes; supragingival calculus removal employing ultrasonic scaler tips and accurate polishing with prophylaxis pastes were also performed in the first session (T0). Baseline parameters of PI, BOP and GI index were properly recorded before the previously described first oral

hygiene treatment. Therefore accurate oral hygiene instructions were given, taking care that patients maintained a high level of hygiene throughout the clinical protocol period. No rinses, drugs or medications were prescribed to patients with the only exception of those deemed essential for the health of the patient. Each group was treated with the same protocol of oral hygiene but with a different assigned gel. After the recording of the clinical variables and the oral hygiene session, each patient received an anonymous gel tube, a syringe and an applicator nozzle. During the study the patients were required to use the daily mechanical oral hygiene except for the evaluated implant site. The patient was carefully instructed on the application methods of the assigned gel in the implant site: an application of the gel twice a day, for 14 days was prescribed. In order to reduce inter-operator variability a single dental provider has carried out the oral hygiene, as well as the evaluation and recording of clinical variables. Follow-up evaluations were performed after 14 days (T1). Neither the researchers, therapists nor the patients were aware of the group allocation.

2.4 Gel Composition

The tested formulations (Curasept Spa, Saronno, VA, Italy) was composed by a solution of 0.5% Chlorhexidine Anti Discoloration System (ADS), PVP-VA and Sodium DNA. The ADS system is composed of ascorbic acid and sodium metabisulfate, while the adding of 0.12% polyvinylpyrrolidone/vinyl acetate proven their efficacy to avoid the chlorhexidine capability to bind the surface of the tooth and the soft tissue membranes and their pigmentation maintaining the anti-plaque efficacy. The 0.2% of Sodium DNA Sodium DNA (Na-DNA) is a biologically active, functional compound obtained by deoxyribonucleic acid of the gonadic tissue of male sturgeons. These molecules submitted a purification, de-polymerization process and finally neutralization sodium (Na+) ions. The PVP-VA copolymer associated with with sodium DNA improve the gingival tissues trophism and improve their effect on bacterial plaque control. The placebo mouthwash was composed by an aqueous alcohol solution (Betafarma, Cesano Boscone, Milan, Italy).

2.5 Study Outcomes

The plaque index (PI) was recorded at all timepoints to evaluate the presence or absence of dental plaque along the mucosal margin was recorded. The recording has been performed by two blinded calibrated operators and the mean value was considered for further statistical evaluations. Moreover, the bleeding on probing (BOP) was recorded to assess the presence/absence of bleeding after probing of the gingiva. Moderate force (<25 g) was used during the probing. Gingival tissue health using Gingival Index (Loe & Silness 1963) has been recorded as follows: 0 = Normal gingiva; 1 = Mild inflammation and slight edema and color change in absence of bleeding on probing; 2 = Moderate in-

Table 1. Basic characteristic of the population sample.

General characteristics	
Total sample size	n = 24 subjects 12 subjects (Group A); 12 subjects (Group B)
Average age of subjects	64.2 ± 8.3 years
Age range	41–74 years
Gender	Male/Female ratio 0.92/1 (Group A); 0.95/1 (Group B)
Total of rated implant with mucosistis	N = 62 implants 32 implants (Group A); 26 implants (Group B)
Incisal/canine region implants	82.26% (51 implants)
Molar/premolar region implants	17.74% (11 implants)
Mean pocket depth (DS)	Group A: 2.2 ± 0.6 mm [median: 1.6 mm]; Group B 2.4 ± 0.5 [median: 1.7 mm]

flammation, reddened tissues, edematosis and bleeding on probing; 3 = Severe inflammation marked redness, edema, ulceration and tendency to bleeding.

2.6 Statistical Analysis

The descriptive analysis of the data was carried out: the quantitative variables are presented with mean and standard deviation. The statistical evaluations were carried out by means of two sample *t* test to compare for each group of patients analyzed, the values detected at time T0 and the values measured at time T1. The level of statistical significance was set at 5% ($p < 0.05$). The normal distribution was evaluated by the Kilmogorov Smirnoff test (p -value > 0.05).

3. Results

3.1 General Characteristics of the Population

Twenty-four patients, with a mean age of 64.2 ± 8.3 years, were enrolled and randomly allocated into two group for this study (Table 1). By randomization the patients were included in GROUP A or GROUP B. The sample consisted of 13 women (54.2%) and 11 men (45.8%) (Table 1). No drop-outs were recorded at the T0 and T1 trial stages (14 days). Therefore, patients were required to use 10 mL of gel twice a day for 2 weeks. In T1 phase, after 14 days, a new recording of the clinical values was performed. No adverse effects were recorded during the study period. In addition, no side effects have been recorded following the administration of the product Test and Placebo.

3.2 Study Outcomes

The results for the gingival index at baseline and at T1 are summarized in Table 2.

At T0 time, the baseline related to the Plaque Index detected was 2.4 ± 0.4 for Group A and 2.2 ± 0.5 for Group B ($p > 0.05$). After 14 days (T1) mean Plaque Index recorded was 0.5 ± 0.4 for Group A and 1.7 ± 0.9 for Group B ($p < 0.05$) (Fig. 2). At baseline (T0), mean BOP value was $57.1\% \pm 15.2\%$ for Group A and $55.3\% \pm 11.7\%$ for Group B ($p > 0.05$). At 2 weeks (T1) the BOP score was $14.3\% \pm 6.6\%$ for Group A and $45.4\% \pm 9.8\%$ for Group B ($p <$

0.05) (Fig. 3, Table 2).

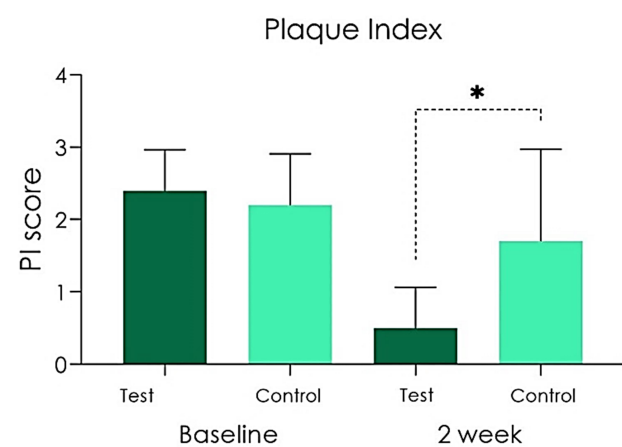


Fig. 2. Plaque Index scored at baseline and after 2 weeks [$*p < 0.05$].

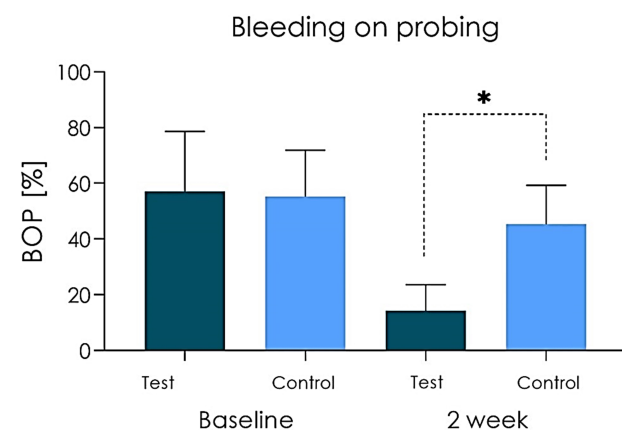


Fig. 3. BOP (%) scored at baseline and 2 weeks from baseline.

Table 2. Plaque index and BOP assessment of the Test and Control Group at the baseline and after 2 weeks.

Plaque index (mean, SD)	Group A	Group B	<i>p</i> value
	Test	Control	
Baseline	2.4 ± 0.4 [95% CI: -2.682/7.482]	2.2 ± 0.5 [95% CI: -4.153/8.553]	<i>p</i> > 0.05
2 weeks	0.5 ± 0.4 [95% CI: -4,582/5,582]	1.7 ± 0.9 [95% CI: -9,736/13,14]	<i>p</i> < 0.05
BOP score (mean, SD)	Group A	Group B	<i>p</i> value
	Test	Control	
Baseline	57.1% ± 15.2% [95% CI: -136,0/250,2]	55.3% ± 11.7% [95% CI: -93,36/204,0]	<i>p</i> > 0.05
2 weeks	14.3% ± 6.6% [95% CI: -69,56/98,16]	45.4% ± 9.8% [95% CI: -79,12/169,9]	<i>p</i> < 0.05

4. Discussion

The chlorhexidine (CHX) has been investigated for several years as an antimicrobial agent for the chemical control of plaque formation and it is unanimously recognized as one of the most effective cationic antiseptic compound currently used in oral hygiene [13,14]. The film-forming properties of PVP-VA (Polyvinylpyrrolidone/vinyl acetate) in protecting dental surfaces or oral mucosal membranes, even if not intact, are known [16]. Moreover, the sodium DNA in form of topical formulation is able to improve gingival trophism and human gingival epithelium repair [24]. In our work we have analyzed, as primary outcome, the antiplaque activity of a gel containing Chlorhexidine and A.D.S. 0.5% with the addition of PVP-VA and Sodium DNA compared to a placebo gel in the peri-implant mucositis treatment [22]. From a histological point of view, the inflammatory lesion characteristic of peri-implant mucositis is well defined and confined to the most coronal connective tissue, lateral to the junctional or pocket epithelium [2,10,31]. It contains an inflammatory infiltrate rich in vascular structures, plasma cells and lymphocytes, which does not extend apically in the supracrestal connective area [32,33]. Strong scientific evidence identifies plaque as the etiological factor of peri-implant mucositis [34]. However, there is interindividual variability in the immune response, and factors such as smoking, diabetes mellitus, and radiation therapy may be modifying factors [35,36].

Certainly, the oral environment is exposed to oxidative stress and free-radicals action occurred by the inflammation state [37,38]. The state of chronicity induces an unbalanced connection between these exogenous agents and the physiological response to the damage repair [39–41]. The hydrolyzed DNA is reported to a protective action against the oxidative stress in the oral cavity [23,24] with a very high strong versatility in its formulation. In fact, it could be found in combination with anti-microbial agents in form of topical gels and mouthwash solution [18,42]. *In vitro*, the hydrolyzed DNA a significant effect of the proliferation and activity of the fibroblast cells due to the activation of A2

purinergic receptors [43]. The repair activity seems to be induced following a synergic action to the growth factors cascade including epidermal growth factor (EGF) platelet-derived growth factor (PDGF) and fibroblast growth factor (FGF) [44].

Experimental studies have shown that peri-implant mucositis is reversible, and that it is therefore possible to restore health through plaque control procedures, while a resolution of clinical signs may take more than 3 weeks after treatment [31]. The present study evaluated the short-term effect after two weeks of treatment, in order to detect the effect of the therapies on marginal peri-implant inflammation. Gingival inflammation can be assessed by different methods including gingival indices increasing its specificity if associated to the bleeding on probing index. In this study, there was no statistically significant differences in the Plaque Index (primary outcome) between the Test and Placebo groups at baseline while a significant difference was found between the two groups after 14 days of treatment, with a decreased bacterial plaque in the Group A (test). As for secondary outcomes, less bleeding (Bleeding on Probing Score) emerged at 2 weeks of treatment in the Test group compared to Control group. According to Mish *et al.* [45], the clinical Bleeding on Probing index, represents a simple and accurate indicator of the health of peri-implant tissues. The Bleeding on probing (BOP) is a basic clinical exploratory sign: a positive bleeding on probing is indicative of gingival inflammation. The diagnostic utility of BOP is high, although its prognostic value is debated. Many authors concluded that the presence of BOP does not indicate an increased risk of tissue destruction and bone support, as this clinical sign has a low positive predictive value [2,3,21]. Conversely, the negative predictive value of the bleeding on probing is high. A prospective study on implants confirmed that, similar to the situation of natural teeth, the absence of bleeding on probing has high negative predictive values and therefore can be interpreted as a sign of stability of peri-implant soft tissues [46,47]. Within a periodontal treatment, it is essential to

ensure healthy gums, without inflammation and therefore in the absence of BOP [8,48,49]. In the present study, at T1 evaluation an absent/mild degree of inflammation (Gingival Index) was present in patients that used CHX gel while a mild/moderate degree of inflammation was found in the placebo group at the same time. According to the literature peri-implant mucositis is considered as a superficial clinical phase of peri-implantitis, that is characterized by a progressive involvement of deep tissues with bone resorption. The control of many factors such as bacterial plaque, tartar deposits and home and professional maintenance are fundamental aspects for the long-term functional survival of supported implant rehabilitations [3,50,51]. At experimental time T1 a statistically significant difference emerges between the test group and the placebo group with regard to the primary parameter Plaque Score. The beneficial effect induced by the CHX and ADS 0.5%, PVP-VA and sodium DNA gel on the peri-implant soft tissues are also evident in relation to the secondary outcomes of BOP and GI, which showed a statistically significant difference between patients in favour of the Test group compared to the placebo gel group.

5. Conclusions

According to our results, the use of a Chlorhexidine gel with Anti Discoloration System (ADS) 0.5%, PVP-VA and Sodium DNA, tested for two weeks in peri-implant mucositis treatment, appears to be effective in leading to a reduction in the clinical parameters of mucous inflammation and reduced deposits of bacterial plaque, without adverse effects and risks associated with treatment.

Author Contributions

Conceptualization—AS; Methodology—AS, FL; Investigation—AS, FL; Data curation—FL, Writing and reviewing of the manuscript—AS, FL; Supervision—GT, FI; Validation—AS, FL, GT, FI.

Ethics Approval and Consent to Participate

Ethical Committee for Biomedical Research of Chieti and Pescara (Prot. N. 1776/5.12.2019).

Acknowledgment

Not applicable.

Funding

This research received no external funding.

Conflict of Interest

The authors declare no conflict of interest. FL is serving as one of the Editorial Board members and Guest editors of this journal. We declare that FL had no involvement in the peer review of this article and has no access to information regarding its peer review. Full responsibility for the

editorial process for this article was delegated to LT.

References

- [1] Araujo MG, Lindhe J. Peri-implant health. *Journal of Periodontology*. 2018; 89: S249–S256.
- [2] Lee C, Huang Y, Zhu L, Weltman R. Prevalences of peri-implantitis and peri-implant mucositis: systematic review and meta-analysis. *Journal of Dentistry*. 2017; 62: 1–12.
- [3] Derks J, Tomasi C. Peri-implant health and disease. a systematic review of current epidemiology. *Journal of Clinical Periodontology*. 2015; 42: S158–S171.
- [4] Piattelli A, Scarano A, Piattelli M, Bertolai R, Panzoni E. Histologic Aspects of the Bone and Soft Tissues Surrounding Three Titanium Non-Submerged Plasma-Sprayed Implants Retrieved at Autopsy: a Case Report. *Journal of Periodontology*. 1997; 68: 694–700.
- [5] Degidi M, Artese L, Piattelli A, Scarano A, Shibli JA, Piccirilli M, *et al.* Histological and immunohistochemical evaluation of the peri-implant soft tissues around machined and acid-etched titanium healing abutments: a prospective randomised study. *Clinical Oral Investigations*. 2012; 16: 857–866.
- [6] Lang NP, Lindhe J. *Clinical periodontology and Implant Dentistry*. Wiley Blackwell, Chichester: UK. 2015.
- [7] Lindhe J, Meyle J. Peri-implant diseases: Consensus Report of the Sixth European Workshop on Periodontology. *Journal of Clinical Periodontology*. 2008; 35: 282–285.
- [8] Maglione M, Bevilacqua L, Dotto F, Costantinides F, Lorusso F, Scarano A. Observational Study on the Preparation of the Implant Site with Piezosurgery vs. Drill: Comparison between the Two Methods in terms of Postoperative Pain, Surgical Times, and Operational Advantages. *Biomed Research International*. 2019; 29: 8483658.
- [9] Mombelli A, Lang NP. The diagnosis and treatment of peri-implantitis. *Periodontology 2000*. 1998; 17: 63–76.
- [10] Renvert S, Roos-Jansåker A, Claffey N. Non-surgical treatment of peri-implant mucositis and peri-implantitis: a literature review. *Journal of Clinical Periodontology*. 2008; 35: 305–315.
- [11] Renvert S, Hirooka H, Polyzois I, Kelekis-Cholakias A, Wang H. Diagnosis and non-surgical treatment of peri-implant diseases and maintenance care of patients with dental implants – Consensus report of working group 3. *International Dental Journal*. 2019; 69: 12–17.
- [12] Ramanauskaite A, Fretwurst T, Schwarz F. Efficacy of alternative or adjunctive measures to conventional non-surgical and surgical treatment of peri-implant mucositis and peri-implantitis: a systematic review and meta-analysis. *International Journal of Implant Dentistry*. 2021; 7: 112.
- [13] Supranoto SC, Slot DE, Addy M, Van der Weijden GA. The effect of chlorhexidine dentifrice or gel versus chlorhexidine mouthwash on plaque, gingivitis, bleeding and tooth discoloration: a systematic review. *International Journal of Dental Hygiene*. 2015; 13: 83–92.
- [14] Slot D, Berchier C, Addy M, Van der Velden U, Van der Weijden G. The efficacy of chlorhexidine dentifrice or gel on plaque, clinical parameters of gingival inflammation and tooth discoloration: a systematic review. *International Journal of Dental Hygiene*. 2014; 12: 25–35.
- [15] Marrelli M, Amantea M, Tatullo M. A comparative, randomized, controlled study on clinical efficacy and dental staining reduction of a mouthwash containing Chlorhexidine 0.20% and Anti Discoloration System (ADS). *Annali di Stomatologia (Roma)*. 2015; 6: 35–42.
- [16] Maddi A, Scannapieco FA. Oral biofilms, oral and periodontal infections, and systemic disease. *The American Journal of Dentistry*. 2013; 26: 249–254.

- [17] Pinto G, Silva MD, Peddey M, Sillankorva S, Azeredo J. The role of bacteriophages in periodontal health and disease. *Future Microbiology*. 2016; 11: 1359–1369.
- [18] Varoni EM, Gargano M, Ludwig N, Lodi G, Sardella A, Carrassi A. Efficacy of an anti-discoloration system (ADS) in a 0.12% chlorhexidine mouthwash: A triple blind, randomized clinical trial. *The American Journal of Dentistry*. 2017; 30: 235–242.
- [19] Cortellini P, Labriola A, Zambelli R, Pini Prato G, Nieri M, Tonetti MS. Chlorhexidine with an anti discoloration system after periodontal flap surgery: a cross-over, randomized, triple-blind clinical trial. *Journal of Clinical Periodontology*. 2008; 35: 614–620.
- [20] Lorenz K, Bruhn G, Heumann C, Netuschil L, Brex M, Hoffmann T. Effect of two new chlorhexidine mouthrinses on the development of dental plaque, gingivitis, and discoloration. a randomized, investigator-blind, placebo-controlled, 3-week experimental gingivitis study. *Journal of Clinical Periodontology*. 2006; 33: 561–567.
- [21] Cosgarea R, Sculean A, Shibli JA, Salvi GE. Prevalence of peri-implant diseases - a critical review on the current evidence. *Brazilian Oral Research*. 2019; 33: e063.
- [22] Li W, Wang RE, Finger M, Lang NP. Evaluation of the antigingivitis effect of a chlorhexidine mouthwash with or without an antidiscoloration system compared to placebo during experimental gingivitis. *Journal of Investigative and Clinical Dentistry*. 2014; 5: 15–22.
- [23] Ionescu AC, Vezzoli E, Conte V, Sartori P, Procacci P, Brambilla E. Activity of Experimental Mouthwashes and Gels Containing DNA-RNA and Bioactive Molecules against the Oxidative Stress of Oral Soft Tissues: The Importance of Formulations. *A Bioreactor-Based Reconstituted Human Oral Epithelium Model*. *Molecules*. 2021; 26: 2976.
- [24] Ionescu AC, Vezzoli E, Conte V, Procacci P, Garcia-Godoy F, Brambilla E. Effects of Na-DNA mouthwash solutions on oral soft tissues. A bioreactor-based reconstituted human oral epithelium model. *The American Journal of Dentistry*. 2020; 33: 277–284.
- [25] Lorusso F, Tartaglia G, Inchingolo F, Scarano A. Early Response and Clinical Efficacy of a Mouthwash Containing Chlorhexidine, Anti Discoloration System, Polyvinylpyrrolidone/Vinyl Acetate and Sodium DNA in Periodontitis Model: A Triple-Blind Randomized Controlled Clinical Trial. *Dentistry Journal*. 2022; 10: 101.
- [26] Guerra F, Pasqualotto D, Rinaldo F, Mazur M, Corridore D, Nofroni I, *et al.* Therapeutic efficacy of chlorhexidine-based mouthwashes and its adverse events: Performance-related evaluation of mouthwashes added with Anti-Discoloration System and cetylpyridinium chloride. *International Journal of Dental Hygiene*. 2019; 17: 229–236.
- [27] Ballini A, Cantore S, Farronato D, Cirulli N, Inchingolo F, Papa F, *et al.* Periodontal disease and bone pathogenesis: The crosstalk between cytokines and porphyromonas gingivalis. *Journal of Biological Regulators and Homeostatic Agents*. 2015; 29: 273–281.
- [28] Inchingolo F, Martelli FS, Gargiulo Isacco C, Borsani E, Cantore S, Corcioli F, *et al.* Chronic Periodontitis and Immunity, Towards the Implementation of a Personalized Medicine: A Translational Research on Gene Single Nucleotide Polymorphisms (SNPs) Linked to Chronic Oral Dysbiosis in 96 Caucasian Patients. *Biomedicines*. 2020; 8: 115.
- [29] Rapone B, Corsalini M, Converti I, Loverro MT, Gnoni A, Trerotoli P, *et al.* Does Periodontal Inflammation Affect Type 1 Diabetes in Childhood and Adolescence? A Meta-Analysis. *Frontiers in Endocrinology*. 2020; 11: 278.
- [30] Cuschieri S. The CONSORT statement. *Saudi Journal of Anaesthesia*. 2019; 13: 27.
- [31] Pontoriero R, Tonelli MP, Carnevale G, Mombelli A, Nyman SR, Lang NP. Experimentally induced peri-implant mucositis. a clinical study in humans: Experimental peri-implant mucositis. *Clinical Oral Implants Research*. 1994; 5: 254–259.
- [32] Carinci F, Lauritano D, Bignozzi CA, Pazzi D, Candotto V, Santos de Oliveira P, *et al.* A New Strategy Against Peri-Implantitis: Antibacterial Internal Coating. *International Journal of Molecular Sciences*. 2019; 20: 3897.
- [33] Scarano A, Cholakis A, Piattelli A. Histologic Evaluation of Sinus Grafting Materials after Peri-implantitis-Induced Failure: a Case Series. *The International Journal of Oral & Maxillofacial Implants*. 2017; 32: e36–e75.
- [34] Dreyer H, Grischke J, Tiede C, Eberhard J, Schweitzer A, Toikkanen SE, *et al.* Epidemiology and risk factors of peri-implantitis: a systematic review. *Journal of Periodontal Research*. 2018; 53: 657–681.
- [35] Zandim-Barcelos DL, Carvalho GG, Sapata VM, Villar CC, Hämmerle C, Romito GA. Implant-based factor as possible risk for peri-implantitis. *Brazilian Oral Research*. 2019; 33: e067.
- [36] Canullo L, Schlee M, Wagner W, Covani U. International Brainstorming Meeting on Etiologic and Risk Factors of Peri-implantitis, Montegrotto (Padua, Italy), August 2014. *The International Journal of Oral & Maxillofacial Implants*. 2015; 30: 1093–1104.
- [37] Żukowski P, Maciejczyk M, Waszkiel D. Sources of free radicals and oxidative stress in the oral cavity. *Archives of Oral Biology*. 2018; 92: 8–17.
- [38] Wang X, Shen K, Wang J, Liu K, Wu G, Li Y, *et al.* Hypoxic preconditioning combined with curcumin promotes cell survival and mitochondrial quality of bone marrow mesenchymal stem cells, and accelerates cutaneous wound healing via PGC-1 α /SIRT3/HIF-1 α signaling. *Free Radical Biology and Medicine*. 2020; 159: 164–176.
- [39] Lindskog S, Blomlof L, Hammarstrom L. Repair of periodontal tissues in vivo and in vitro. *Journal of Clinical Periodontology*. 1983; 10: 188–205.
- [40] Scarano A, Nounbissi S, Gupta S, Inchingolo F, Stilla P, Lorusso F. Scanning electron microscopy analysis and energy dispersion X-ray microanalysis to evaluate the effects of decontamination chemicals and heat sterilization on implant surgical drills: zirconia vs. steel. *Applied Sciences*. 2019; 9: 2837.
- [41] Inchingolo AD, Inchingolo AM, Bordea IR, Malcangi G, Xhajanka E, Scarano A, *et al.* SARS-CoV-2 Disease Adjuvant Therapies and Supplements Breakthrough for the Infection Prevention. *Microorganisms*. 2021; 9: 525.
- [42] Van Strydonck DAC, Slot DE, Van der Velden U, Van der Weijden F. Effect of a chlorhexidine mouthrinse on plaque, gingival inflammation and staining in gingivitis patients: a systematic review. *Journal of Clinical Periodontology*. 2012; 39: 1042–1055.
- [43] Thellung S, Florio T, Maragliano A, Cattarini G, Schettini G. Polydeoxyribonucleotides enhance the proliferation of human skin fibroblasts: Involvement of $\alpha 2$ purinergic receptor subtypes. *Life Sciences*. 1999; 64: 1661–1674.
- [44] Bülzingslöwen IV, Brennan MT, Spijkervet FKL, Logan R, Stringer A, Raber-Durlacher JE, *et al.* Growth factors and cytokines in the prevention and treatment of oral and gastrointestinal mucositis. *Supportive Care in Cancer*. 2006; 14: 519–527.
- [45] Misch CE, Strong IT, Bidez MW. *Implant Design*. In *Contemporary implant dentistry 200*. Publisher: Elsevier. 2007.
- [46] Jepsen S, Rühling A, Jepsen K, Ohlenbusch B, Albers H-K. Progressive peri-implantitis. Incidence and prediction of peri-implant attachment loss. *Clinical Oral Implants Research*. 1996; 7: 133–142.
- [47] Luterbacher S, Mayfield L, Brägger U, Lang NP. Diagnostic characteristics of clinical and microbiological tests for monitoring periodontal and peri-implant mucosal tissue conditions

- during supportive periodontal therapy (SPT): Diagnosis of periodontal and peri-implant sites. *Clinical Oral Implants Research*. 2000; 11: 521–529.
- [48] Marrone A, Lasserre J, Bercy P, Brex MC. Prevalence and risk factors for peri-implant disease in Belgian adults. *Clinical Oral Implants Research*. 2013; 24: 934–940.
- [49] Costa FO, Takenaka-Martinez S, Cota LOM, Ferreira SD, Silva GLM, Costa JE. Peri-implant disease in subjects with and without preventive maintenance: a 5-year follow-up. *Journal of Clinical Periodontology*. 2012; 39: 173–181.
- [50] Mir-Mari J, Mir-Orfila P, Figueiredo R, Valmaseda-Castellón E, Gay-Escoda C. Prevalence of peri-implant diseases. a cross-sectional study based on a private practice environment. *Journal of Clinical Periodontology*. 2012; 39: 490–494.
- [51] Hashim D, Cionca N, Combescure C, Mombelli A. The diagnosis of peri-implantitis: A systematic review on the predictive value of bleeding on probing. *Clinical Oral Implants Research*. 2018; 29: 276–293.