



Cupid's arrow retained in the heart

Umberto Benedetto¹, Massimo Caputo¹, Angeliki Kosti¹, Mariangela Peruzzi², Sebastiano Sciarretta^{2,3}, Giuseppe Biondi-Zoccai^{2,3}, Giacomo Frati^{2,3}

¹Bristol Heart Institute, University of Bristol, School of Clinical Sciences, Bristol Royal Infirmary, Bristol BS2 8HW, UK; ²Department of Medico-Surgical Sciences and Biotechnologies, Sapienza University of Rome, Corso della Repubblica 79, 04100, Latina (LT), Italy; ³Department of Angiocardioneurology, IRCCS Neuromed, Via Atinense 18, 86077, Pozzilli (IS), Italy

Correspondence to: Dr. Mariangela Peruzzi. Department of Medico-Surgical Sciences and Biotechnologies, Sapienza University of Rome, Corso della Repubblica 79, 04100 Latina (LT), Italy. Email: mariangela.peruzzi@uniroma1.it.

Submitted Feb 07, 2018. Accepted for publication Jul 10, 2018.

doi: 10.21037/jtd.2018.12.12

View this article at: <http://dx.doi.org/10.21037/jtd.2018.12.12>

Introduction

Non-iatrogenic, traumatic foreign bodies penetration and retention in the heart are rare, with available reports mainly focusing on bullets, shrapnel, and circular saw fragments. Indeed, self-inflicted intracardiac foreign bodies are very rarely seen in clinical practice. The sequelae largely depend on the projectile nature, path of travel, and unquestionably on the final position in the thorax.

In this case, while arrow injury to the heart is a common cause of penetrating trauma in rural areas of underdeveloped nations, it certainly represents an unusual occurrence in Western countries.

Accordingly, the rarity of such events precludes standardized diagnostic and therapeutic protocols and any approach must be tailored in accordance with clinical conditions and surgical risks (1-4).

Case presentation

We hereby present a rare case of an accidental 16" crossbow dart penetrating injury of the heart in a 48-year-old-gentleman treated at the Bristol Heart Institute. The patient was at home when he accidentally shot himself with a crossbow which penetrated his chest. Despite the injury, he did not lose consciousness and was able to call for emergency assistance. He was brought to the emergency department where at inspection the pulsating metallic tail of a dart was evident near the left parasternal region (*Figure 1A*), without any evident exit wound. Because the patient was clinically

and hemodynamically stable, he underwent a contrast-enhanced computed tomography (CT), which provided us striking anatomic details concerning the features of the tip and the trajectory of the arrow in view of its extraction (*Figure 1B,C,D,E*). After a fast consultation of our heart team, emergency operation was promptly performed. Before chest opening, cardiopulmonary bypass was established using peripheral cannulation (right femoral vessels) in order to drain the heart thus preventing exsanguination in case of arrow displacement during sternotomy and during its removal. A full median sternotomy was performed uneventfully and the pericardium was opened. Surprisingly no blood was found into the pericardium. The entry and exit point of the dart were identified on the anterior face of the right ventricle and diaphragmatic wall of the left ventricle respectively. On beating heart, the arrow was gently pulled-back and both, the entry and the exit orifices were closed by means of pledged 4/0 prolene U-sutures (*Figure 1F*). The patient was weaned from cardiopulmonary bypass (total bypass time 10 minutes) without bleeding and the lacerations were finally reinforced with glue. Intraoperative transesophageal echocardiography (TEE) ruled out any injury of intra-cardiac structures such ventricular or atrial septum defect or alterations in valves morphology and function. Therefore, it was not necessary to open heart chambers and chest was closed. Postoperative course was uneventful and was discharged on post-operative day 12. Pre-discharge transthoracic echocardiogram, chest X-ray and blood tests were within limits.

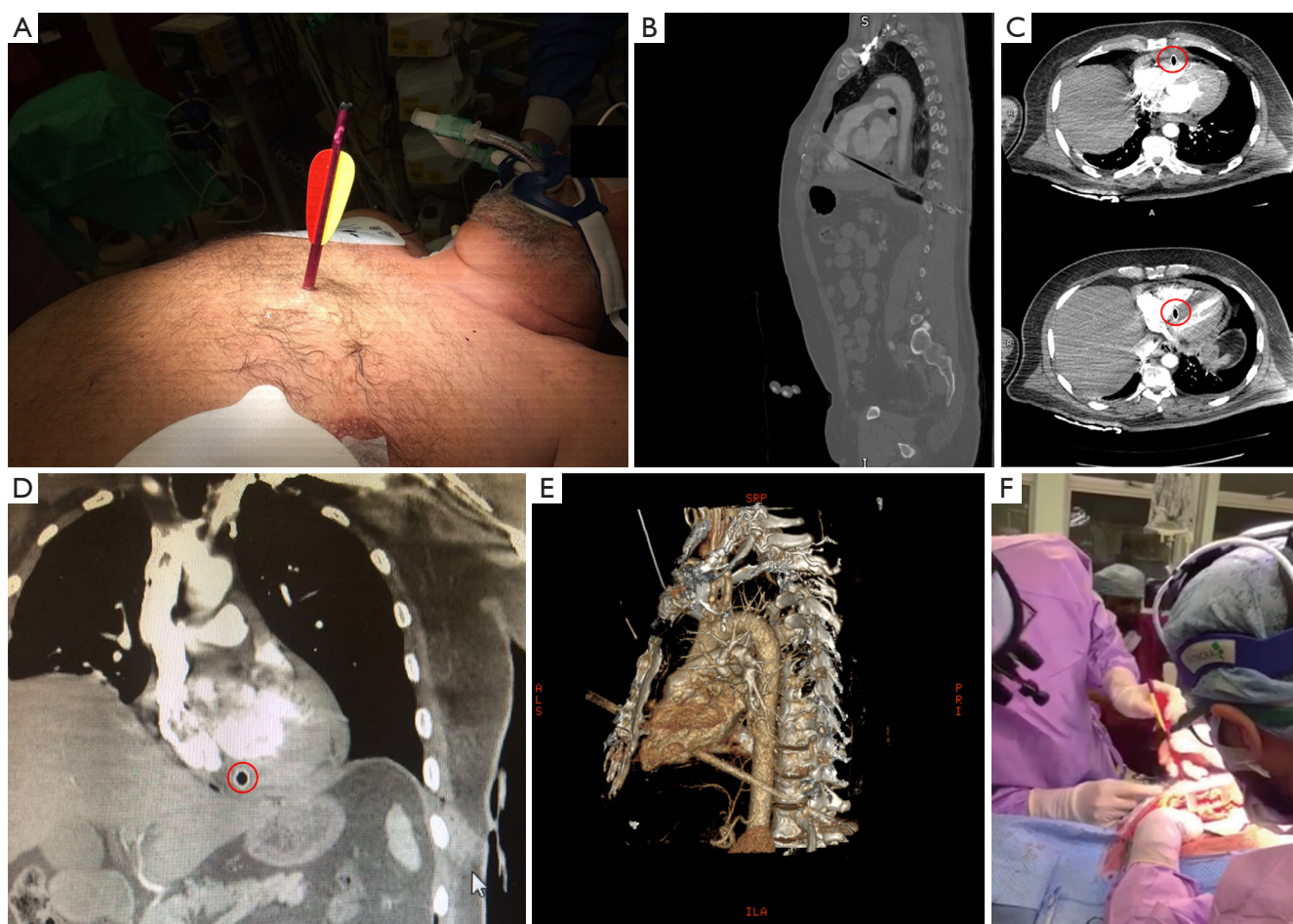


Figure 1 Patient's presentation at the emergency department, instrumental examination and arrow retrieval during surgery. (A) Patient's presentation; (B,C,D) different computed tomography scan planes (red circles pointing out the arrow); (E) 3D volume rendering reconstruction; (F) arrow retrieval.

Discussion

Penetrating cardiac trauma is almost universally fatal, with more than 50% of patients dying in the very short term and another 30% dying on arrival to the hospital. Localization of intra-thoracic missiles can be supported by multiple imaging modalities including TEE and CT scan but the promptness of the decision-making process is mandatory to achieve more chance of succeeding. In our case, operative decision making regarding diagnostic imaging modalities and the way of retrieval of the dart has been based on multiple factors including patient stability along with arrow features and location acquired by CT scan. The correct management of cardiac missiles should be thus individualized according to their overall dimensions,

location and nature.

Small missiles completely embedded in the myocardium or in the pericardium and pericardial space are generally well tolerated and they may be left in place without further complications (5,6). This was not even our case due to the overall dimension of the dart and its anatomical location. Surgical options are evidently subjected to the nature, dimension and localization of the foreign body. Some authors suggest a median sternotomy approach especially when a pericardiectomy is needed such in our case. It has been also found that a median sternotomy results in decreased morbidity and reduced hospitalization compared with thoracotomy (7). More specifically, arrows penetrating the chest cavity and the heart should be left *in situ* and not be removed until arrival in a hospital with necessary

expertise to determine underlying injury.

In this exceptional case the patient had the double fate that even with a 16" dart running through the thorax, the head had the same diameter as the arrow shaft allowing an easy extraction and second, the projectile did not hit and seriously damage any of the mediastinal organs. Paradoxically, the right ventricle resulted as the safest cardiac chamber due to its muscular wall and lower intracavitary pressure, as injury of any other cardiac chamber would have likely been much deadlier.

This exceptional case requiring emergency cardiac surgery, in which all specialists faced a uniquely life-threatening situation and worked as a veritable team, supports the heart team concept, with an onsite and readily available application.

Acknowledgements

None.

Footnote

Conflicts of Interest: Prof. Biondi-Zoccai has consulted for Abbott and Bayer. The other authors have no conflicts of interest to declare.

Cite this article as: Benedetto U, Caputo M, Kosti A, Peruzzi M, Sciarretta S, Biondi-Zoccai G, Frati G. Cupid's arrow retained in the heart. *J Thorac Dis* 2019;11(1):E1-E3. doi: 10.21037/jtd.2018.12.12

Informed Consent: Written informed consent was obtained from the patient for publication of this manuscript and any related images.

References

1. Peloponissios N, Halkic N, Moeschler O, et al. Penetrating thoracic trauma in arrow injuries. *Ann Thorac Surg* 2001;71:1019-21.
2. Fingleton LJ. Arrow wounds to the heart and mediastinum. *Br J Surg* 1987;74:126-8.
3. VanGurp G, Hutchison T, Alto W. Arrow wound management in Papua New Guinea. *J Trauma* 1990;30:183-8.
4. Nwiloh J, Edaigbini S, Danbauchi S, et al. Arrow injury to the heart. *Ann Thorac Surg* 2010;90:287-9.
5. Symbas PN, Picone AL, Hatcher CR, et al. Cardiac missiles. A review of the literature and personal experience. *Ann Surg* 1990;211:639-47.
6. Muzzi L, Bizzarri F, Barretta A, et al. A piece of chainlink fence in the heart. *Tex Heart Inst J* 2007;34:498-500.
7. Kumar R, Rana SS, Kumar S, et al. Management of Accidental and Iatrogenic Foreign Body Injuries to Heart-Case Series. *J Clin Diagn Res* 2017;11:PE01-4.