

## Review

Filomena Giulia Sileo, Sara Alameddine, Daniela Anna Iaccarino, Daniele Di Mascio, Giulia Andrea Giuliani, Emma Bertucci, Asma Khalil and Francesco D'Antonio\*

# Outcome of fetal congenital pulmonary malformations: a systematic review and meta-analysis

<https://doi.org/10.1515/jpm-2024-0017>

Received January 14, 2024; accepted April 12, 2024;

published online April 24, 2024

## Abstract

**Objectives:** To report the outcome of fetuses with a prenatal diagnosis of congenital lung malformation (CLM) diagnosed on ultrasound by performing a comprehensive assessment of these outcomes through a systematic review and meta-analysis.

**Content:** CLMs are a heterogeneous group of anomalies that involve the lung parenchyma and its bronchovascular structures. Their presentation and evolution are variable, from entirely asymptomatic lesions with sonographic regression *in utero* to hydropic fetuses requiring fetal therapy, intrauterine death or neonatal morbidity. A systematic

review was conducted in Medline, Embase and Cochrane databases including studies on fetuses with CLM diagnosed prenatally in order to report the *in-utero* natural history of these lesions. Thirty-nine studies (2,638 fetuses) were included in the final review.

**Summary:** Regression/reduction in size of the lung lesion during pregnancy was reported in 31 % of cases, while its increase in 8.5 % of cases. Intra-uterine death complicated 1.5 % of pregnancies with fetal CLM, while neonatal and perinatal death were 2.2 and 3 %, respectively. Neonatal morbidity occurred in 20.6 % of newborns with CLM; 46 % had surgery, mainly elective. In fetuses with CLM and hydrops, fetal/perinatal loss occurred in 42 %. Assessment of the role of fetal therapy in improving the outcomes of pregnancies complicated by CLM was hampered by the small number of included cases and heterogeneity of type of interventions.

**Outlook:** Fetuses with CLM prenatally diagnosed have a generally favorable outcome. Conversely, there is a low quality of evidence on the actual role of fetal therapy in improving the outcome of fetuses presenting with these anomalies.

**Keywords:** lung; fetus; ultrasound; pulmonary; systematic review

\*Corresponding author: Prof. Francesco D'Antonio, MD, PhD, Centre for Fetal Care and High-risk Pregnancy, Department of Obstetrics and Gynaecology, University of Chieti, Chieti, Italy. E-mail: francesco.dantonio@unich.it

**Filomena Giulia Sileo**, Prenatal Medicine Unit, Obstetrics and Gynaecology Unit, Department of Medical and Surgical Sciences for Mother, Child and Adult, University of Modena and Reggio Emilia, Modena, Italy; and Department of Biomedical, Metabolic and Neural Sciences, International Doctorate School in Clinical and Experimental Medicine, University of Modena and Reggio Emilia, Modena, Italy. <https://orcid.org/0000-0001-7380-0576>

**Sara Alameddine and Daniela Anna Iaccarino**, Department of Obstetrics and Gynaecology, University of Chieti, Chieti, Italy

**Daniele Di Mascio**, Department of Maternal and Child Health and Urological Sciences, Sapienza University of Rome, Rome, Italy. <https://orcid.org/0000-0002-6560-3393>

**Giulia Andrea Giuliani**, Prenatal Medicine Unit, Obstetrics and Gynaecology Unit, Department of Medical and Surgical Sciences for Mother, Child and Adult, University of Modena and Reggio Emilia, Modena, Italy; and Department of Obstetrics and Gynaecology, University of Chieti, Chieti, Italy

**Emma Bertucci**, Prenatal Medicine Unit, Obstetrics and Gynaecology Unit, Department of Medical and Surgical Sciences for Mother, Child and Adult, University of Modena and Reggio Emilia, Modena, Italy

**Asma Khalil**, Fetal Medicine Unit, Saint George's Hospital, London, UK; and Fetal Medicine Unit, Liverpool Women's Hospital, Liverpool, UK

## Introduction

Congenital lung malformations (CLM) are a heterogeneous group of anomalies that involve the lung parenchyma and its bronchovascular structures and accounting for 5–18 % of all congenital anomalies. Their incidence is now reported to be 1 in 2,500 due to the increased detection during routine ultrasound scanning and it is probably still underestimated due to the frequency of undetected and/or asymptomatic lesions incidentally found later in life [1, 2]. The most common lesion is the congenital pulmonary airway malformation (CPAM), previously called congenital cystic adenomatoid malformation (CCAM), which is a hamartomatous proliferation of cystic spaces lined by respiratory

epithelium, communicating with the bronchial tree and with vascular supply from the pulmonary artery [2–4]. The second most common lesion is the bronchopulmonary sequestration (BPS), a non-functioning lung lesion not communicating with the tracheobronchial tree and receiving an anomalous artery supply from the systemic circulation [3, 5, 6]. However, CPAM and BPS frequently overlap histopathologically in the so-called “hybrid lesions” [7]. The CLM are usually classified into macrocystic, microcystic/hyperechogenic or mixed lesion according to their ultrasonographic appearance since the histopathological classification is not possible *in utero*.

Presentation and evolution of CLMs are variable, from entirely asymptomatic lesions with sonographic regression *in utero* to hydropic fetuses requiring fetal therapy, or suffering from intrauterine death or neonatal morbidity. In order to predict the likely outcome of these pregnancies, several sonographic predictors have been suggested, with the CPAM-volume ratio (CVR) being the most commonly used in order to predict fetal hydrops in CLMs [8].

After birth, around 10 % of newborns with prenatally diagnosed CLMs will develop respiratory distress symptoms early in life while around 90 % of them will be entirely asymptomatic during their life [9]. In the latter, therefore, the optimal management is less defined. The role and timing of surgery in asymptomatic CLMs remains controversial [10]: the rationale for surgery is based on the desire to avoid recurrent pneumonias or abscesses which are usually refractory to antibiotics. However, the true pneumonia risk has not been well defined [11]. Similarly, malignant degeneration of CLMs has been described although the overall risk is likely to be extremely low [12]. This is why, a non-operative management has been proposed, especially for small CLMs prenatally diagnosed whose natural history is believed to be more benign and therefore not justifying the potential major postoperative morbidity of the surgical management [13].

Despite the importance and their relatively high frequency, a systematic review and meta-analysis on the natural history *in utero* and postnatal outcomes of these lesions is still lacking. In this context, we performed a systematic review and meta-analysis of the published literature to report the outcome of fetuses with CPAM diagnosed on prenatal ultrasound.

## Methods

### Protocol, eligibility criteria, information sources and search strategy

This review was performed according to a *a priori* designed protocol recommended for systematic reviews and meta-analysis. Medline,

Embase and Cochrane databases were searched electronically in 2018 and updated in December 2022, utilizing combinations of the relevant medical subject heading (MeSH) terms, key words, and word variants for “congenital pulmonary airways obstruction” and “outcome” (Supplementary Table 1). The search and selection criteria were restricted to English language.

Reference lists of relevant articles and reviews were hand searched for additional reports. PRISMA and MOOSE guidelines were followed. The study was registered with the PROSPERO database (Registration number: CRD42018107238).

### Study selection, data extraction and data items

The primary outcome to report was *in-utero* natural history of prenatally diagnosed CLM by describing the reduction (reduction or disappearance) or the increase in size of the lesions.

The secondary outcomes were:

- Intrauterine death (IUD), defined as fetal loss after 20 weeks’ gestation;
- Neonatal death (NND), defined as death occurring up to 28 days after birth;
- Perinatal death (PND), defined as IUD or NND;
- Overall neonatal morbidity (including respiratory distress syndrome (RDS), Neonatal Intensive Care Unit (NICU) admission, respiratory morbidity).
- Need for surgery.
- Type of surgery: elective or emergency (i.e. in the neonatal period and/or for respiratory symptoms).

Furthermore, we planned to perform sub-group analysis according to the sonographic appearance of the lesion (microcystic, macrocystic, mixed and hyperechoic) and in those presenting with hydrops at ultrasound. Finally, we planned to report the role of fetal therapy (any, cyst drainage or thora-coamniotic shunt placement) in improving the outcome of these anomalies.

Only studies including fetuses with a prenatal diagnosis of isolated CLM confirmed at birth were considered eligible for the inclusion in the present systematic review. Studies reporting prenatal information on paediatric or pathologic series were excluded if no information on the natural history and perinatal mortality of these fetuses could be extrapolated.

Case reports, conference abstracts and case series with fewer or equal to three cases were excluded to avoid sampling bias. Studies published before 2010 were also excluded as we believe that the recent important advances in prenatal diagnosis (better resolution of ultrasound machines, improvement in knowledges of these pathologies, etc.) have increased the diagnosis also of small lesions while, on the other hand, it is likely that only more severe forms were prenatally diagnosed in the past. Therefore, by including only papers from 2010 onward, this review will best reflect the natural history and the current management of these lesions.

Three authors (FGS, SA and DAI) reviewed all abstracts independently. Agreement regarding potential relevance was reached by consensus. Full text copies of those papers were obtained, and the same reviewers independently extracted relevant data regarding study characteristics and pregnancy outcomes. Inconsistencies were discussed by the reviewers and consensus reached or by discussion with a senior author (FDA). If more than one study was published on the same cohort with identical endpoints, the report containing the most

comprehensive information on the population was included to avoid overlapping populations.

### Assessment of risk of bias

Quality assessment of the included studies was performed using the Newcastle-Ottawa Scale (NOS) for cohort and/or case-control studies [14]. According to NOS, each study is judged on three broad perspectives: the selection of the study groups, the comparability of the groups, and the ascertainment outcome of interest. Assessment of the selection of a study includes the evaluation of the representativeness of the exposed cohort, selection of the non-exposed cohort, ascertainment of exposure and the demonstration that outcome of interest was not present at the start of study. Assessment of the comparability of the study includes the evaluation of the comparability of cohorts based on the design or analysis. Finally, the ascertainment of the outcome of interest includes the evaluation of the type of the assessment of the outcome of interest, length and adequacy of follow-up. According to NOS a study can be awarded a maximum of one star for each numbered item within the Selection and Outcome categories. A maximum of two stars can be given for Comparability [14].

### Data synthesis

We used meta-analyses of proportions to combine data and reported pooled proportions and their 95 % confidence intervals (CI). Between-study heterogeneity was explored using the  $I^2$  statistic, which represents the percentage of between-study variation that is due to heterogeneity rather than chance. A value of 0 % indicates that no heterogeneity was observed, whereas values >50 % are associated with substantial heterogeneity. Due to the clinical heterogeneity among studies, a random effects model was used for all meta-analyses [15]. Egger's test was used to assess potential publication bias and funnel plots were created for visual inspection [16]. Tests for funnel plot asymmetry were not used when the total number of publications included for each outcome was less than 10, as the tests lack power to detect real asymmetry in this scenario [17]. The analysis was performed using Statsdirect 3.0.171 (Stats Direct Ltd) and Revman 5.3 (The Nordic Cochrane Centre, The Cochrane Collaboration, 2014) statistical software.

## Results

### Study selection and study characteristics

A total of 1787 studies were identified, 173 were assessed with respect to their eligibility for inclusion and 39 studies were included in this systematic review (Table 1 and Figure 1) [18–56].

These 39 studies included 2,638 fetuses with an antenatal diagnosis of CPAM (Table 1). No randomized controlled trial was available for inclusion; data for this review were derived only from observational cohort studies or case series. Thirty-nine studies were retrospective [19–38, 40–49, 51–56] and only three [18, 39, 50] were prospective in nature.

Diagnosis occurred mainly in the second trimester at the time of the anomaly scan and reported at its earliest at 19.5 weeks' gestation [19].

The sonographic appearance of the lesions (i.e. microcystic, macrocystic, mixed or hyperechoic) was reported by 19 studies [18, 21, 22, 24, 25, 29–32, 37, 38, 42–44, 47, 50, 53, 55]. Type of lesions (i.e. CPAM or CCAM or Bronchopulmonary sequestration or hybrid lesions) was reported by 34 studies [18–25, 27–32, 34–40, 43–54, 56]. Among the included studies, 15 studies [19, 23, 26, 30, 33, 37, 38, 43, 45, 46, 48, 49, 52, 55, 56] reported also data on fetal therapy: four studies performed a cyst drainage [37, 38, 49, 52], 10 studies positioned a thoraco-amniotic shunt [19, 23, 30, 33, 37, 38, 45, 46, 55, 58], seven studies performed other types of fetal therapy including amniodrainage, laser therapy of the feeding artery, maternal steroids or EXIT procedure [19, 26, 37, 38, 43, 45, 56]. Finally, 17 studies reported data on hydropic fetuses separately from the whole cohort [19, 25, 26, 30, 31, 34, 35, 38, 43, 45–47, 49, 51, 52, 54].

### Risk of bias of included studies

The results of the quality assessment of the included studies using the NOS scale are presented in Table 2. Most of the included studies showed average scores regarding the selection and comparability of study groups, and for ascertainment of the outcome of interest. The main weaknesses of these studies were their retrospective non-randomized design, small sample size, heterogeneity of outcomes observed and lack of stratification of the observed outcomes according to the ultrasound appearance of the lesions for most of the included studies.

### Synthesis of results

Regression or reduction in size of the lung lesion during pregnancy was reported in 30.90 % (95 % CI 20.09–42.88) of cases, while its increase in 8.47 % (95 % CI 2.93–16.46). Intra-uterine death complicated 1.53 % (95%CI 0.89–2.34) of pregnancies, while the corresponding figures for neonatal and perinatal death were 2.21 % (95 % CI 1.21–3.50) and 2.97 % (95 % 1.77–4.46). 20.57 % (95 % CI 15.66–25.97) of newborns with CLM experienced postnatal morbidity and 18.50 % (95 % CI 8.60–31.10) had radiological signs of mediastinal shift at birth. 46.29 % (95 % CI 33.96–58.86) of newborns with a prenatal diagnosis of CLM had surgery; elective surgical intervention was performed in 67.13 % (95 % CI 54.05–78.99), while 32.87 % (95 % CI 21.01–45.95) required emergency surgery for the presence of respiratory symptoms (Table 3).

**Table 1:** General characteristics of the studies included in the systematic review.

First author	Year	Country	Study design	Period considered	Gestational age at diagnosis	Type of lesion	Fetuses, n
Delacourt [18]	2022	France	Prospective	2015–2018	NS	CPAM	436
Karlsson [19]	2022	Sweden	Retrospective	2002–2020	19.5 (17–35)	CPAM, PBS	66
Rolo [20]	2022	Brasil	Retrospective	2013–2017	22–32	CCAM	21
An [21]	2022	China	Retrospective	2004–2016	22.5 (CVR<1.0), 23.3 (CVR 1–1.6)	CPAM	42
Chen [22]	2021	China	Retrospective	2014–2017	24.7 ± 2.8	CPAM	227
Wong [23]	2021	France	Retrospective	2009–2018	23 + 6 ± 2.7	CPAM, BPS, BC, CLE	75
Gilad [24]	2020	Israel	Retrospective	2008–2018	22 (17.3–26.2)	CPAM, BPS	20
Jeong [25]	2020	Korea	Retrospective	2010–2016	23.2 (17.4–32.3)	CPAM	118
King [26]	2020	USA	Retrospective	2015–2018	NS	CLM	44
Anderson <sup>a</sup> [27]	2019	USA	Retrospective	2009–2017	NS	CPAM, BPS	61
Beksac [28]	2019	Turkey	Retrospective	2004–2018	From 22 to 34.4 weeks	CPAM	35
Cho [29]	2019	Korea	Retrospective	2009–2019	23.5 ± 2.2	BPS+Hybrid	47
Molinaro [30]	2019	Italy	Retrospective	2003–2016	22 (21–28 weeks)	CCAM	33
Tuzovic [31]	2019	USA	Retrospective	2005–2015	Median 22 weeks	CCAM, PBS	53
Chon [32]	2018	USA	Retrospective	2006–2017	21.9	CPAM	8
Girsen <sup>a</sup> [33]	2017	USA	Retrospective	2009–2014	NS	CPAM	47
Kane [34]	2017	Australia	Retrospective	2005–2015	Mean 22 weeks and 6 days (range 17 weeks 5 days–36 weeks and 1 day)	CCAM, BPS, mixed lesions	65
Lin [35]	2017	China	Retrospective	2008–2015	Median 24 weeks, 24 (18–32)	BPS	71
Makhijani [36]	2017	Australia	Retrospective	2007–2014	NS	CPAM	35
Walker [37]	2017	UK	Retrospective	1990–2015	Median 21 weeks	CCAM, PS	228
Hellmund [38]	2016	Germany	Retrospective	2002–2013	22 weeks (range 17–29)	CPAM	67
Lau [39]	2016	China	Prospective	2009–2014	22.4 ± 0.52 weeks	CPAM	63
Xia [40]	2016	China	Retrospective	2012–2014	24.3 weeks (17–36)	CCAM	115
Feghali [41]	2015	USA	Retrospective	2005–2013	20.2 weeks (±1.4 weeks)	CPAM	42
Kunisaki [42]	2015	USA	Retrospective	2002–2014	Between a mean of 21.3 ± 1.0 and 24.3 ± 0.5	CPAM	100
Stoiber [43]	2015	Switzerland	Retrospective	2000–2013	NS (different GA for CPAM and BPS)	CPAM, BPS	37
Bondioni [44]	2014	Italy	Retrospective	2004–2012	NS	CPAM	27
Mallmann [45]	2014	Germany	Retrospective	2002–2011	Median 23.3 (20.4–27.0)	BPS	41
Ng [46]	2014	UK	Retrospective	2001–2011	NS	CCAM, PS	74
Ruchonnet-Metralier [47]	2014	France	Retrospective	2008–2013	Median 22 weeks	CPAM	89
Zhang [48]	2014	China	Retrospective	2010–2013	Mean 24 weeks (range 18–30 weeks).	PS	68
Alamo [49]	2013	Switzerland	Retrospective	2006–2012	20–33	CPAMs, BPS, bronchogenic cyst	22
Beydon [50]	2013	France	Prospective	2007–2011	NS	CPAM, BPS, hybrid lesions and cysts	23
Ho [51]	2013	Hong Kong	Retrospective	2008–2010	From 18 to 35 weeks	CPAM, BPS, mixed lesions	19
Lima [52]	2013	Brasil	Retrospective	1990–2010	Mean 24 ± 3.7 weeks	CCAM	25
Muller [53]	2012	France	Retrospective	2007–2009	Median 23	CCAM	12
Yong [54]	2012	Canada	Retrospective	1996–2004	21 weeks (range 15–39)	CCAM	69
Hadchouel [55]	2011	France	Retrospective	2004–2008	23.4 ± 0.5 (21–4 to 36.0)	CPAM	36
Raychaudhuri [56]	2011	Australia	Retrospective	2004–2010	Mean 20.8 weeks (range 17–29 weeks)	CCAM	24

<sup>a</sup>Shared cases, Girsen included only for fetal therapy outcomes. BC, bronchogenic cysts; BPS, bronchopulmonary sequestration; CCAM, congenital cystic adenomatoid malformation; CLE, congenital lung emphysema; CCLL, congenital cystic lung lesions; CPAM, congenital pulmonary airway malformation; NS, not specified; PS, pulmonary sequestration.

The occurrence of the explored outcomes when not considering studies including cases of fetal hydrops is reported in Table 3. Unfortunately, a comprehensive assessment of the

observed outcomes according to the ultrasound appearance of the lesion was not possible due to the very small number of studies reporting these sub-group analyses.

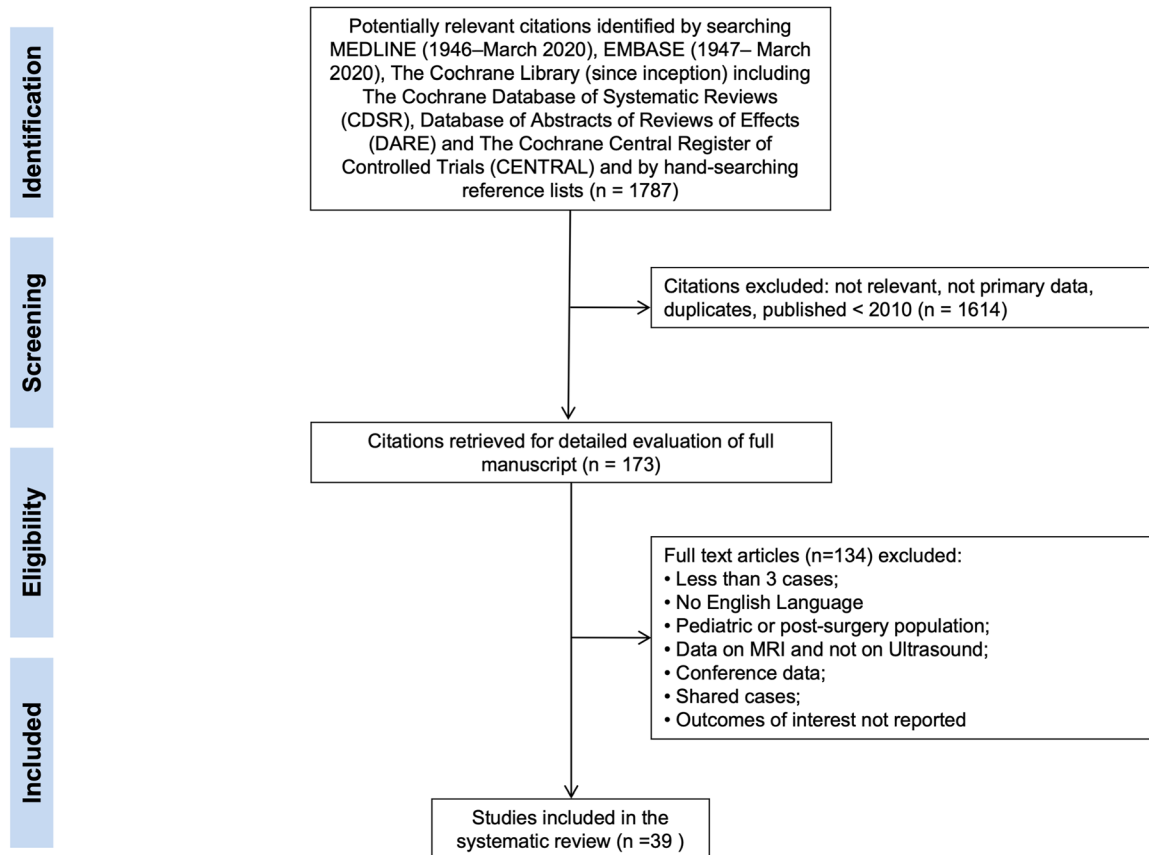


Figure 1: Systematic review flowchart.

## Sub-group analyses: fetuses with hydrops and fetal therapy

Fetal or perinatal loss occurred in 42.38 % (95 % CI 26.84–58.74) of fetuses with hydrops, while reduction of the size during pregnancy was reported in 4.42 % (95 % CI 1.26–9.39) as presented in Table 4. Assessment of the role of fetal therapy in improving the outcomes of pregnancies complicated by CLM was hampered by the small number of included cases and even smaller number of events which precluded a comprehensive assessment of the role of fetal therapy in these anomalies. Furthermore, different interventions for fetal CLM were reported in the published literature, including insertion of thoraco-amniotic shunt, drainage of the lesion in case of cystic malformation and laser coagulation of the feeding vessel of the lesion. For the purpose of the analysis and in view of the small number of cases included, we reported the analysis for fetuses undergoing drainage of the lesion or insertion of thoraco-amniotic shunt. When considering all fetuses undergoing intervention (Table 5), regression or reduction in size of the lesion was reported in 61.73 % (95 % CI 13.99–97.86), perinatal death

in 21.51 % (95 % CI 11.88–33.07) and preterm birth in 29.42 % (95 % CI 14.57–46.95), while 70.37 % (95 % CI 55.18–83.55) of newborns underwent surgery. Finally, when considering only fetuses presenting with hydrops at ultrasound, regression or reduction in size of the lesion was reported in 84.02 % (95 % CI 47.60–99.98) of cases and 78.76 % (95 % CI 43.62–98.82) had resolution of the hydrops after fetal therapy. Perinatal death occurred in 21.91 % (95 % CI 9.37–37.88) of pregnancies complicated by CLM presenting with hydrops and PTB in 52.73 % (95 % CI 25.54–79.06).

## Discussion

### Main findings

The findings from this study showed that fetuses with CLM diagnosed on prenatal ultrasound have a generally good outcome. Regression or reduction in size of the lesion occurred in 31 % of cases, while its increase in size in about 8.5 %. The risk of fetal or neonatal mortality was also low. Conversely, in fetuses presenting with hydrops the risk of



**Table 2:** Quality assessment of the included studies according to the Newcastle-Ottawa Scale (NOS) for cohort studies; a study can be awarded a maximum of one star for each numbered item within the Selection and Outcome categories. A maximum of two stars can be given for Comparability.

First author	Year	Selection	Comparability	Outcome
Delacourt [18]	2022	★★★	★	★★
Karlsson [19]	2022	★★	★	★
Rolo [20]	2022	★★		★
An [21]	2021	★	★	★
Chen [22]	2021	★★★	★	★★
Wong [23]	2021	★★	★	★
Gilad [24]	2020	★		★
Jeong [25]	2020	★★★	★	★
King [26]	2020	★	★	★
Anderson [27]	2019	★★		★
Beksac [28]	2019	★	★	★
Cho [29]	2019	★★		★
Molinaro [30]	2019	★		★
Tuzovic [31]	2019	★★	★	★
Chon [32]	2018	★★		★
Girsén [33]	2017	★★	★	★
Kane [34]	2017	★★★	★	★★
Lin [35]	2017	★★	★	★★
Makhijani [36]	2017	★★	★	★★
Walker [37]	2017	★★	★	★
Hellmund [38]	2016	★★	★	★★
Lau [39]	2016	★★★	★	★
Xia [40]	2016	★★	★	★★
Feghali [41]	2015	★★★	★	★
Kunisaki [42]	2015	★★	★	★★
Stoiber [43]	2015	★★		★
Bondioni [44]	2014	★★	★	★★
Mallmann [45]	2014	★★	★	★★
Ng [46]	2014	★★		★★★
Ruchonnet-Metrailler [47]	2014	★★		★
Zhang [48]	2014	★★		★★
Alamo [49]	2013	★★★		★★★
Beydon [50]	2013	★★★		★★
Ho [51]	2013	★★		★★
Lima [52]	2013	★★★	★	★
Muller [53]	2012	★		★
Yong [54]	2012	★★		★★★
Hadchouel [55]	2011	★★		★
Raychaudhuri [56]	2011	★★		★★★

perinatal loss was high while the regression or resolution of the lesion was less frequent. Assessment of the role of fetal therapy in improving the outcomes of pregnancies complicated by CLM was impaired by the small number of included cases and heterogeneity of interventions explored which precluded a comprehensive assessment of the role of fetal therapy in these anomalies.

**Table 3:** Pooled proportions for the different outcomes explored in the present systematic review in fetuses with CLM (95 % confidence intervals, CI, between parentheses).

Outcome	Studies (n)	Fetuses, n/N	I <sup>2</sup> , %	Pooled proportion (95 % CI)
<b>All studies</b>				
Regression of the lesion during pregnancy	20	450/1,219	94.7	30.90 (20.09–42.88)
Increase in size of the lesion during pregnancy	10	25/334	79.9	8.47 (2.93–16.46)
Intra-uterine death	27	27/2012	33.4	1.53 (0.89–2.34)
Neonatal death	27	35/2012	61.4	2.21 (1.21–3.50)
Perinatal death	27	53/2012	62.4	2.97 (1.77–4.46)
Overall neonatal morbidity	29	362/2007	87	20.57 (15.66–25.97)
Mediastinal shift after birth	7	66/351	86.9	18.50 (8.60–31.10)
Newborns undergoing surgery	32	380/1977	96.9	46.29 (33.96–58.86)
Elective surgery	17	342/485	87.6	67.13 (54.05–78.99)
Emergency surgery	17	143/485	87.6	32.87 (21.01–45.95)
<b>Excluding studies with fetal hydrops</b>				
Regression of the lesion during pregnancy	12	249/683	95.8	30.37 (31.68–38.81)
Increase in size of the lesion during pregnancy	6	10/234	60.9	5.38 (1.59–11.23)
Intra-uterine death	9	5/385	55.4	1.36 (0.15–3.73)
Neonatal death	9	6/385	30.4	1.85 (0.56–3.86)
Perinatal death	9	11/385	75.6	3.51 (0.69–8.36)
Overall neonatal morbidity	15	149/729	85	22.63 (15.13–31.14)
Mediastinal shift after birth	4	23/208	82.5	10.19 (2.43–22.44)
Newborns undergoing surgery <sup>a</sup>	16	419/762	97	53.06 (32.72–72.94)
Elective surgery <sup>a</sup>	8	198/267	88.2	72.78 (54.22–87.87)
Emergency surgery <sup>a</sup>	8	69/267	88.2	27.22 (12.13–45.67)

<sup>a</sup>These outcomes were not reported consistently by the same studies.

## Strengths and limitations

This is, to the best of our knowledge, the first systematic review and meta-analysis on congenital lung malformations and their natural *in-utero* history. The main strengths of this

**Table 4:** Pooled proportions for the different outcomes explored in the present systematic review in hydropic fetuses with CLM (95 % confidence intervals, CI, between parentheses).

Outcome	Studies, n	Fetuses, n/N	I <sup>2</sup> , %	Pooled proportion (95 % CI)
Fetal or perinatal loss	17	42/96	60.5	42.38 (26.84–58.74)
Reduction in size during pregnancy	16	289	0	4.42 (1.26–9.39)

**Table 5:** Pooled proportions for the different outcomes explored in the present systematic review in fetuses with CLM undergoing *in utero* therapy (thoraco-amniotic shunt or drainage) (95 % confidence intervals, CI, between parentheses).

Outcome	Studies, n	Fetuses, n/N	I <sup>2</sup> , %	Pooled proportion (95 % CI)
<b>All fetuses with CLM</b>				
Regression of the lesion during pregnancy	4	14/26	86.3	61.73 (13.99–97.86)
Perinatal death	9	10/52	0	21.51 (11.88–33.07)
Preterm birth	7	14/47	39	29.42 (14.57–46.95)
Post-natal surgery	5	26/36	0	70.37 (55.18–83.55)
<b>Fetuses with hydrops</b>				
Regression of the lesion during pregnancy	4	12/13	44.5	84.02 (47.60–99.98)
Resolution of the hydrops after treatment	2	5/6	0	78.76 (43.62–98.82)
Perinatal death	10	8/37	21.1	21.91 (9.37–37.88)
Preterm birth	6	10/19	38.8	52.73 (25.54–79.06)
Post-natal surgery	5	9/19	0	48.41 (28.05–69.05)

study include the systematic literature search and the large number of included studies. Nevertheless, the retrospective design and differences among the included populations, the different definitions adopted, the different management protocols and criteria to perform fetal therapy represent the main limitation of this review.

Subgroup analysis according to the sonographic appearance of the lesions were conducted although only few studies reported outcomes according to this while the majority of them only described the sonographic appearance of the lesions and then reported the outcomes for the whole population.

Similarly, despite most of the studies included hydropic fetuses in their cohorts, data on these fetuses were frequently aggregated to the whole cohort limiting the number of studies included in the sub-group analysis on hydrops.

Furthermore, we decided to include only studies reporting data on prenatally identified cohort or paediatric cohort with comprehensive prenatal data in order to avoid the selection bias introduced by including pediatric surgical series. The latter, in fact, reported only data on children undergoing surgery and consequently excluded the most severe cases (i.e. pregnancies complicated by IUD or where parents opted for TOP).

Finally, the outcomes reported were not consistent among studies both in prenatal and post-natal reported information. In particular, the post-natal imaging technique and/or its timing were not consistent as well as the indication and type of surgery performed with high heterogeneity among studies.

However, despite these limitations, this review represents the most up-to-date assessment of this important congenital pathology.

### Comparison with existing literature

This is, to the best of our knowledge, the first systematic review and meta-analysis reporting the outcome of fetuses with CLM diagnosed prenatally. Another systemic review assessing the diagnostic accuracy of congenital airway malformation lung volume (CVR) ratio in identifying those fetuses who will develop hydrops, reported a sensitivity and specificity of this ultrasound parameter in detecting hydrops of 86 and 90 % respectively [57]. Compared to this review, the present meta-analysis reported the natural history of fetuses with CLM *in utero*, perinatal and post-natal outcome of these anomalies.

### Implications for clinical practice and research

This review updated the knowledge on prenatally diagnosed CLM with the most recently published studies showing a very favorable outcome for fetuses with this diagnosis. In fact, up to one third of the lesions decreased in size or disappeared *in utero* while only in 8.5 % of them the lesion increased in the prenatal period. Furthermore, the perinatal outcome of uncomplicated (i.e. without hydrops) CLM is good, being these pregnancies complicated by perinatal death in only 3.5 % of the cases while previous studies have produced highly variable rates of perinatal death from 9 to

49 % [58]. This is likely to be explained by the fact that the rate of prenatal diagnosis of CLM has been increasing over recent years thanks to the improvement in prenatal imaging with an increased identification also of small lesions without additional anomalies or without hydrops at presentation.

The CVR has already been described as a possible a tool to predict the development of hydrops in these fetuses two decades ago. However, since then, no clear international consensus has been reached to define the optimal CVR thresholds and, as recently shown by Kane et al. [59] in their systematic review, further large-scale studies are still required to confirm and define the utility of this index.

The possible role of fetal therapy in these fetuses still needs to be clarified. In fact, the number of included fetuses was small and differences in techniques, protocols and management impairs our ability to produce robust evidence on the use of thoracoamniotic shunt or cyst drainage in these fetuses although cyst drainage can be offered for macrocystic lesion occupying space and shunting is frequently offered in CLM complicated by hydrothorax and/or hydrops [9].

Looking at post-natal outcomes, the rate of neonatal morbidity was only 20.6 %, confirming the fact that most of the fetuses with prenatal diagnosis of CLM are likely to be asymptomatic at birth. However, around 33 % of these fetuses required an emergency surgery due to neonatal symptoms. Moreover, more than half (67 %) of the fetuses with CLM underwent surgery in the series included in this review. In fact, prophylactic elective surgery is usually recommended to avoid the long-term risk of pulmonary infections and to prevent the development of malignancy, despite the true incidence of these adverse outcomes remains debated [10–12]. Therefore, the results of this review should help guiding the counseling with parents of fetuses with a prenatal diagnosis of CLM, who should be reassured of the good prognosis of the lesions when the pregnancy is not complicated by the occurrence of hydrops.

## Conclusions

Fetuses with CLM diagnosed on prenatal ultrasound have a generally favorable outcome. Conversely, there is a low quality of evidence on the actual role of fetal therapy in improving the outcomes of fetuses presenting with these anomalies.

**Research ethics:** Not applicable.

**Informed consent:** Not applicable.

**Author contributions:** The authors have accepted responsibility for the entire content of this manuscript and approved its submission.

**Competing interests:** The authors state no conflict of interest.

**Research funding:** None declared.

**Data availability:** Not applicable.

## References

1. Lakhoo K. Preface *Semin Pediatr Surg* 2015;24:151. ISSN 1055-8586.
2. Chowdhury MM, Chakraborty S. Imaging of congenital lung malformations. *Semin Pediatr Surg* 2015;24:168–75.
3. Berrocal T, Madrid C, Novo S, Gutiérrez J, Arjonilla A, Gómez-León N. Congenital anomalies of the tracheobronchial tree, lung, and mediastinum: embryology, radiology, and pathology. *Radiographics* 2004;24:e17.
4. Stocker JT, Madewell JE, Drake RM. Congenital cystic adenomatoid malformation of the lung. Classification and morphologic spectrum. *Hum Pathol* 1977;8:155–71.
5. Biyyam DR, Chapman T, Ferguson MR, Deutsch G, Dighe MK. Congenital lung abnormalities: embryologic features, prenatal diagnosis, and postnatal radiologic-pathologic correlation. *Radiographics* 2010;30:1721–38.
6. Lee EY, Boiselle PM, Cleveland RH, Multidetector CT. Evaluation of congenital lung anomalies. *Radiology* 2008;247:632–48.
7. Conran RM, Stocker JT. Extralobar sequestration with frequently associated congenital cystic adenomatoid malformation, Type 2: report of 50 cases. *Pediatr Dev Pathol* 1999;2:454–63.
8. Crombleholme TM, Coleman B, Hedrick H, Liechty K, Howell L, Flake AW, et al. Cystic adenomatoid malformation volume ratio predicts outcome in prenatally diagnosed cystic adenomatoid malformation of the lung. *J Pediatr Surg* 2002;37:331–8.
9. Kunisaki SM. Narrative review of congenital lung lesions. *Transl Pediatr* 2021;10:1418–31.
10. Lo AY, Jones S. Lack of consensus among Canadian pediatric surgeons regarding the management of congenital cystic adenomatoid malformation of the lung. *J Pediatr Surg* 2008;43:797–9.
11. Criss CN, Musili N, Matusko N, Baker S, Geiger JD, Kunisaki SM. Asymptomatic congenital lung malformations: is nonoperative management a viable alternative? *J Pediatr Surg* 2018;53:1092–7.
12. Casagrande A, Pederiva F. Association between congenital lung malformations and lung tumors in children and adults: a systematic review. *J Thorac Oncol* 2016;11:1837–45.
13. Eber E. Antenatal diagnosis of congenital thoracic malformations: early surgery, late surgery, or no surgery? *Semin Respir Crit Care Med* 2007;28:355–66.
14. Wells GA, Shea B, O'Connell D, Peterson J, Welch V, Losos M, et al. The newcastle-ottawa scale (NOS) for assessing the quality of nonrandomised studies in meta-analyses. [http://www.ohri.ca/programs/clinical\\_epidemiology/oxford.asp](http://www.ohri.ca/programs/clinical_epidemiology/oxford.asp) [Accessed 15 January 2023].
15. Higgins J, Thompson S, Deeks J, Altman D. Statistical heterogeneity in systematic reviews of clinical trials: a critical appraisal of guidelines and practice. *J Health Serv Res Policy* 2002;7:51–61.
16. Egger M, Davey Smith G, Schneider M, Minder C. Bias in meta-analysis detected by a simple, graphical test. *BMJ* 1997;315:629–34.
17. Hunter JP, Saratzis A, Sutton AJ, Boucher RH, Sayers RD, Bown MJ. In meta-analyses of proportion studies, funnel plots were found to be an inaccurate method of assessing publication bias. *J Clin Epidemiol* 2014;67:897–903.



18. Delacourt C, Bertille N, Salomon LJ, Rahshenas M, Benachi A, Bonnard A, for the MALFPULM study group; members of the MALFPULM study group, et al. Predicting the risk of respiratory distress in newborns with congenital pulmonary malformations. *Eur Respir J* 2022;59:2100949.
19. Karlsson M, Conner P, Ehren H, Bitkover C, Burgos CM. The natural history of prenatally diagnosed congenital pulmonary airway malformations and bronchopulmonary sequestrations. *J Pediatr Surg* 2022;57:282–7.
20. Rolo LC, Ribeiro GD, Caldas JV, Coutinho LG, Muniz TD, Araujo Júnior E. Perinatal outcomes of prenatal diagnosis of congenital pulmonary airway malformation: an experience. *Rev Assoc Med Bras (1992)* 2022; 68:1582–6.
21. An P, Xiao X, Zhao Y, Zhou J, Li X, Xiong Y. Prenatal ultrasound measurements of mild congenital pulmonary airway malformation and long-term prognosis: a retrospective cohort study. *Int J Gynaecol Obstet* 2022;157:327–32.
22. Chen Y, Zhao B, Xi F, Wang Y, Yang M, Luo Q. The prenatal ultrasonic character and postnatal follow-up of 227 microcystic and macrocystic congenital cystic adenomatoid malformations. *J Obstet Gynaecol* 2021; 41:562–8.
23. Wong MCY, Faure Bardon V, Farmakis K, Berteloot L, Lapillonne A, Delacourt C, et al. Ultrasound detected prenatal hyperechoic lung lesions and concordance with postnatal findings: a common aspect for multiple diagnoses. *Prenat Diagn* 2021;41:323–31.
24. Gilad N, Furman Y, Weissmann-Brenner A. A retrospective clinical analysis of 20 cases of congenital lung masses. *J Matern Fetal Neonatal Med* 2022;35:3640–5.
25. Jeong BD, An SA, Lee MY, Won HS, Han M, Yoon H, et al. Comparison of the prognostic factors of fetuses with congenital pulmonary airway malformations according to type. *J Ultrasound Med* 2020;39:2243–52.
26. King A, Lee TC, Steen E, Olutoye OO, Belfort MA, Cassady CI, et al. Prenatal imaging to predict need for urgent perinatal surgery in congenital lung lesions. *J Surg Res* 2020;255:463–8.
27. Anderson JN, Girsan AI, Hintz SR, El-Sayed YY, Davis AS, Barth RA, et al. Obstetric and neonatal outcomes in pregnancies complicated by fetal lung masses: does final histology matter? *J Matern Fetal Neonatal Med* 2021;34:3662–8.
28. Beksac MS, Fadiloglu E, Tanacan A, Unal C, Tepe NB, Aydin E, et al. Outcomes of cases of prenatally-diagnosed congenital pulmonary airway malformation. *Rev Bras Ginecol Obstet* 2019;41:654–9.
29. Cho MK, Lee MY, Kang J, Kim J, Won HS, Lee PR, et al. Prenatal sonographic markers of the outcome in fetuses with bronchopulmonary sequestration. *J Clin Ultrasound* 2020;48:89–96.
30. Molinaro F, Schneider A, Messina M, Becmeur F, Favre R. Congenital pulmonary adenomatoid malformation: indication and management of fetal shunting in our center. *Curr Pediatr Res* 2019;23:82–7.
31. Tuzovic L, Copel JA, Stitelman DH, Levit O, Bahtiyar MO. Utility of fetal cardiac Axis and cardiac position assessment in predicting neonatal respiratory morbidity in fetal congenital lung lesions. *J Ultrasound Med* 2019;38:2361–72.
32. Chon AH, Korst LM, Abdel-Sattar M, Llanes A, Ouzounian JG, Chmait RH. Types II and III congenital pulmonary airway malformation with hydrops treated in utero with percutaneous sclerotherapy. *Prenat Diagn* 2018;38:493–8.
33. Girsan AI, Hintz SR, Sammour R, Naqvi A, El-Sayed YY, Sherwin K, et al. Prediction of neonatal respiratory distress in pregnancies complicated by fetal lung masses. *Prenat Diagn* 2017;37:266–72.
34. Kane SC, Da Silva Costa F, Cramer JA, Reidy KL, Kaganov H, Palma-Dias R. Antenatal assessment and postnatal outcome of fetal echogenic lung lesions: a decade's experience at a tertiary referral hospital. *J Matern Fetal Neonatal Med* 2019;32:703–9.
35. Lin MF, Xie HN, Zhao XH, Peng R, Zheng J, Peng ZP. Systemic venous drainage is associated with an unfavorable prenatal behavior in fetal bronchopulmonary sequestration. *Fetal Diagn Ther* 2018;44: 291–8.
36. Makhijani AV, Wong FY. Conservative post-natal management of antenatally diagnosed congenital pulmonary airway malformations. *J Paediatr Child Health* 2018;54:267–71.
37. Walker L, Cohen K, Rankin J, Crabbe D. Outcome of prenatally diagnosed congenital lung anomalies in the North of England: a review of 228 cases to aid in prenatal counselling. *Prenat Diagn* 2017;37: 1001–7.
38. Hellmund A, Berg C, Geipel A, Bludau M, Heydweiller A, Bachour H, et al. Prenatal diagnosis and evaluation of sonographic predictors for intervention and adverse outcome in congenital pulmonary airway malformation. *PLoS One* 2016;11:e0150474.
39. Lau CT, Kan A, Shek N, Tam P, Wong KK. Is congenital pulmonary airway malformation really a rare disease? Result of a prospective registry with universal antenatal screening program. *Pediatr Surg Int* 2017;33: 105–8.
40. Xia B, Yu G, Liu C, Hong C, Tang J. Surgical treatment of congenital cystic adenomatoid malformation: a retrospective study of single tertiary center experience. *J Matern Fetal Neonatal Med* 2017;30:416–9.
41. Feghali M, Jean KM, Emery SP. Ultrasound assessment of congenital fetal lung masses and neonatal respiratory outcomes. *Prenat Diagn* 2015;35:1208–12.
42. Kunisaki SM, Ehrenberg-Buchner S, Dillman JR, Smith EA, Mychaliska GB, Treadwell MC. Vanishing fetal lung malformations: prenatal sonographic characteristics and postnatal outcomes. *J Pediatr Surg* 2015;50:978–82. W.B. Saunders.
43. Stoiber B, Moehrlen U, Kurmanavicius J, Meuli M, Haslinger C, Zimmermann R, et al. Congenital lung lesion: prenatal course, therapy and predictors of perinatal outcome. *Ultraschall der Med* 2017;38: 158–65.
44. Bondioni MP, Gatta D, Lougaris V, Palai N, Signorelli M, Michelini S, et al. Congenital cystic lung disease: prenatal ultrasound and postnatal multidetector computer tomography evaluation. Correlation with surgical and pathological data. *Radiol Med* 2014;119:842–51.
45. Mallmann MR, Geipel A, Bludau M, Matil K, Gottschalk I, Hoopmann M, et al. Bronchopulmonary sequestration with massive pleural effusion: pleuroamniotic shunting vs intrafetal vascular laser ablation. *Ultrasound Obstet Gynecol* 2014;44:441–6.
46. Ng C, Stanwell J, Burge DM, Stanton MP. Conservative management of antenatally diagnosed cystic lung malformations. *Arch Dis Child* 2014; 99:432–7.
47. Ruchonnet-Metrailler I, Leroy-Terquem E, Stirnemann J, Cros P, Ducoin H, Hadchouel A, et al. Neonatal outcomes of prenatally diagnosed congenital pulmonary malformations. *Pediatrics* 2014;133: e1285–91.
48. Zhang H, Tian J, Chen Z, Ma X, Yu G, Zhang J, et al. Retrospective study of prenatal diagnosed pulmonary sequestration. *Pediatr Surg Int* 2014; 30:47–53.
49. Alamo L, Reinberg O, Vial Y, Gudinchet F, Meuli R. Comparison of foetal US and MRI in the characterisation of congenital lung anomalies. *Eur J Radiol* 2013;82:e860–6.

50. Beydon N, Larroquet M, Coulomb A, Jouannic JM, Ducou le Pointe H, Clément A, et al. Comparison between US and MRI in the prenatal assessment of lung malformations. *Pediatr Radiol* 2013;43:685–96.
  51. Ho G, Cheung KW, Lam HL, Ip JK, Tang HYM, Lam WWM. Echogenic and cystic fetal lung lesions: evaluation by prenatal sonography and postnatal imaging. *Hong Kong J Radiol* 2013;16:5–16.
  52. Lima JS, Camargos PA, Aguiar RA, Campos AS, Aguiar MJ. Pre and perinatal aspects of congenital cystic adenomatoid malformation of the lung. *J Matern Fetal Neonatal Med* 2014;27:228–32.
  53. Muller CO, Berrebi D, Kheniche A, Bonnard A. Is radical lobectomy required in congenital cystic adenomatoid malformation? *J Pediatr Surg* 2012;47:642–5.
  54. Yong PJ, Von Dadelszen P, Carpara D, Lim K, Kent N, Tessier F, et al. Prediction of pediatric outcome after prenatal diagnosis and expectant antenatal management of congenital cystic adenomatoid malformation. *Fetal Diagn Ther* 2012;31:94–102.
  55. Hadchouel A, Benachi A, Revillon Y, Rousseau V, Martinovic J, Verkarre V, et al. Factors associated with partial and complete regression of fetal lung lesions. *Ultrasound Obstet Gynecol* 2011;38:88–93.
  56. Raychaudhuri P, Pasupati A, James A, Whitehead B, Kumar R. Prospective study of antenatally diagnosed congenital cystic adenomatoid malformations. *Pediatr Surg Int* 2011;27:1159–64.
  57. Zhu P, Cheng K, He M, Wang Y, Shen P, He K, et al. Diagnostic value of congenital pulmonary airway malformation volume ratio for fetal hydrops due to congenital lung malformations: a systematic review and meta-analysis. *Orphanet J Rare Dis* 2022;17:213.
  58. Ierullo AM, Ganapathy R, Crowley S, Craxford L, Bhide A, Thilaganathan B. Neonatal outcome of antenatally diagnosed congenital cystic adenomatoid malformations. *Ultrasound Obstet Gynecol* 2005;26:150–3.
  59. Kane SC, Ancona E, Reidy KL, Palma-Dias R. The utility of the congenital pulmonary airway malformation-volume ratio in the assessment of fetal echogenic lung lesions: a systematic review. *Fetal Diagn Ther* 2020;47:171–81. Epub 2019 Oct 8. PMID: 31593968.
- 
- Supplementary Material:** This article contains supplementary material (<https://doi.org/10.1515/jpm-2024-0017>).