

Computed tomography and nuclear medicine for the assessment of coronary inflammation: clinical applications and perspectives

Andrea Igoren Guaricci^{a,*}, Danilo Neglia^{b,*}, Wanda Acampa^c, Daniele Andreini^{d,e}, Andrea Baggiano^{d,e}, Francesco Bianco^f, Nazario Carrabba^g, Edoardo Conte^{d,h}, Valeria Gaudieri^c, Saima Mushtaq^d, Gianluigi Napoli^a, Valeria Pergolaⁱ, Gianluca Pontone^d, Roberto Pedrinelli^j, Giuseppe Mercurio^k, Ciro Indolfi^l and Marco Guglielmo^m, On behalf of the Working Group CT & Nuclear of the Italian Society of Cardiology

There is increasing evidence that in patients with atherosclerotic cardiovascular disease (ASCVD) under optimal medical therapy, a persisting dysregulation of the lipid and glucose metabolism, associated with adipose tissue dysfunction and inflammation, predicts a substantial residual risk of disease progression and cardiovascular events. Despite the inflammatory nature of ASCVD, circulating biomarkers such as high-sensitivity C-reactive protein and interleukins may lack specificity for vascular inflammation. As known, dysfunctional epicardial adipose tissue (EAT) and pericoronary adipose tissue (PCAT) produce pro-inflammatory mediators and promote cellular tissue infiltration triggering further pro-inflammatory mechanisms. The consequent tissue modifications determine the attenuation of PCAT as assessed and measured by coronary computed tomography angiography (CCTA). Recently, relevant studies have demonstrated a correlation between EAT and PCAT and obstructive coronary artery disease, inflammatory plaque status and coronary flow reserve (CFR). In parallel, CFR is well recognized as a marker of coronary vasomotor function that incorporates the haemodynamic effects of epicardial, diffuse and small-vessel disease on myocardial tissue perfusion. An inverse relationship between EAT volume and coronary vascular function and the association of PCAT attenuation and impaired CFR have already been reported. Moreover, many studies demonstrated that 18F-FDG PET is able to detect PCAT inflammation in patients with coronary atherosclerosis. Importantly, the perivascular FAI (fat attenuation index) showed incremental value for the

prediction of adverse clinical events beyond traditional risk factors and CCTA indices by providing a quantitative measure of coronary inflammation. As an indicator of increased cardiac mortality, it could guide early targeted primary prevention in a wide spectrum of patients. In this review, we summarize the current evidence regarding the clinical applications and perspectives of EAT and PCAT assessment performed by CCTA and the prognostic information derived by nuclear medicine.

J Cardiovasc Med 2023, 24 (suppl 1):e67–e76

Keywords: 18F-FDG PET, coronary artery disease, coronary computed tomography angiography, epicardial adipose tissues, pericoronary adipose tissues

^aUniversity Cardiology Unit, Department of Interdisciplinary Medicine, University of Bari Aldo Moro, Bari, ^bCardiovascular Department, Fondazione Toscana Gabriele Monasterio (FTGM), Pisa, ^cDepartment of Advanced Biomedical Sciences, University of Naples 'Federico II', Naples, ^dCentro Cardiologico Monzino IRCCS, ^eDepartment of Clinical Sciences and Community Health, Cardiovascular Section, Milan, ^fCardiovascular Sciences Department - AOU 'Ospedali Riuniti', Ancona, ^gDepartment of Cardiothoracovascular Medicine, Azienda Ospedaliero-Universitaria Careggi, Florence, ^hDepartment of Biomedical Sciences for Health, University of Milan, Milan, ⁱDepartment of Cardiac, Thoracic and Vascular Sciences and Public Health, University of Padova, Padova, ^jCardiac, Thoracic and Vascular Department, University of Pisa, Pisa, ^kDepartment of Medical Sciences and Public Health, University of Cagliari, Cagliari, ^lDepartment of Medical and Surgical Sciences, Magna Graecia University, Catanzaro, Italy and ^mDepartment of Cardiology, Division of Heart and Lungs, University Medical Center Utrecht, Utrecht University, Utrecht, The Netherlands

Correspondence to Andrea Igoren Guaricci, MD, PhD, FESC, Piazza Giulio Cesare 11, Bari 70124, Italy
Tel: +39 080 5592740; e-mail: andreaigoren.guaricci@uniba.it

Received 31 July 2022 Revised 8 December 2022
Accepted 10 December 2022

Introduction

At its inception, coronary computed tomography angiography (CCTA) took its first steps with limited technology.^{1–5} The dramatic improvement in the technique has brought very high values in the accuracy for coronary artery disease (CAD) detection and grading ranging from

85% to 100%.^{6–8} As a consequence, current indications of CTA include a large spectrum of patients with suspected CAD.^{9–11} Detailed visualization of plaque components has allowed the identification of high-risk and vulnerable plaque features, which has led to the improvement in the prognostic power of the technique.^{12–14} Nowadays, the applications of the fractional flow reserve derived from CT (FFR_{CT}) and the stress CT perfusion (CTP)

* Andrea Igoren Guaricci and Danilo Neglia contributed equally as first authors.

allow the combination of anatomic and functional assessment of CAD with excellent diagnostic and prognostic accuracy (Fig. 1).^{15–18} A recent breakthrough in CCTA allows the quantification of pericoronary adipose tissue (PCAT) attenuation and the calculation of epicardial adipose tissue (EAT) as being strictly linked with the progression of CAD.^{19–21} In parallel, nuclear perfusion imaging has demonstrated its ability in documenting significant inducible ischemia in the presence of coronary atherosclerosis also before an obstructive coronary lesion develops.²² Moreover, coronary flow reserve (CFR) assessed by PET provides important prognostic information in patients with or without known CAD.^{23,24} Importantly, ¹⁸F-FDG PET has been shown to be able to detect PCAT inflammation in patients with coronary atherosclerosis.²⁵ This review explores the clinical role and future perspectives of EAT and PCAT evaluation made by CCTA and prognostic information derived from PET-focused nuclear medicine.

Pericoronary and epicardial adipose tissue activity

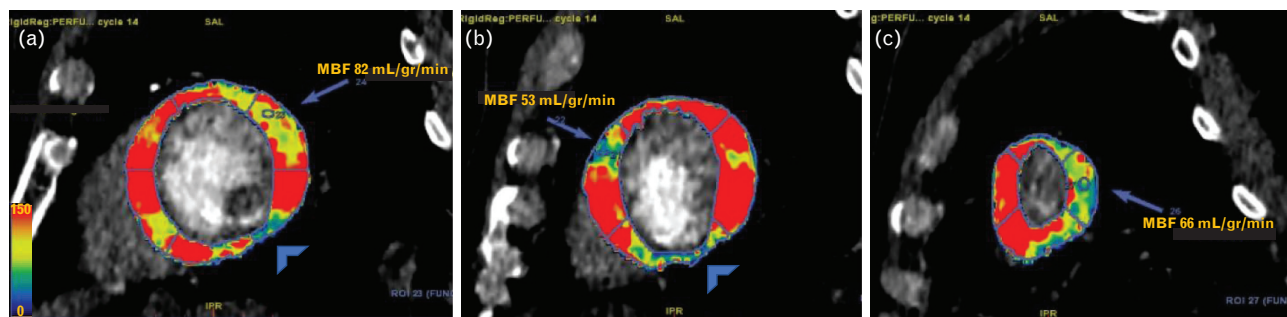
Visceral fat, especially intra-abdominal fat, has a well recognized role in the development of the so-called metabolic syndrome.²⁶ Nevertheless, mediastinal and epicardial fat, as well as other extra-abdominal fat deposits, are now in the spotlight. Epicardial adipose tissue, which is more closely related to visceral than total fat, originates from brown adipose tissue and is located between the myocardium and visceral pericardium. Fully differentiated adipocytes can be usually found in the atrioventricular and inter-ventricular sulcus extending to the apex, around the two appendages and, less frequently, in the free walls of the atria.²⁷ It accounts for

around 20% of total ventricular mass with a consensual and proportional increase in epicardial adipose mass during cardiac hypertrophy which results in a constant fat/muscle ratio.^{28,29} Unlike skeletal muscle, wherein a fascia distinctly separates adipocytes and muscular cells, the close anatomical relationship between these structures in the heart reflects their functional interdependence.

The biochemical properties of EAT go beyond the storage of excess calories, and a relevant role in metabolic, vascular, immunological and inflammatory responses has been demonstrated. Under ischemic conditions, EAT is a ready source of free fatty acids able to supply increased myocardial energy consumption through its high lipolytic activity. Furthermore, it represents a buffering system against lipotoxicity, as disproportionately high levels of fatty acids have accounted for ventricular dysfunction, repolarization abnormalities and arrhythmias.³⁰

Moreover, a paracrine regulation of vascular homeostasis by PCAT/EAT has also been demonstrated. In the presence of CAD, the radical oxygen species generated in response to regional ischemia seems to activate an EAT-driven inflammatory signal with the release of chemokines and inflammatory cytokines (including interleukin-1 β , interleukin-6, interleukin-6 soluble receptor and tumour necrosis factor- α).³⁰ Endothelial dysfunction may be enhanced by induced decreased nitric oxide production, and smooth muscle cell proliferation.^{31,32} At the same time, concomitant reduction in the expression of adiponectin, an adipocyte-derived protein with anti-inflammatory and antiatherogenic properties, has been shown.^{33,34} This leads to amplification of vascular inflammation, plaque instability and

Fig. 1



Myocardial stress computed tomography perfusion. A 62-year-old patient with a positive history of inferior myocardial infarction, previous percutaneous coronary intervention + drug-eluting stent (PCI + DES) on left anterior descending artery (LAD) and right coronary artery (RCA) in multiple cardiovascular risk factors. Coronary computed tomography angiography (CCTA) showed LDA in the mid-proximal tract stenting difficult to evaluate due to an intense blooming effect, in the mid-distal tract of the vessel mixed plaque with stenosis more than 50%; left circumflex artery (LCx) at the proximal and middle tracts disease of mixed nature, predominantly calcific, determining mild degree stenosis; CDx, dominant, presents at the proximal tract diffuse disease, predominantly calcific, determining moderate degree stenosis, at the level of the middle tract a patent stent, and in the middle-distal tract mixed disease, predominantly fibrolipidic, determining moderate stenosis. After pharmacological stimulation with Regadenoson (400 μ g 1 fl bolus ev), scanning with a dynamic perfusion technique was performed. Stress myocardial perfusion study showed pathological MBF values at the middle anterolateral wall, middle anterior septum and apex (blue arrowheads in a, b, c). The inferior wall looks thin and necrotic (blue arrowheads in a, b). LAD was revascularized by PCI and stenting.

neovascularization, stimulating an angiogenic response and the development of collateral circulation in patients with obstructive CAD.³³

In addition, a clear involvement of EAT in the cardiac response to sympathetic stimuli has been proven in heart failure. In the context of sympathetic nervous system hyperactivity, EAT shows an enhanced adrenergic activity, with the expression of catecholamine biosynthetic enzymes and a two-fold higher concentration of norepinephrine than plasma, which generates a negative feedback on cardiac sympathetic nerves, thus inducing a functional and anatomic denervation of the heart.³⁵

Correlation between epicardial adipose tissue/pericoronary adipose tissue and obstructive coronary artery disease

Coronary computed tomography angiography has recently been complemented by the measurement and characterization of EAT and PCAT, with no extra radiation exposure and extra cost, as additional tools to stratify patient risk. Several studies reported the association of EAT volume with the presence and severity of coronary stenosis detected by CCTA or by invasive coronary angiography (ICA).^{31,36,37} Mancio *et al.*³¹ published a meta-analysis confirming that EAT volume is independently and positively associated with obstructive or significant coronary stenosis (luminal narrowing ≥ 50 and $\geq 70\%$, respectively), myocardial ischemia and major adverse cardiovascular events (MACE). A recent multicentre study showed that EAT volume could enhance the predictive ability of pretest probability of obstructive CAD over clinical risk factors and coronary artery calcium (CAC) score.³⁸ Other studies focused on the correlation of measurements of PCAT volume with coronary stenosis. Hassan *et al.*³⁹ measured segmental EAT volume around eight coronary segments in patients with stable angina by cardiac magnetic resonance (CMR) and found a significant association with the extent and severity of coronary lesions and features of plaque vulnerability at CCTA.

On the contrary, PCAT inflammation, detected by the degree of PCAT density/attenuation at CT, has been associated with the presence, severity, extent and adverse features of coronary atherosclerotic plaques independently of traditional cardiovascular risk factors and ethnicity.^{40,41} The associations of PCAT CT attenuation, with the presence of obstructive CAD and the effects of CAD on myocardial perfusion and prognosis, have been explored using the combination of CCTA with myocardial perfusion imaging by nuclear modalities. In fact, PET (PET/CT) and more recently single photon emission computed tomography (CZT-SPECT) allow absolute quantitative measurement of myocardial blood flow (MBF) and of myocardial perfusion reserve (MPR). Absolute flow measurements provide not only incremental diagnostic value in identifying obstructive CAD over regional perfusion and irrespective of CT CAC burden

but also incremental prognostic power over a CCTA positive for obstructive or nonobstructive CAD.^{42–45} In patients with suspected CAD, the evidence of PCAT inflammation by CT attenuation was recently associated with downstream MPR measured by using PET also in patients with lower CAC score or without obstructive lesions at CCTA underlying the relevance of PCAT inflammatory status as a determinant of CAD-related risk.⁴⁶

Correlation between epicardial adipose tissue/pericoronary adipose tissue and inflammatory markers

Inflammation is one of the key factors in atherogenesis and pro-inflammatory mediators produced by monocytes and T cells contribute to both plaque progression and destabilization leading to acute coronary syndromes.^{47–50}

In patients with stable angina, there is evidence that circulating levels of high-sensitivity C-reactive protein (hs-CRP) or interleukin-6 (IL-6) predict functionally significant CAD and high-risk coronary anatomy at CCTA.^{22,51} Moreover, whole-blood transcriptional profiles, including genes involved in the inflammatory response, have been shown to discriminate patients with significant coronary stenoses and predict adverse plaque characteristics.⁵² Circulating levels of IL-6 are associated with the risk of cardiovascular death, myocardial infarction (MI) and hospitalization for heart failure in patients with stable CAD under optimal medical treatment and serum hs-CRP levels appear to be higher in patients with acute MI than in those with stable CAD.^{53,54} Although these are excellent biomarkers of systemic inflammation, they are not specific for coronary inflammation and provide little information on local vascular biological processes. Therefore, evaluation of more local biomarkers of coronary inflammation is needed.²¹ PCAT could be a major driver in vascular physiology, as adipo-cytokines secreted from it could affect the biology of adjacent vessels in a paracrine way; on the contrary, modifications in PCAT composition are observed in response to inflammatory stimuli derived from the vascular wall.⁴⁰ In particular, a change in PCAT attenuation around an inflamed artery could be easily detected by CCTA, but a clear correlation between serum inflammation biomarkers and PCAT inflammation is not always demonstrable. It has been observed that PCAT attenuation is significantly higher in patients with acute MI than in those with stable CAD and also significantly higher in patients with stable CAD than in controls. On the contrary, although hs-CRP is higher in patients with MI and is an independent predictor of disease severity and outcome in patients with stable CAD, there is no significant overall difference in circulating hs-CRP between patients with stable CAD and controls. These findings may reflect the low grade of coronary inflammation associated with atherosclerosis that is better detected by PCAT attenuation.^{22,55,56}

PET/CT imaging of 18F-Fluorodeoxyglucose (18F-FDG) or, more recently, 68Ga-Dotatate (68Ga-DOT) tissue uptake are established imaging biomarkers of vascular inflammation *in vivo*.⁵⁷ 18F-FDG uptake at the PCAT level is higher in patients with significant CAD or vasospastic angina than in controls, correlating with the extent of CAD in overweight individuals.^{58,59} The relationships between CT and PET/CT imaging markers of PAAT and PCAT inflammation have been recently explored in patients with Takayasu arteritis (TAK), with or without CAD.⁶⁰ PAAT and PCAT density on CCTA were higher in patients with TAK than in CAD or control individuals. PCAT density was associated with evidence of coronary inflammation documented by using 68Ga-DOT PET and linked with circulating markers of inflammation (hs-CRP) and TAK disease activity.

All these findings support the use of PCAT noninvasive imaging, by CT and PET/CT, as a biomarker of coronary arterial inflammation in atherosclerosis and its promising role as an incremental predictor of outcome and high-risk coronary plaque features above clinical risk factors and circulating biomarkers.^{19,21}

Correlation between epicardial adipose tissue/pericoronary adipose tissue and inflammatory plaque status

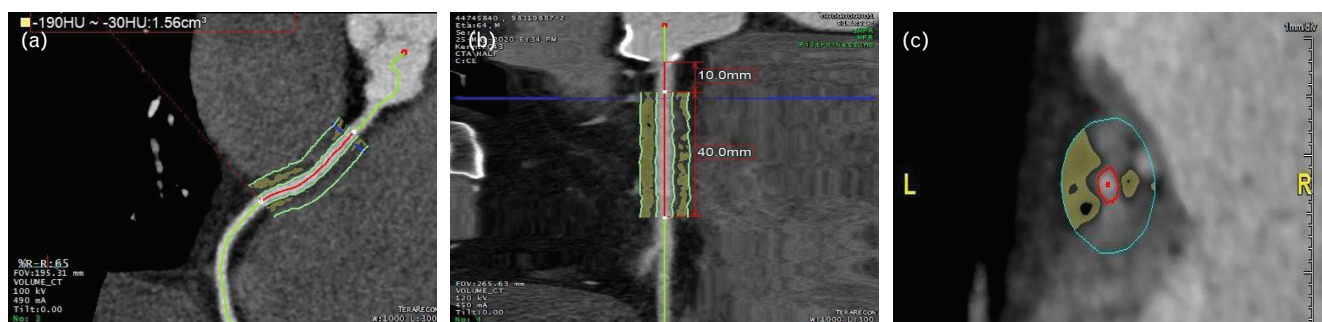
The advent in the clinical and research fields of cardiac CT during the last two decades has enabled noninvasive identification of coronary atherosclerosis and highlighted the prognostic role of high-risk atherosclerosis itself beyond coronary lumen stenosis severity.^{61,62} High-risk coronary plaque features are associated with inflammatory biomarkers such as hs-CRP and pentraxin-3, supporting the hypothesis that inflammation could play a pivotal role in the vulnerable plaque process to instability leading to acute coronary syndrome.⁴⁹ EAT, and more specifically PCAT, have been recently demonstrated as the site of inflammatory pathways activation via paracrine

and vasocrine effects resulting in endothelial dysfunction from decreased nitric oxide production, hypercoagulability and vascular smooth muscle cell proliferation.⁶³ When assessed by using CCTA, PCAT is imaged with attenuation ranging from -190 to -30 HU depending on its normal status or inflamed condition, respectively (Fig. 2).

In a recent post hoc analysis of the SCOT-HEART study, authors reported a significant association between increased PCAT attenuation and high-risk coronary plaque features (i.e. LAP) at CCTA in patients with stable CAD.⁶⁴ Both parameters were related to cardiovascular prognosis, but no clear relationship was established between PCAT attenuation and circulating inflammatory biomarkers, supporting the hypothesis that PCAT attenuation may detect a specific coronary inflammatory status that is otherwise undetectable by systemic markers of inflammation. Goeller *et al.*⁶⁵ found a close relationship between PCAT attenuation and high-risk coronary plaque demonstrating the association between noncalcified plaque burden and PCAT inflammatory activity; on the contrary, PCAT attenuation was not associated with calcified plaque burden. A recently published study enrolling 198 patients with NSTEMI who underwent both cardiac CT and optical computer tomography (OCT) of the culprit lesion prior to intervention demonstrated that PCAT attenuation in culprit plaque was higher in patients with plaque rupture than in those with plaque erosion suggesting that pancoronary inflammation is involved more in plaque rupture than in plaque erosion.⁶⁶

Increased coronary 18F-sodium fluoride (18F-NaF) uptake at PET/CT occurs in lesions associated with acute coronary syndromes and reflects microcalcifications occurring in response to coronary inflammation.⁶⁷ In patients with high-risk plaque features, Kwiecinski *et al.*²⁵ demonstrated that lesion PCAT density and LAP volume were independent predictors of increased

Fig. 2



Pericoronary adipose tissue. (a) Three-dimensional (3D) coronary CT reconstruction of the right coronary artery (RCA) obtained using Aquarius TeraRecon. (b) Selection of the region of interest analysis showing the distribution of values between -190 and -30 HU. (c) Short axis view of the region of interest showing the distribution of values between -190 and -30 HU.

18F-NaF uptake. All these data strengthen the hypothesis that coronary plaque instability is driven by an inflammatory process.

Correlation between epicardial adipose tissue/pericoronary adipose tissue and coronary flow reserve

Measurement of FFR correlates with the prediction of acute cardiac events and the FFR value is currently considered the standard reference for guiding revascularization.^{68–70} Hoshino *et al.*⁷¹ investigated the association between PCAT attenuation, as expressed by the fat attenuation index (FAI), and whole vessel and lesion plaque quantification on CCTA in 187 stable patients with intermediate stenosis evaluated by using FFR. At multivariate analysis, male sex, CCTA-derived positive remodelling, lower minimum lumen area and lower FFR were independent predictors of FAI.⁷¹ CCTA-derived 2D and 3D analysis and FAI were independently associated with FFR values.

FFR_{CT} has been shown to be accurate in detecting ischemia compared with invasively measured FFR, effective in assessing prognosis and cost-effective.^{72–74} Yu *et al.*⁷⁵ investigated the association between perivascular FAI and the haemodynamic significance of coronary lesions. In a cohort of 167 patients, authors showed that diameter stenosis, lesion length, total plaque volume and perivascular FAI were significantly larger or longer in the group of haemodynamically significant lesions. At multivariate analysis, diameter stenosis, total plaque volume and perivascular FAI were significant predictors of lesion-specific ischemia.

Duncker *et al.*⁷⁶ investigated the association between CT-derived characterization of different cardiac fat compartments and myocardial ischemia, as assessed by FFR_{CT}. In a cohort of 133 patients, authors found that individuals with myocardial ischemia showed significantly higher RCA PCAT attenuation than individuals without myocardial ischemia. Interestingly, there was no significant difference between individuals with or without myocardial ischemia in the volume and attenuation of EAT and PAT or in the PCAT volume.

Coronary vascular function is accurately assessed by using PET/CT with the quantification of MBF and MPR, integrating epicardial and microvascular circulations. The added value of MBF and MPR has been shown both in the detection of impaired vasodilator capacity of the coronary circulation and in the prognostic assessment of patients with suspected or known CAD.^{77–79} Several studies have focused on the relationship between EAT, PCAT and coronary vascular function. Bucci *et al.*⁸⁰ found an inverse relationship between hyperemic MBF and EAT in patients with and without CAD, suggesting that EAT could promote endothelial dysfunction and impaired MBF could aggravate adipose tissue hypoxia

triggering a vicious circle. Nappi *et al.*⁸¹ observed that in patients without overt CAD and normal myocardial perfusion imaging, EAT volume is associated with hyperemic MBF and MPR, confirming the influence of EAT also on microcirculation. PCAT attenuation has been found to be significantly associated with MPR in patients with intermediate risk of CAD; in particular, in patients without obstructive CAD, MPR was lower in the presence of high PCAT attenuation.⁴⁶

Prognostic value of pericoronary adipose tissue in suspected coronary artery disease beyond high-risk coronary plaques and ischemia

Residual CAD-related risk, that is the risk which persists despite optimal treatment of established risk factors, is an emerging determinant of prognosis and is associated with abnormal lipid metabolism and vascular inflammation.^{82,83} Accordingly, there is growing evidence that an accurate assessment of vascular inflammation might improve risk stratification and allow tailored treatment in CAD patients.⁸⁴ Currently, detection of coronary inflammation is hampered by a lack of specificity (e.g. serum biomarkers) or by the limited availability and relatively high costs of PET/CT imaging.⁴⁰ CCTA as a widely available and used diagnostic tool might mediate these limitations by being able to detect the morphological changes of the PCAT adipocytes, induced by mediators released by inflamed coronary arteries, which can be quantified by using PCAT attenuation.³³ The CRISP-CT (Cardiovascular Risk Prediction Using Computed Tomography) study has shown that FAI of the right (RCA) and left descending (LAD) coronary arteries was of prognostic importance over clinical characteristics, qualitatively assessed extent of CAD and high-risk coronary plaque (HRP) features.²¹ The increased risk of all-cause mortality in patients with high FAI was driven by a higher rate of cardiac deaths. In a subanalysis of the CRISP-CT study, patients with high FAI and HRP features were at an increased risk of suffering events, whereas patients with low FAI and HRP features were not.¹⁹ The association of PCAT attenuation with MI has previously been demonstrated by Goeller *et al.*⁸⁵ who observed higher PCAT attenuation values surrounding culprit lesions of MI patients as compared with nonculprit lesions, healthy controls and patients with stable CAD. In recent reports, only RCA PCAT attenuation retained prognostic value beyond quantitative plaque volume, HRPs and myocardial ischemia.⁸⁶ A possible explanation for this discordancy is the fact that PCAT is more prevalent around the RCA as compared with the left coronary system and has less hindering nonfatty structures (e.g. side branches and myocardium) in its proximity.^{40,85} Therefore, RCA PCAT attenuation has been proposed as a robust and easily accessible measurement of global inflammatory status and prognostic risk.

Prognostic value of pericoronary adipose tissue in asymptomatic patients beyond coronary artery disease

Beyond CAD, PCAT is increasingly gaining attention as a cardiovascular noninvasive biomarker. PCAT attenuation of both RCA and LAD could serve as an independent predictor of endothelial dysfunction, as assessed by using the flow-mediated dilation of the brachial artery or by MPR.^{46,87} Brachial flow-mediated dilation is a well established independent predictor of cardiovascular events in different patient populations and an indicator of cardiovascular health, apart from CAD and chest pain, whereas MPR is a marker of coronary vascular dysfunction, which is associated with poor prognosis in patients with normal or nonobstructive CAD.^{88,89} In non-CAD patients, some authors recently demonstrated the predictive role of PCAT in different populations, particularly in patients with atrial fibrillation, type 2 diabetes mellitus and spontaneous coronary artery dissection (SCAD).

Nogami *et al.*,⁹⁰ in a population of 323 patients with paroxysmal atrial fibrillation, demonstrated an association between PCAT and its recurrences after a second-generation cryoballoon ablation in a total follow-up of 3 months. Regarding type 2 diabetes mellitus patients, it has been observed that in nonsymptomatic diabetic patients high LAD PCAT attenuation predicts cardiovascular events, defined as cardiac death, hospitalization for acute coronary syndrome, late coronary revascularization and hospitalizations for heart failure.⁹¹ It is well known that diabetic patients, even without other risk factors and without symptoms suggestive of CAD, have lower MBF and MPR values than nondiabetic individuals and these parameters are able to identify diabetic patients at a higher risk of events.^{79,92,93} It has been suggested that microvascular dysfunction could be a consequence of prolonged chronic inflammation, which is also related to the pathogenesis of diabetes and related complications.^{94,95} Therefore, imaging inflammatory pathways by LAD PCAT assessment and identifying coronary vascular dysfunction can help individuate high-risk type 2 diabetes mellitus patients regardless of their symptoms and prestress test probability.

In 2018 and 2019, respectively, Tweet *et al.*⁹⁶ and Hedgire *et al.*⁹⁷ reported an increased perivascular fat stranding in SCAD patients. This finding suggested that aside from traditional risk factors for cardiovascular disease, perivascular fat stranding could result in a local inflammatory process that triggers eosinophilic inflammatory infiltrates, precursors of SCAD and intramural haematoma.⁹⁸ These studies indicate that vascular inflammation may play a role in the pathophysiology of SCAD, but more extensive studies are needed to confirm and validate these findings.⁹⁹ Finally, as different blood levels of n-3 fatty acids are associated with differences in PCAT attenuation, early detection of both RCA and LAD PCAT attenuation might significantly improve

cardiovascular risk stratification and target anti-inflammatory treatment, probably with eicosapentaenoic acid (EPA) supplementation in asymptomatic patients without CAD.¹⁰⁰

Prognostic value of epicardial adipose tissue/pericoronary adipose tissue in a specific scenario: COVID-19 patients, transcatheter aortic valve implantation patients

Obesity and severe obesity have been shown to increase the risk of hospitalization, ICU admission and death among patients with COVID-19.^{101,102} Furthermore, excessive visceral adiposity appears to be associated with severe COVID-19 outcomes.¹⁰³ It has been suggested that EAT volume could help in the stratification of prognostic risk of patients with COVID-19.^{104,105} In particular, the integration of EAT volume into the clinical risk score for patients with COVID-19 can potentially improve the prediction of adverse outcomes. In particular, an EAT volume of at least 97 cm³ has been shown to be associated with a risk of a greater extent of COVID-19 pneumonia and ICU admission.¹⁰⁶ The release of proinflammatory cytokines from EAT into the general bloodstream may contribute to a systemic inflammatory state in COVID-19 patients and systemic inflammation that, in turn, promotes the accumulation of EAT.¹⁰⁷ Turker Duyuler *et al.*¹⁰⁸ investigated the association between EAT and PCAT thicknesses measured using CT and severity of COVID-19 infection in 504 patients. EAT and PCAT were significantly increased in ICU patients and, in multiple logistic regression analyses, were independent predictors of ICU admission. These findings suggest that EAT and PCAT may play an important role in the development of a greater burden of COVID-19 pneumonia and both may represent an important imaging biomarker that can predict a worse progression of disease. EAT and PCAT volume imaging could have potential therapeutic implications, representing a clinically measurable and modifiable therapeutic target by drugs that modulate adipose tissue, such as ACE inhibitors, dipeptidyl peptidase 4 (DPP4) inhibitors and statins, usually indicated in patients with diabetes and metabolic syndrome and recently shown to be involved in the pathogenesis of COVID-19 pneumonia.¹⁰⁹

Eberhard *et al.*¹¹⁰ demonstrated that EAT volume is independently associated with all-cause mortality and a positive early safety end point after transcatheter aortic valve replacement (TAVR). In particular in patients undergoing TAVR, EAT volume assessed by using preprocedural CT is independently associated with all-cause 1-, 2- and 3-year mortality and with an early safety end point at 30 days. As almost all TAVR candidates are undergoing preprocedural CT, EAT volume evaluation may provide incremental prognostic value in risk assessment of TAVR candidates, without any additional radiation (Table 1).

Table 1 Prognostic role of EAT/PCAT

Study	Target population	Prognostic variables	Prognostic findings
CRISP-CT post hoc analysis ¹⁹	2040 patients with CAD	FAI	↑ FAI was associated with an increased risk of cardiac deaths and nonfatal myocardial infarction in patients both with (HR 7.29; 95% CI 3.36–15.81; $P < 0.001$) or without (HR 5.62, 95% CI 3.02–10.47); $P < 0.001$) HRP
Van Diemen <i>et al.</i> ⁸⁶	539 patients with suspected CAD	PCAT	In multivariate analysis, RCA PCAT attenuation was associated with higher risk of death and/or nonfatal myocardial infarction (HR 2.45; 95% CI 1.23 – 4.93; $P = 0.011$)
Nogami <i>et al.</i> ⁹⁰	364 patients with persistent and paroxysmal AF undergoing successful CBA	PCAT	In multivariate analysis, PCAT was an independent predictor of recurrence of AF after cryoablation (HR 1.034; 95% CI 1.001–1.069; $P = 0.046$)
Ichikawa <i>et al.</i> ⁹¹	333 patients with T2DM	PCAT	In multivariate analysis, ↑ LAD PCAT attenuation was associated with higher risk of cardiac death, hospitalization for ACS, late coronary revascularization, and hospitalization for HF (HR 2.689, 95% CI 1.166–6.199; $P = 0.026$)
Marcucci <i>et al.</i> ¹⁰⁶	60 patients with COVID-19 pneumonia	EAT	↑ EAT was associated with increased risk of a greater extent of pulmonary involvement and therefore a worse clinical outcome in patients with SARS-CoV-2 pneumonia (HR 11.667; 95% CI 3.384–40.220; $P < 0.001$)
Turker Duyuler <i>et al.</i> ¹⁰⁸	504 patients hospitalized for COVID-19	EAT and PCAT	In multivariate analysis, EAT and PCAT were independent predictors of ICU admission
Eberhard <i>et al.</i> ¹¹⁰	503 patients undergoing TAVR	EAT	EAT volume is independently associated with all-cause 1-, 2- and 3-year mortality after TAVR in Kaplan–Meier analyses using different binary cut-off values of 100 μ l (log-rank $P = 0.002$; HR: 1.94, 95% CI: 1.15–3.26), 125 μ l (log-rank $P = 0.001$; HR: 1.70, 95% CI: 1.06–2.68), and 130 μ l (log-rank $P = 0.001$; HR: 1.69, 95% CI: 1.10–2.60)

ACS, acute coronary syndrome; AF, atrial fibrillation; CAD, coronary artery disease; CBA, cryoballoon ablation; FAI, fat attenuation index; HF, heart failure; HRP, high-risk coronary plaques; PCAT, pericoronary adipose tissue; RCA, right coronary artery; T2DM, diabetes mellitus type 2; TAVR, transcatheter aortic valve replacement.

Future perspectives: radiomics of pericoronary adipose tissue

Artificial intelligence and radiomics represent powerful advancement tools in various fields of cardiovascular imaging.^{111–115} Radiomics-derived additive information can be obtained by available pictures without the need for additional radiation exposure, as radiomics consists of extracting data from images via high-throughput calculations creating enormous information with hundreds of parameters that analyse in a quantitative way the findings in these images.¹¹⁶ Radiomics also represents the new frontiers of cardiac CT; it can be applied to better characterize coronary plaques giving an upper-level evaluation, recognizing plaque attenuation pattern schemes, histogram-based measurements of low attenuation and average HU of the cross-sections.¹¹⁷ Radiomics may play a role in exploring the relationship of atherosclerotic plaques with pericoronary inflammation. Recent studies found that texture and geometry-based radiomic parameters of PCAT may distinguish patients who have a MI, providing new information that was not captured by PCAT attenuation alone.^{118–120} The CCTA-based radiomics phenotype of PCAT outperforms the pFAI model in discriminating acute MI from unstable angina. It is expected that the combination of PCAT radiomics and pFAI evaluation could further enhance the identification of patients at risk of MI.

These findings are of utmost importance and radiomics may become the next tool to detect image biomarkers, advantaging evaluation of risk stratification and targeting patients' care more precisely. So far, radiomics has been used in the research setting but has had limited access into clinical practice, as quantification currently requires

complex manual delineation and highly experienced personnel.

Until now, as revealed by the recent review by Ponsiglione *et al.*,¹²¹ the radiomics quality score for cardiac MRI and CT needs to be improved. A more standardized methodology in the radiomics workflow is needed, and the expanding use of artificial intelligence based evaluation algorithms may allow a rapid and reader-independent assessment. Further studies validating the workflow and the clinical correlations are warranted in order to translate the results into clinical applications and patients' management.

Conclusion

Abundant and dysfunctional EAT and PCAT play a relevant pro-inflammatory role and influence CAD progression. PCAT attenuation and high-risk plaque features are not only promising markers of CAD-related risk but express interconnected pathophysiologic mechanisms. CCTA offers the possibility to study in one fell swoop CAD, stenosis degree, plaque characteristics, functional relevance of the plaque, inducible myocardial ischemia, EAT volume and PCAT attenuation. However, the clinical framing of PCAT is far from being defined, and numerous aspects still need to be clarified, not least the technical aspects of quantification. On the contrary, CFR assessed by using PET provides important prognostic information in patients with or without known CAD. This nuclear technique has proven to be a crucial role in detecting PCAT inflammation in patients with coronary atherosclerosis, although with the limitation of a generic poor availability.

Even if further evidence is needed, anti-inflammatory therapy directed at atherosclerosis may use these noninvasive imaging markers to monitor the effect of treatment and residual disease activity.

Acknowledgements

Conflicts of interest

There are no conflicts of interest.

References

- Hoffmann U, Moselewski F, Cury RC, et al. Predictive value of 16-slice multidetector spiral computed tomography to detect significant obstructive coronary artery disease in patients at high risk for coronary artery disease: patient-versus segment-based analysis. *Circulation* 2004; **110**:2638–2643.
- Brunetti ND, Centola A, Campanale EG, et al. A worrisome 'normal' ECG: implementation of multislice coronary CT scan in an integrated approach to ST-elevation suspected as not associated with acute coronary syndrome. *J Cardiovasc Med (Hagerstown)* 2011; **12**:516–517.
- Maffei E, Seitun S, Martini C, et al. CT coronary angiography and exercise ECG in a population with chest pain and low-to-intermediate pretest likelihood of coronary artery disease. *Heart* 2010; **96**:1973–1979.
- Guaricci AI, Maffei E, Brunetti ND, et al. Heart rate control with oral ivabradine in computed tomography coronary angiography: a randomized comparison of 7.5 mg vs 5 mg regimen. *Int J Cardiol* 2013; **168**:362–368.
- Maffei E, Seitun S, Martini C, et al. Prognostic value of computed tomography coronary angiography in patients with chest pain of suspected cardiac origin. *Radiol Med* 2011; **116**:690–705.
- Benz DC, Fuchs TA, Gräni C, et al. Head-to-head comparison of adaptive statistical and model-based iterative reconstruction algorithms for submillisievert coronary CT angiography. *Eur Heart J Cardiovasc Imaging* 2018; **19**:193–198.
- Jia CF, Zhong J, Meng XY, et al. Image quality and diagnostic value of ultra low-voltage, ultra low-contrast coronary CT angiography. *Eur Radiol* 2019; **29**:3678–3685.
- Pontone G, Muscogiuri G, Andreini D, et al. Impact of a new adaptive statistical iterative reconstruction (ASIR)-V algorithm on image quality in coronary computed tomography angiography. *Acad Radiol* 2018; **25**:1305–1313.
- Knuuti J, Wijns W, Saraste A, et al. 2019 ESC Guidelines for the diagnosis and management of chronic coronary syndromes. *Eur Heart J* 2020; **41**:407–477.
- Carrabba N, Pontone G, Andreini D, et al. Appropriateness criteria for the use of cardiac computed tomography, SIC-SIRM part 2: acute chest pain evaluation; stent and coronary artery bypass graft patency evaluation; planning of coronary revascularization and transcatheter valve procedures; cardiomyopathies, electrophysiological applications, cardiac masses, cardio-oncology and pericardial diseases evaluation. *J Cardiovasc Med (Hagerstown)* 2022; **23**:290–303.
- Esposito A, Francone M, Andreini D, et al. SIRM-SIC appropriateness criteria for the use of Cardiac Computed Tomography. Part 1: Congenital heart diseases, primary prevention, risk assessment before surgery, suspected CAD in symptomatic patients, plaque and epicardial adipose tissue characterization, and functional assessment of stenosis. *Radiol Med* 2021; **126**:1236–1248.
- Motoyama S, Ito H, Sarai M, et al. Plaque characterization by coronary computed tomography angiography and the likelihood of acute coronary events in mid-term follow-up. *J Am Coll Cardiol* 2015; **66**:337–346.
- Williams MC, Moss AJ, Dweck M, et al. Coronary artery plaque characteristics associated with adverse outcomes in the SCOT-HEART Study. *J Am Coll Cardiol* 2019; **73**:291–301.
- Pergola V, Cabrelle G, Mattesi G, et al. Added value of CCTA-derived features to predict MACe in stable patients undergoing coronary computed tomography. *Diagnostics (Basel)* 2022; **12**:1446.
- Pontone G, Guaricci AI, Palmer SC, et al. Diagnostic performance of noninvasive imaging for stable coronary artery disease: a meta-analysis. *Int J Cardiol* 2020; **300**:276–281.
- Baggiano A, Fusini L, Del Torto A, et al. Sequential strategy including FFR (CT) Plus Stress-CTP impacts on management of patients with stable chest pain: the Stress-CTP RIPCORD Study. *J Clin Med* 2020; **9**:2147.
- Yang J, Dou G, He B, et al. Stress myocardial blood flow ratio by dynamic CT perfusion identifies hemodynamically significant CAD. *JACC Cardiovasc Imaging* 2020; **13**:966–976.
- Pontone G, Andreini D, Guaricci AI, et al. Quantitative vs. qualitative evaluation of static stress computed tomography perfusion to detect haemodynamically significant coronary artery disease. *Eur Heart J Cardiovasc Imaging* 2018; **19**:1244–1252.
- Oikonomou EK, Desai MY, Marwan M, et al. Perivascular fat attenuation index stratifies cardiac risk associated with high-risk plaques in the CRISP-CT Study. *J Am Coll Cardiol* 2020; **76**:755–757.
- Tamarappoo B, Dey D, Shmilovich H, et al. Increased pericardial fat volume measured from noncontrast CT predicts myocardial ischemia by SPECT. *JACC Cardiovasc Imaging* 2010; **3**:1104–1112.
- Oikonomou EK, Marwan M, Desai MY, et al. Noninvasive detection of coronary inflammation using computed tomography and prediction of residual cardiovascular risk (the CRISP CT study): a posthoc analysis of prospective outcome data. *Lancet* 2018; **392**:929–939.
- Caselli C, Rovai D, Lorenzoni V, et al. A new integrated clinical-biohumoral model to predict functionally significant coronary artery disease in patients with chronic chest pain. *Can J Cardiol* 2015; **31**:709–716.
- Assante R, Acampa W, Zampella E, et al. Prognostic value of atherosclerotic burden and coronary vascular function in patients with suspected coronary artery disease. *Eur J Nucl Med Mol Imaging* 2017; **44**:2290–2298.
- Taqeti VR, Hachamovitch R, Murthy VL, et al. Global coronary flow reserve is associated with adverse cardiovascular events independently of luminal angiographic severity and modifies the effect of early revascularization. *Circulation* 2015; **131**:19–27.
- Kwiecinski J, Dey D, Cadet S, et al. Peri-coronary adipose tissue density is associated with (18)F-sodium fluoride coronary uptake in stable patients with high-risk plaques. *JACC Cardiovasc Imaging* 2019; **12**:2000–2010.
- Kwon H, Kim D, Kim JS. Body fat distribution and the risk of incident metabolic syndrome: a longitudinal cohort study. *Sci Rep* 2017; **7**:10955.
- Marchington JM, Mattacks CA, Pond CM. Adipose tissue in the mammalian heart and pericardium: structure, foetal development and biochemical properties. *Comp Biochem Physiol B* 1989; **94**:225–232.
- Corradi D, Maestri R, Callegari S, et al. The ventricular epicardial fat is related to the myocardial mass in normal, ischemic and hypertrophic hearts. *Cardiovasc Pathol* 2004; **13**:313–316.
- Iacobellis G, Ribaudo MC, Zappaterreno A, Iannucci CV, Leonetti F. Relation between epicardial adipose tissue and left ventricular mass. *Am J Cardiol* 2004; **94**:1084–1087.
- Iacobellis G, Corradi D, Sharma AM. Epicardial adipose tissue: anatomic, biomolecular and clinical relationships with the heart. *Nat Clin Pract Cardiovasc Med* 2005; **2**:536–543.
- Mancio J, Azevedo D, Saraiva F, et al. Epicardial adipose tissue volume assessed by computed tomography and coronary artery disease: a systematic review and meta-analysis. *Eur Heart J Cardiovasc Imaging* 2018; **19**:490–497.
- Shirani J, Berezowski K, Roberts WC. Quantitative measurement of normal and excessive (cor adiposum) subepicardial adipose tissue, its clinical significance, and its effect on electrocardiographic QRS voltage. *Am J Cardiol* 1995; **76**:414–418.
- Mazurek T, Zhang L, Zalewski A, et al. Human epicardial adipose tissue is a source of inflammatory mediators. *Circulation* 2003; **108**:2460–2466.
- Iacobellis G, Pistilli D, Gucciardo M, et al. Adiponectin expression in human epicardial adipose tissue in vivo is lower in patients with coronary artery disease. *Cytokine* 2005; **29**:251–255.
- Parisi V, Rengo G, Perrone-Filardi P, et al. Increased epicardial adipose tissue volume correlates with cardiac sympathetic denervation in patients with heart failure. *Circ Res* 2016; **118**:1244–1253.
- Rajani R, Shmilovich H, Nakazato R, et al. Relationship of epicardial fat volume to coronary plaque, severe coronary stenosis, and high-risk coronary plaque features assessed by coronary CT angiography. *J Cardiovasc Comput Tomogr* 2013; **7**:125–132.
- Bo X, Ma L, Fan J, et al. Epicardial fat volume is correlated with coronary lesion and its severity. *Int J Clin Exp Med* 2015; **8**:4328–4334.
- Zhou J, Chen Y, Zhang Y, et al. Epicardial fat volume improves the prediction of obstructive coronary artery disease above traditional risk factors and coronary calcium score. *Circ Cardiovasc Imaging* 2019; **12**:e008002.
- Hassan M, Said K, Rizk H, et al. Segmental peri-coronary epicardial adipose tissue volume and coronary plaque characteristics. *Eur Heart J Cardiovasc Imaging* 2016; **17**:1169–1177.
- Antonopoulos AS, Sanna F, Sabharwal N, et al. Detecting human coronary inflammation by imaging perivascular fat. *Sci Transl Med* 2017; **9**:eaal2658.
- Goeller M, Rahman Ihdahid A, Cadet S, et al. Pericoronary adipose tissue and quantitative global noncalcified plaque characteristics from CT angiography do not differ in matched South Asian, East Asian and European-origin Caucasian patients with stable chest pain. *Eur J Radiol* 2020; **125**:108874.

- 42 Zampella E, Acampa W, Assante R, *et al.* Combined evaluation of regional coronary artery calcium and myocardial perfusion by (82)Rb PET/CT in the identification of obstructive coronary artery disease. *Eur J Nucl Med Mol Imaging* 2018; **45**:521–529.
- 43 Acampa W, Assante R, Mannarino T, *et al.* Low-dose dynamic myocardial perfusion imaging by CZT-SPECT in the identification of obstructive coronary artery disease. *Eur J Nucl Med Mol Imaging* 2020; **47**:1705–1712.
- 44 Maaniitty T, Stenström I, Bax JJ, *et al.* Prognostic value of coronary CT angiography with selective PET perfusion imaging in coronary artery disease. *JACC Cardiovasc Imaging* 2017; **10**:1361–1370.
- 45 Zampella E, Acampa W, Assante R, *et al.* Combined evaluation of regional coronary artery calcium and myocardial perfusion by (82)Rb PET/CT in predicting lesion-related outcome. *Eur J Nucl Med Mol Imaging* 2020; **47**:1698–1704.
- 46 Nomura CH, Assuncao-Jr AN, Guimarães PO, *et al.* Association between perivascular inflammation and downstream myocardial perfusion in patients with suspected coronary artery disease. *Eur Heart J Cardiovasc Imaging* 2020; **21**:599–605.
- 47 Libby P. Inflammation during the life cycle of the atherosclerotic plaque. *Cardiovasc Res* 2021; **117**:2525–2536.
- 48 Guaricci AI, Pontone G, Fusini L, *et al.* Additional value of inflammatory biomarkers and carotid artery disease in prediction of significant coronary artery disease as assessed by coronary computed tomography angiography. *Eur Heart J Cardiovasc Imaging* 2017; **18**:1049–1056.
- 49 Conte E, Andreini D, Magnoni M, *et al.* Association of high-risk coronary atherosclerosis at CCTA with clinical and circulating biomarkers: insight from CAPIRE study. *J Cardiovasc Comput Tomogr* 2021; **15**:73–80.
- 50 Guaricci AI, Arcadi T, Brunetti ND, *et al.* Carotid intima media thickness and coronary atherosclerosis linkage in symptomatic intermediate risk patients evaluated by coronary computed tomography angiography. *Int J Cardiol* 2014; **176**:988–993.
- 51 Caselli C, De Graaf MA, Lorenzoni V, *et al.* HDL cholesterol, leptin and interleukin-6 predict high risk coronary anatomy assessed by CT angiography in patients with stable chest pain. *Atherosclerosis* 2015; **241**:55–61.
- 52 Andreini D, Melotti E, Vavassori C, *et al.* Whole-blood transcriptional profiles enable early prediction of the presence of coronary atherosclerosis and high-risk plaque features at coronary CT angiography. *Biomedicines* 2022; **10**:1309.
- 53 Held C, White HD, Stewart RAH, *et al.* Inflammatory biomarkers interleukin-6 and C-reactive protein and outcomes in stable coronary heart disease: experiences from the STABILITY (Stabilization of Atherosclerotic Plaque by Initiation of Darapladib Therapy) Trial. *J Am Heart Assoc* 2017; **6**:e005077.
- 54 Zebrack JS, Anderson JL, Maycock CA, Horne BD, Bair TL, Muhlestein JB. Usefulness of high-sensitivity C-reactive protein in predicting long-term risk of death or acute myocardial infarction in patients with unstable or stable angina pectoris or acute myocardial infarction. *Am J Cardiol* 2002; **89**:145–149.
- 55 Neglia DAA, Lorenzoni V, Caselli C, Gimelli A. Triglyceride-glucose index predicts outcome in patients with chronic coronary syndrome independently of other risk factors and myocardial ischaemia. *EHJ Open* 2021; **1**:oeab004.
- 56 Lin A, Nerlekar N, Yuvaraj J, *et al.* Pericoronary adipose tissue computed tomography attenuation distinguishes different stages of coronary artery disease: a cross-sectional study. *Eur Heart J Cardiovasc Imaging* 2021; **22**:298–306.
- 57 Tarkin JM, Joshi FR, Evans NR, *et al.* Detection of atherosclerotic inflammation by (68)Ga-DOTATATE PET compared to [(18)F]FDG PET imaging. *J Am Coll Cardiol* 2017; **69**:1774–1791.
- 58 Mazurek T, Kobylecka M, Zielenkiewicz M, *et al.* PET/CT evaluation of (18)F-FDG uptake in pericoronary adipose tissue in patients with stable coronary artery disease: independent predictor of atherosclerotic lesions' formation? *J Nucl Cardiol* 2017; **24**:1075–1084.
- 59 Ohyama K, Matsumoto Y, Takanami K, *et al.* Coronary adventitial and perivascular adipose tissue inflammation in patients with vasospastic angina. *J Am Coll Cardiol* 2018; **71**:414–425.
- 60 Wall CHY, Le EPV, Čorović A, *et al.* Pericoronary and periaortic adipose tissue density are associated with inflammatory disease activity in Takayasu arteritis and atherosclerosis. *Eur Heart J Open* 2021; **1**:oeab019.
- 61 Conte E, Annoni A, Pontone G, *et al.* Evaluation of coronary plaque characteristics with coronary computed tomography angiography in patients with nonobstructive coronary artery disease: a long-term follow-up study. *Eur Heart J Cardiovasc Imaging* 2017; **18**:1170–1178.
- 62 Williams MC, Kwiecinski J, Doris M, *et al.* Low-attenuation noncalcified plaque on coronary computed tomography angiography predicts myocardial infarction: results from the multicenter SCOT-HEART Trial (Scottish Computed Tomography of the HEART). *Circulation* 2020; **141**:1452–1462.
- 63 Guglielmo M, Lin A, Dey D, *et al.* Epicardial fat and coronary artery disease: role of cardiac imaging. *Atherosclerosis* 2021; **321**:30–38.
- 64 Tzolos E, Williams MC, McElhinney P, *et al.* Pericoronary adipose tissue attenuation, low-attenuation plaque burden, and 5-year risk of myocardial infarction. *JACC Cardiovasc Imaging* 2022; **15**:1078–1088.
- 65 Goeller M, Tamarappoo BK, Kwan AC, *et al.* Relationship between changes in pericoronary adipose tissue attenuation and coronary plaque burden quantified from coronary computed tomography angiography. *Eur Heart J Cardiovasc Imaging* 2019; **20**:636–643.
- 66 Nakajima A, Sugiyama T, Araki M, *et al.* Plaque rupture, compared with plaque erosion, is associated with a higher level of pancoronary inflammation. *JACC Cardiovasc Imaging* 2022; **15**:828–839.
- 67 Joshi NV, Vesey AT, Williams MC, *et al.* 18F-fluoride positron emission tomography for identification of ruptured and high-risk coronary atherosclerotic plaques: a prospective clinical trial. *Lancet* 2014; **383**:705–713.
- 68 Neumann FJ, Sousa-Uva M, Ahlsson A, *et al.* 2018 ESC/EACTS Guidelines on myocardial revascularization. *Eur Heart J* 2019; **40**:87–165.
- 69 Gaibazzi N, Porter T, Lorenzoni V, *et al.* Effect of coronary revascularization on the prognostic value of stress myocardial contrast wall motion and perfusion imaging. *J Am Heart Assoc* 2017; **6**:e006202.
- 70 Gaibazzi N, Tuttolomondo D, Guaricci AI, De Marco F, Pontone G. Stress-echocardiography or coronary computed tomography in suspected chronic coronary syndrome after the 2019 European Guidelines? A practical guide. *J Cardiovasc Med (Hagerstown)* 2021; **23**:12–21.
- 71 Hoshino M, Yang S, Sugiyama T, *et al.* Peri-coronary inflammation is associated with findings on coronary computed tomography angiography and fractional flow reserve. *J Cardiovasc Comput Tomogr* 2020; **14**:483–489.
- 72 Norgaard BL, Leipsic J, Gaur S, *et al.* Diagnostic performance of noninvasive fractional flow reserve derived from coronary computed tomography angiography in suspected coronary artery disease: the NXT trial (Analysis of Coronary Blood Flow Using CT Angiography: Next Steps). *J Am Coll Cardiol* 2014; **63**:1145–1155.
- 73 Fairbairn TA, Nieman K, Akasaka T, *et al.* Real-world clinical utility and impact on clinical decision-making of coronary computed tomography angiography-derived fractional flow reserve: lessons from the ADVANCE Registry. *Eur Heart J* 2018; **39**:3701–3711.
- 74 Hlatky MA, De Bruyne B, Pontone G, *et al.* Quality-of-life and economic outcomes of assessing fractional flow reserve with computed tomography angiography: PLATFORM. *J Am Coll Cardiol* 2015; **66**:2315–2323.
- 75 Yu M, Dai X, Deng J, Lu Z, Shen C, Zhang J. Diagnostic performance of perivascular fat attenuation index to predict hemodynamic significance of coronary stenosis: a preliminary coronary computed tomography angiography study. *Eur Radiol* 2020; **30**:673–681.
- 76 Duncker HAS, Moshage M, Dey D, *et al.* Computed tomography-derived characterization of pericoronary, epicardial, and paracardial adipose tissue and its association with myocardial ischemia as assessed by computed fractional flow reserve. *J Thorac Imaging* 2021; **38**:46–53.
- 77 Assante R, Acampa W, Zampella E, *et al.* Coronary atherosclerotic burden vs. coronary vascular function in diabetic and nondiabetic patients with normal myocardial perfusion: a propensity score analysis. *Eur J Nucl Med Mol Imaging* 2017; **44**:1129–1135.
- 78 Gaudieri V, Acampa W, Rozza F, *et al.* Coronary vascular function in patients with resistant hypertension and normal myocardial perfusion: a propensity score analysis. *Eur Heart J Cardiovasc Imaging* 2019; **20**:949–958.
- 79 Assante R, Mainolfi CG, Zampella E, *et al.* Relation between myocardial blood flow and cardiac events in diabetic patients with suspected coronary artery disease and normal myocardial perfusion imaging. *J Nucl Cardiol* 2021; **28**:1222–1233.
- 80 Bucci M, Joutsiniemi E, Saraste A, *et al.* Intrapericardial, but not extrapericardial, fat is an independent predictor of impaired hyperemic coronary perfusion in coronary artery disease. *Arterioscler Thromb Vasc Biol* 2011; **31**:211–218.
- 81 Nappi C, Ponsiglione A, Acampa W, *et al.* Relationship between epicardial adipose tissue and coronary vascular function in patients with suspected coronary artery disease and normal myocardial perfusion imaging. *Eur Heart J Cardiovasc Imaging* 2019; **20**:1379–1387.
- 82 Raposeiras-Roubin S, Rosselló X, Oliva B, *et al.* Triglycerides and residual atherosclerotic risk. *J Am Coll Cardiol* 2021; **77**:3031–3041.

- 83 Peng X, Wu H. Inflammatory links between hypertriglyceridemia and atherogenesis. *Curr Atheroscler Rep* 2022; **24**:297–306.
- 84 Antoniadou C, Antonopoulos AS, Deanfield J. Imaging residual inflammatory cardiovascular risk. *Eur Heart J* 2020; **41**:748–758.
- 85 Goeller M, Achenbach S, Cadet S, et al. Pericoronary adipose tissue computed tomography attenuation and high-risk plaque characteristics in acute coronary syndrome compared with stable coronary artery disease. *JAMA Cardiol* 2018; **3**:858–863.
- 86 van Diemen PA, Bom MJ, Driessen RS, et al. Prognostic value of RCA pericoronary adipose tissue CT-attenuation beyond high-risk plaques, plaque volume, and ischemia. *JACC Cardiovasc Imaging* 2021; **14**:1598–1610.
- 87 Ichikawa K, Miyoshi T, Ohno Y, et al. Association between high pericoronary adipose tissue computed tomography attenuation and impaired flow-mediated dilation of the brachial artery. *J Atheroscler Thromb* 2022; [Online ahead of print].
- 88 Yeboah J, Folsom AR, Burke GL, et al. Predictive value of brachial flow-mediated dilation for incident cardiovascular events in a population-based study: the multiethnic study of atherosclerosis. *Circulation* 2009; **120**:502–509.
- 89 Brainin P, Frestad D, Prescott E. The prognostic value of coronary endothelial and microvascular dysfunction in subjects with normal or nonobstructive coronary artery disease: a systematic review and meta-analysis. *Int J Cardiol* 2018; **254**:1–9.
- 90 Nogami K, Sugiyama T, Kanaji Y, et al. Association between pericoronary adipose tissue attenuation and outcome after second-generation cryoballoon ablation for atrial fibrillation. *Br J Radiol* 2021; **94**:20210361.
- 91 Ichikawa K, Miyoshi T, Osawa K, et al. High pericoronary adipose tissue attenuation on computed tomography angiography predicts cardiovascular events in patients with type 2 diabetes mellitus: posthoc analysis from a prospective cohort study. *Cardiovasc Diabetol* 2022; **21**:44.
- 92 Yokoyama I, Momomura S, Ohtake T, et al. Reduced myocardial flow reserve in noninsulin-dependent diabetes mellitus. *J Am Coll Cardiol* 1997; **30**:1472–1477.
- 93 Kelshiker MA, Seligman H, Howard JP, et al. Coronary flow reserve and cardiovascular outcomes: a systematic review and meta-analysis. *Eur Heart J* 2022; **43**:1582–1593.
- 94 Recio-Mayoral A, Mason JC, Kaski JC, Rubens MB, Harari OA, Camici PG. Chronic inflammation and coronary microvascular dysfunction in patients without risk factors for coronary artery disease. *Eur Heart J* 2009; **30**:1837–1843.
- 95 Lontchi-Yimagou E, Sobngwi E, Matsha TE, Kengne AP. Diabetes mellitus and inflammation. *Curr Diab Rep* 2013; **13**:435–444.
- 96 Tweet MS, Akhtar NJ, Hayes SN, Best PJ, Gulati R, Araoz PA. Spontaneous coronary artery dissection: acute findings on coronary computed tomography angiography. *Eur Heart J Acute Cardiovasc Care* 2019; **8**:467–475.
- 97 Hedgire S, Baliyan V, Zucker EJ, et al. Perivascular epicardial fat stranding at coronary CT angiography: a marker of acute plaque rupture and spontaneous coronary artery dissection. *Radiology* 2018; **287**:808–815.
- 98 Pitliya A, Datta S, Kalayci A, et al. Eosinophilic inflammation in spontaneous coronary artery dissection: a potential therapeutic target? *Med Hypotheses* 2018; **121**:91–94.
- 99 Yuvaraj J, Lin A, Nerlekar N, et al. Is spontaneous coronary artery dissection (SCAD) related to vascular inflammation and epicardial fat? Insights from computed tomography coronary angiography. *Cardiovasc Diagn Ther* 2020; **10**:239–241.
- 100 Bittner DO, Goeller M, Dey D, Zopf Y, Achenbach S, Marwan M. High levels of eicosapentaenoic acid are associated with lower pericoronary adipose tissue attenuation as measured by coronary CTA. *Atherosclerosis* 2021; **316**:73–78.
- 101 Raeesi T, Mozaffari H, Sepehri N, et al. The negative impact of obesity on the occurrence and prognosis of the 2019 novel coronavirus (COVID-19) disease: a systematic review and meta-analysis. *Eat Weight Disord* 2022; **27**:893–911.
- 102 Yang Y, Wang L, Liu J, Fu S, Zhou L, Wang Y. Obesity or increased body mass index and the risk of severe outcomes in patients with COVID-19: a protocol for systematic review and meta-analysis. *Medicine (Baltimore)* 2022; **101**:e28499.
- 103 Favre G, Legueult K, Pradier C, et al. Visceral fat is associated to the severity of COVID-19. *Metabolism* 2021; **115**:154440.
- 104 Liu K, Wang X, Song G. Association of epicardial adipose tissue with the severity and adverse clinical outcomes of COVID-19: a meta-analysis. *Int J Infect Dis* 2022; **120**:33–40.
- 105 Pontone G, Scafuri S, Mancini ME, et al. Role of computed tomography in COVID-19. *J Cardiovasc Comput Tomogr* 2021; **15**:27–36.
- 106 Marcucci M, Fogante M, Tagliati C, Papiri G. Cut-off point of CT-assessed epicardial adipose tissue volume for predicting worse clinical burden of SARS-CoV-2 pneumonia. *Emerg Radiol* 2022; **29**:645–653.
- 107 Muzurović EM, Vujošević S, Mikhailidis DP. Can we decrease epicardial and pericardial fat in patients with diabetes? *J Cardiovasc Pharmacol Ther* 2021; **26**:415–436.
- 108 Turker Duyuler P, Duyuler S, Demirtaş B, Çayhan V. Epicardial and pericoronary adipose tissue in severe COVID-19 infection. *Acta Cardiol* 2021; **6**:1–8.
- 109 Shivshankar P, Karmouty-Quintana H, Mills T, et al. SARS-CoV-2 infection: host response, immunity, and therapeutic targets. *Inflammation* 2022; **45**:1430–1449.
- 110 Eberhard M, Stocker D, Meyer M, et al. Epicardial adipose tissue volume is associated with adverse outcomes after transcatheter aortic valve replacement. *Int J Cardiol* 2019; **286**:29–35.
- 111 Muscogiuri G, Chiesa M, Baggiano A, et al. Diagnostic performance of deep learning algorithm for analysis of computed tomography myocardial perfusion. *Eur J Nucl Med Mol Imaging* 2022; **49**:3119–3128.
- 112 Muscogiuri G, Chiesa M, Trotta M, et al. Performance of a deep learning algorithm for the evaluation of CAD-RADS classification with CCTA. *Atherosclerosis* 2020; **294**:25–32.
- 113 Argentiero A, Muscogiuri G, Rabbat MG, et al. The applications of artificial intelligence in cardiovascular magnetic resonance: a comprehensive review. *J Clin Med* 2022; **11**:2866.
- 114 Penso M, Moccia S, Scafuri S, et al. Automated left and right ventricular chamber segmentation in cardiac magnetic resonance images using dense fully convolutional neural network. *Comput Methods Programs Biomed* 2021; **204**:106059.
- 115 Oikonomou EK, Williams MC, Kotanidis CP, et al. A novel machine learning-derived radiotranscriptomic signature of perivascular fat improves cardiac risk prediction using coronary CT angiography. *Eur Heart J* 2019; **40**:3529–3543.
- 116 Kumar V, Gu Y, Basu S, et al. Radiomics: the process and the challenges. *Magn Reson Imaging* 2012; **30**:1234–1248.
- 117 Kolossváry M, Karády J, Kikuchi Y, et al. Radiomics versus visual and histogram-based assessment to identify atheromatous lesions at coronary CT angiography: an ex vivo study. *Radiology* 2019; **293**:89–96.
- 118 Lin A, Kolossváry M, Yuvaraj J, et al. Myocardial infarction associates with a distinct pericoronary adipose tissue radiomic phenotype: a prospective case-control study. *JACC Cardiovasc Imaging* 2020; **13**:2371–2383.
- 119 Mahabadi AA, Rassaf T. Radiomic assessment of pericoronary adipose tissue: detecting the vulnerable patient. *JACC Cardiovasc Imaging* 2020; **13**:2384–2385.
- 120 Si N, Shi K, Li N, et al. Identification of patients with acute myocardial infarction based on coronary CT angiography: the value of pericoronary adipose tissue radiomics. *Eur Radiol* 2022; **32**:6868–6877.
- 121 Ponsiglione A, Stanzione A, Cuocolo R, et al. Cardiac CT and MRI radiomics: systematic review of the literature and radiomics quality score assessment. *Eur Radiol* 2022; **32**:2629–2638.