

Choroidal Vasculature Index Fluctuations in Epiretinal Membranes in Vitreoretinal Surgery: Comparison Between Idiopathic and Diabetic Ones

Rossella D'Aloisio¹, Maria Ludovica Ruggeri¹, Annamaria Porreca², Marta Di Nicola², Agbéanda Aharrh-Gnama¹, Alberto Quarta¹, Matteo Gironi¹, Lisa Toto¹, and Rodolfo Mastropasqua¹

¹ Ophthalmology Clinic, Department of Medicine and Science of Ageing, University G. D'Annunzio Chieti- Pescara, Chieti, Italy

² Department of Medical, Oral and Biotechnological Sciences, Laboratory of Biostatistics, University "G. d'Annunzio" Chieti-Pescara, Chieti, Italy

Correspondence: Rossella D'Aloisio, Department of Medicine and Science of Ageing, University G. D'Annunzio Chieti-Pescara, Via dei Vestini, 31, Chieti 66100, Italy. e-mail: ross.daloisio@gmail.com

Received: August 26, 2023

Accepted: October 29, 2023

Published: December 7, 2023

Keywords: idiopathic epiretinal membrane; diabetic epiretinal membrane; choroidal vasculature index; vitrectomy

Citation: D'Aloisio R, Ruggeri ML, Porreca A, Di Nicola M, Aharrh-Gnama A, Quarta A, Gironi M, Toto L, Mastropasqua R. Choroidal vasculature index fluctuations in epiretinal membranes in vitreoretinal surgery: Comparison between idiopathic and diabetic ones. *Transl Vis Sci Technol.* 2023;12(12):9, <https://doi.org/10.1167/tvst.12.12.9>

Purpose: The aim of the study was to analyze choroidal vasculature index (CVI) fluctuations in patients with epiretinal membrane after vitreoretinal surgery, comparing idiopathic and secondary diabetic ones.

Methods: Thirty eyes suffering from idiopathic ERMs (I-ERMS; $n = 15$) and diabetic ERMs (D-ERMS; $n = 15$) were analyzed in this observational prospective study. Anatomical (central macular thickness) and functional (best-corrected visual acuity) parameters were analyzed preoperatively and at 1 and 3 months after vitrectomy. Perfusion findings regarding CVI and luminal area were also calculated.

Results: At 1 month after surgery, the luminal area and CVI significantly decreased in the I-ERMS group, whereas they were increased in the D-ERMS group. At the 3-month follow-up, the CVI tended to return to baseline values in I-ERMS and to reduce in D-ERMS, but without any statistical differences.

Conclusions: The significant change in the CVI after surgery seems to imply that the choroidal layer is affected by vitreomacular disease and can become a novel potential biomarker of predictiveness in vitreoretinal surgery.

Translational Relevance: The aim of the study was to focus on the early choroidal changes to better understand initial predictive elements of long-term functional postoperative outcomes.

Introduction

Epiretinal membrane (ERM) is a disease that affects the vitreoretinal interface characterized by progressive vision loss and metamorphopsia. First described by Ivanoff in 1865, it entails the growth of a pathologic layer on the vitreoretinal inner surface.^{1,2} Although the pathogenesis remains unclear, a role seems to

be covered by posterior vitreous detachment causing migration and proliferation of retinal glial cells, as well as by hyalocytes deriving from cortical vitreous remnants.^{3,4} ERMs are mainly divided into two different groups: primary (idiopathic) or secondary ERMs.⁵

Studies have depicted idiopathic ERMs (I-ERMS) and diabetic ERMs (D-ERMS) to be different in pathophysiology, characteristics and response to treatment.⁶

I-ERMS in 95% of cases result from posterior vitreous detachment causing cell proliferation at the vitreoretinal interface. Different mechanisms have been reported as responsible for secondary ERMs formation, particularly the result of inflammatory and vascular processes as well as a consequence of different existing ocular conditions, including vitreoretinal surgery, ocular trauma, retinal tears, uveitis, argon laser photocoagulation, cryotherapy, retinal vasculitis, retinal detachment, diabetes mellitus, and proliferative vitreoretinopathy.⁷⁻¹⁰

ERMs can also characterize the most severe stage of proliferative diabetic retinopathy owing to ERM contraction causing retinal traction or tractional retinal detachment.¹¹ Indeed, proliferative diabetic retinopathy seems responsible for glial cell proliferation, which is significantly involved in ERMs development.^{12,13}

The introduction of optical coherence tomography (OCT) in routine clinical practice has permitted a better comprehension and identification of ERMs, thus becoming the gold standard for ERMs diagnosis and follow-up, with a simultaneous qualitative and quantitative evaluation. Govetto et al., in their work, staged the ERM by observing different parameters on OCT scans and predicting a successful recovery after surgery.¹⁴ Enhanced depth imaging mode on standard structural OCT has given the chance to obtain high resolution images of the choroid of both its two components: connective tissue and blood vessels. Over the years, great importance has been given to the choroid involved in different pathologies affecting the eye, from choroidal neovascularization to central serous chorioretinopathy and uveitis. The choroidal vasculature index (CVI) is a novel parameter recently introduced, able to better identify the vasculature of the choroid.^{15,16}

Some studies have demonstrated that fluctuations in the CVI are connected with different ocular pathologies; thus, it has been proposed as a good indicator of treatment response in choroidal neovascularizations and central serous chorioretinopathy. Compared with choroidal thickness, it has the advantage of not being affected by many biological factors such as diurnal fluctuation, intraocular pressure, refractive error, and axial length, becoming a robust biomarker to monitor choroidal status in several chorioretinal disorders.^{17,18} Moreover, it seems to have more retinal topographical variations if compared with CVI, with thinning toward the peripheral choroid.¹⁹

Currently, the relationship between choroidal changes and ERM remains in debate. Some authors have identified temporary differences in eyes that developed ERMs, or that underwent vitrectomy,^{20,21}

whereas other works reported no significant differences when comparing eyes with ERMs and fellow eyes.²²

The aim of our study was to analyze CVI fluctuations in patients with ERMs after vitreoretinal surgery, comparing I-ERMS with secondary D-ERMS.

Methods

A total of 30 eyes of 30 patients were analyzed in our observational study. Patients older than 18 years old with I-ERMS ($n = 15$) and D-ERMS ($n = 15$) (stage 3 Govetto classification), disturbing metamorphopsia (Amsler grid test positive), best-corrected visual acuity (BCVA) of less than 0.22 logarithm of the minimum angle of resolution, and clear evidence of tractional ERM at the OCT scans were enrolled at the University G. d'Annunzio, Chieti-Pescara, Italy. All enrolled patients had clear indications for vitrectomy and ERM/internal limiting membrane (ILM) peeling and, therefore, were waiting for surgery.

Exclusion criteria were elevated myopia (defined as axial length >26.5 mm, refractive error >-6 diopters), other pathologic ocular conditions including proliferative diabetic retinopathy, vascular retinal disorders, glaucoma, chorioretinal diseases), systemic disorders affecting the eye, previous surgical treatments within 12 months (including intravitreal injections) and pregnancy.

The study adhered to the Declaration of Helsinki, and all patients signed a specific informed consent. The study was approved by our Institutional Review Board, Department of Medicine and Science of Ageing, University G. D'Annunzio Chieti-Pescara.

All enrolled patients were divided into two groups: I-ERM group ($n = 15$), and age-matched eyes with D-ERMS ($n = 15$). I-ERMS was defined as the presence of a fibrocellular membrane proliferating on the inner surface of the retina at the macular area, evidenced at the ophthalmoscopic clinical evaluation and instrumental evaluation (multicolor imaging, autofluorescence, and spectral domain OCT). D-ERMS were defined as ERMs secondary to nonproliferative diabetic retinopathy.

All patients received complete ophthalmologic examination, including BCVA in logarithm of the minimum angle of resolution measurements (BCVA), anterior segment biomicroscopy, indirect fundus examination, intraocular pressure assessment, axial length measurement, multicolor imaging, and spectral domain OCT. All examinations were performed at baseline and at 1 and 3 months after surgery.

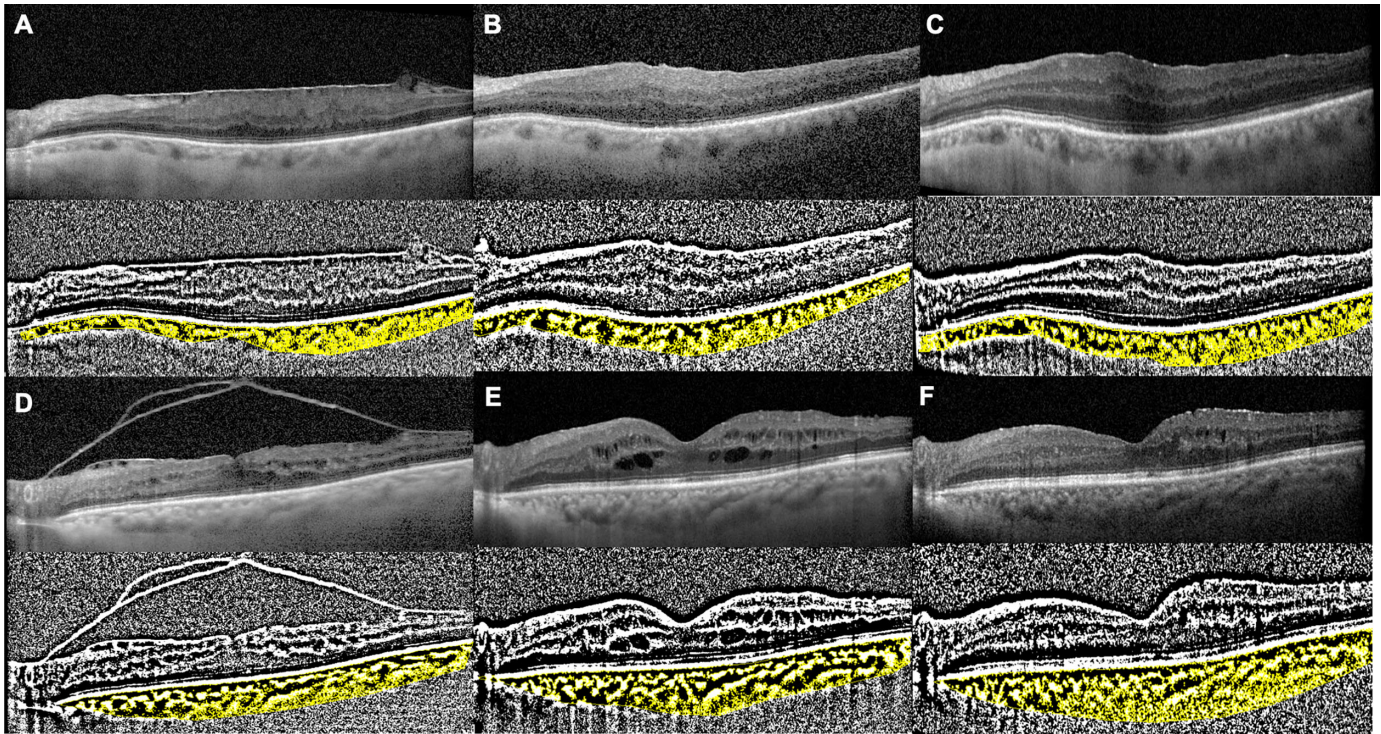


Figure 1. CVI modifications during follow-up after surgery. Patient with the I-ERMS at baseline preoperatively, T0 (A); at 1 month after surgery, T1 (B); and after 3 months postoperatively, T2 (C). Patient with the D-ERMS at baseline preoperatively, T0 (D), at 1 month after surgery, T1 (E), and after 3 months postoperatively, T2 (F).

The choroidal evaluation was performed by obtaining a horizontal single-line scan involving the fovea through SD-OCT imaging (Spectralis OCT, Heidelberg Engineering, Inc, Germany) with enhanced depth imaging mode by two different masked physicians. Images with poor signal strength (<25) were excluded and thus repeated.

CVI parameter was calculated through the application of a validated algorithm as previously described: once identified manually, the choroid, defined as the area between the outer border of the retinal pigment epithelium and the sclera and, therefore, known as the total choroidal area, “Niblack’s Auto Local threshold” was applied, to binarize the obtained images (Image J). Dark pixels were defined as the luminal area (LA), and light pixels were defined as the stromal area. The CVI percentage (%) was then obtained by dividing the LA for total choroidal area (Fig. 1).

Statistical Analysis

Data were collected at baseline (T0), after 1 month (T1), and after 3 months (T2) to determine how the patients improved their conditions. Descriptive statistics included frequencies and proportions for categorical variables and mean \pm standard deviation for

continuous. The Mann–Whitney U test and the χ^2 tests were used to assess baseline differences between groups for continuous and categorical variables, respectively. Differences in the mean values of BCVA, central macular thickness, CCT, LA, total choroidal area, and the CVI in each group over time were assessed by two-way mixed analysis of variance, followed by Tukey’s post hoc test. All statistical tests were two-sided, with a significance level set at $P < 0.05$. Analyses were performed using the R software environment for statistical computing and graphics (version 3.4.1; <http://www.r-project.org/>).

Results

A total of 30 eyes of 30 patients with ERM undergoing vitrectomy and ILM + ERM peeling surgery were enrolled and included in the statistical analysis. Clinical and demographic baseline patient characteristics are summarized in Table.

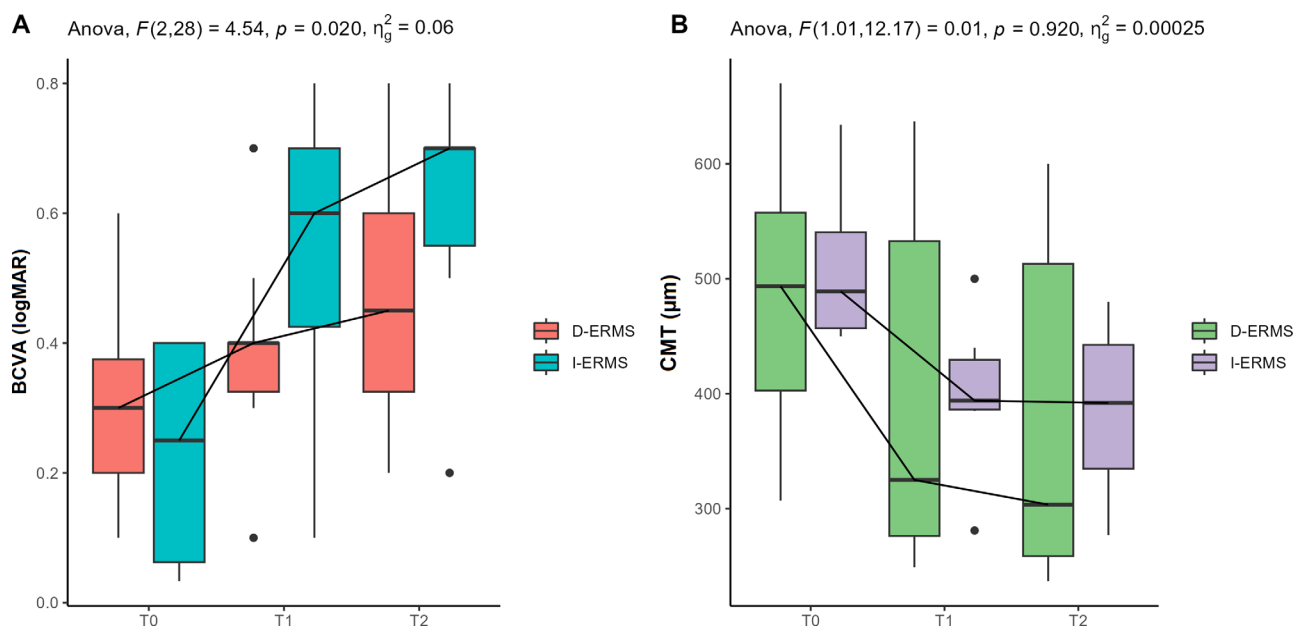
Our findings showed a significant improvement in terms of BCVA in both two groups but with different behavior: in the I-ERMS group, a greater increase in visual acuity was observed, whereas in the D-ERMS

Table. Clinical and Demographic Baseline Patient Characteristics of the Two Groups (D-ERMS and I-ERMS) for Continuous Variables and Absolute Frequency (Column Percentage) for Categorical

Baseline Characteristics	D-ERMS (n = 15)	I-ERMS (n = 15)	P Value
Age, years	72.5 [70.2; 73.0]	61.5 [57.2; 69.5]	0.082
Gender, no. (%)			
Male	72	67	
Female	28	33	
BCVA (logMAR)	0.30 [0.20; 0.38]	0.25 [0.06; 0.40]	0.454
CMT (μm)	494.00 [403.00; 558.00]	489.00 [457.00; 540.00]	0.604
CCT (μm)	214.00 [181.00; 227.00]	200.00 [120.00; 228.00]	0.950
LA (mm^2)	39,300.00 [26,977.00; 46,325.00]	33,054.00 [22,798.00; 47,997.00]	0.952
TCA (mm^2)	59,746.00 [41,350.00; 71,471.00]	51,743.00 [35,417.00; 78,522.00]	0.864
CVI	0.65 [0.64; 0.68]	0.64 [0.61; 0.67]	0.296

CCT, central choroidal thickness; CMT, central macular thickness; logMAR, logarithm of the minimum angle of resolution; TCA, total choroidal area.

Values are median [q1 = first; q3 = third] quartile unless otherwise noted.

**Figure 2.** Box plots for BCVA (A) and central macular thickness, central macular thickness (CMT) (B) into groups (D-ERMS and I-ERMS) report the results of the two-way mixed analysis of variance including F statistics, P value, and effect size.

group, the BCVA increase was lower ($P = 0.020$) (Fig. 2).

Regarding anatomical data, central macular thickness decreased in both groups in a similar manner over time ($P = 0.092$) (Fig. 2).

At 1 month after surgery, the CVI significantly decreased in the I-ERMS group, whereas it increased in the D-ERMS group (Fig. 3D). At the 3-month follow-up, the CVI tended to return to baseline values in I-ERMS and to decrease in D-ERMS, but without any statistical differences (Fig. 3D).

Discussion

Given that the choroid is believed to be the unique responsible oxygen supply for the foveal avascular zone, choroidal circulation changes and inflammation play a key role in the pathogenesis of many ocular and systemic diseases.

Because an increase in choroidal thickness can be caused by both an increase in vasculature and stromal tissues, CVI has become a more reliable

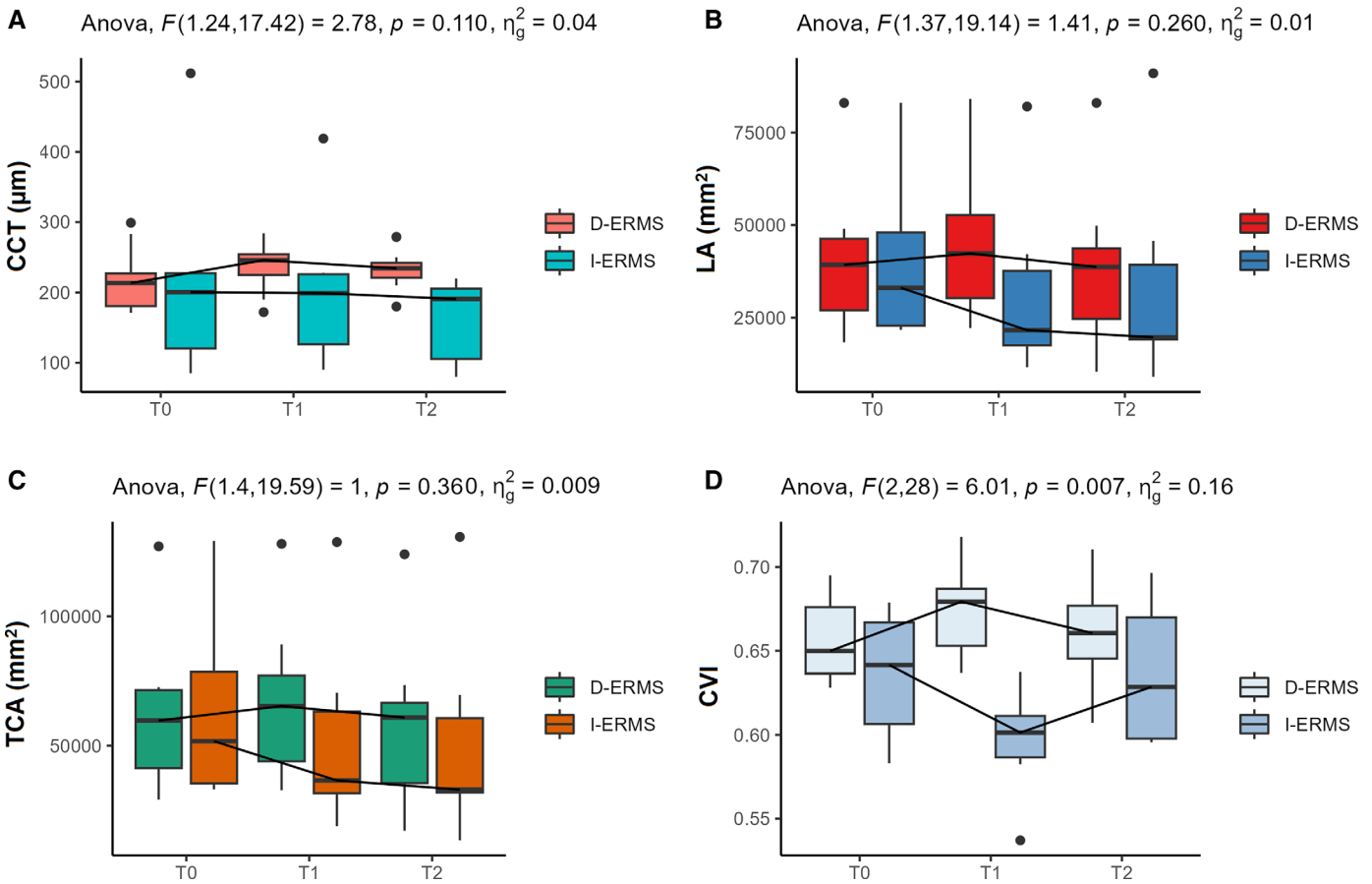


Figure 3. Box plots for CCT (A), LA (B), total choroidal area (TCA) (C), and CVI (D) into groups (D-ERMS and I-ERMS) report the results of the two-way mixed analysis of variance including F statistics, *P* value, and effect size.

biomarker instead of choroidal thickness, which previously showed high variability in various clinical studies.^{16–18}

Indeed, the CVI has been widely studied in healthy eyes and several eye diseases, including age-related macula degeneration, diabetic retinopathy, central serous chorioretinopathy, and retinitis pigmentosa, suggesting an essential role in monitoring disease progression and response to treatment.^{23–25}

Agrawal et al.²⁶ were the first to use the CVI as a valid follow-up tool to quantify choroidal perfusion modifications in ocular diseases and a useful marker to better understand the pathophysiology of postoperative choroidal structure changes occurring after surgery.

Very few studies have analyzed CVI in vitreoretinal surgery, and fewer works focused on CVI in ERMs.^{27,28} Bernabei et al.²⁷ studied CVI changes after encircling scleral buckling for rhegmatogenous retinal detachment, thus, reporting an increase in LA, stromal area, and choroidal thickness if compared with fellow eyes,

but without differences in CVI because of not changing their proportions. They explained their results as a blood flow stasis because of an impaired circulation for LA increase and a venous drainage obstruction with consequent increased vascular resistance owing to the mechanical forces caused by encircling and buckling elements.²⁷

Our work aimed at investigating CVI fluctuations in ERMs after vitreoretinal surgery, comparing two different conditions: I-ERMS and secondary D-ERMS.

The association between choroidal thickness and the ERM is still questioned.

Mechanical traction on the macular area, either by vitreomacular traction or ERMs, may lead to choroidal thickening with possible different pathways.

Some studies have identified temporary differences in eyes that underwent vitrectomy, whereas other works reported no significant differences when comparing eyes with ERMs and fellow eyes.⁶ Some authors excluded an association between neither the develop-

ment nor the progression of ERMs with the CVI by evaluating this parameter in patients with ERMs at different stages.²⁹

Similar to our study, Rizzo et al.²⁸ focused on CVI changes in ERMs after vitrectomy with ERM removal and ILM peeling. Different from our study, they analyzed altogether eyes with macular pucker, full-thickness macular hole, and lamellar macular hole. They reported a gradual CVI decrease over a 3-month follow-up, speculating that preoperative vitreomacular traction could induce thickening of the choroid.

Conversely, our findings showed significant choroidal vascular fluctuations after vitrectomy and peeling ERM + ILM with different behavior in the two groups at one month follow-up, observing a significant decrease in the CVI in the I-ERMS group, likely owing to the release of anteroposterior traction and a significant increase of CVI in D-ERMS group, probably because of more choroidal inflammation owing to surgical trauma in diabetics. At the 3-month follow-up, the CVI tended to return to baseline values in I-ERMS and to decrease in D-ERMS, but without any statistical differences.

Indeed, diabetic patients may have a prevalent inflammatory component compared with I-ERMS. The higher levels of proinflammatory cytokines and vascular endothelial growth factor in the choroid of patients with diabetic retinopathy may be one of the underlying mechanisms of the upregulating expression postoperatively, which is demonstrated to induce a higher increase in CVI in patients with mild to moderate nonproliferative diabetic retinopathy than in nondiabetic patients after cataract surgery.³⁰

Chun et al.³¹ found a significant increase in CVI after phacoemulsification, particularly in the luminal vascular component, that was supposed to be linked both to choroidal inflammation owing to surgical trauma or to a dramatic intraocular pressure drop after cataract surgery.

Of note, the unique perspective of our work was the comparison between two different ERM-related pathogenesis: I-ERMS and D-ERMS, to better understand whether they behave differently with a consequent different response to vitrectomy also because of choroidal modifications, particularly in the early postoperative period.

It is well-known that I-ERMS and D-ERMS differ in pathophysiology, characteristics, and response to treatment. Our findings showed that, in the I-ERMS group, a faster increase in visual acuity was observed, whereas in the D-ERMS group, the BCVA increase was slower, thus underlining a slower or incomplete repositioning of foveal retinal layers in diabetics.

The significant changes in the CVI after surgery imply that the choroidal layer is affected by vitreomacular disease and can be used as a future potential biomarker of predictiveness in vitreoretinal surgery, particularly for functional outcomes.

Some mechanical traction may persist in the early period after vitrectomy, leading to multiple fluctuations of the choroid layer. Mechanical stretching of the retinal pigment epithelium may be responsible for vascular endothelial growth factor and other inflammatory cytokines released directly from the choroid with consequent retinal and choroidal vascular rearrangement owing to greater hyperpermeability.

It should consider the important role of vitreous oxygenation status after vitrectomy, particularly in diabetics, who are more vulnerable and can be involved in CVI modifications.

Some limitations of the study should be mentioned, such as the short follow-up, although the aim of the study was to focus on the early choroidal changes to understand initial predictive elements of long-term functional postoperative outcomes. A longer study is needed to follow changes in choroidal structure over time to verify if these fluctuations are completely reversible.

Acknowledgments

Authors Contributions: Study design, conceptualization, supervision and study management R.M., R.D.A.; L.T., performing experiments, data analysis and editing original manuscript A.P., M.D.N, and A.A.G.; samples collection, A.Q., M.G.; writing original manuscript R.M., R.D.A.; L.T., and M.L.R.

Data Availability Statement: Data and results supporting this study's findings are available upon reasonable request to the corresponding author.

Disclosure: **R. D'Aloisio**, None; **M.L. Ruggeri**, None; **A. Porreca**, None; **M. Di Nicola**, None; **A. Aharrh-Gnama**, None; **A. Quarta**, None; **M. Gironi**, None; **L. Toto**, None; **R. Mastropasqua**, None

References

- Smiddy WE, Maguire AM, Green WR, et al. Idiopathic epiretinal membranes. *Retina*. 2005; 25(Suppl):811–821.
- Yazici AT, Alagöz N, Çelik HU, et al. Idiopathic and secondary epiretinal membranes. *Retina*. 2011;31(4):779–784.

3. Kishi S, Shimizu K. Oval defect in detached posterior hyaloid membrane in idiopathic pre-retinal macular fibrosis. *Am J Ophthalmol.* 1994;118(4):451–456.
4. Sebag J. Vitreous: the resplendent enigma. *Br J Ophthalmol.* 2009;93(8):989–991.
5. Stevenson W, Prospero Ponce C, Agarwal D, Gelman R, Christoforidis J. Epiretinal membrane: optical coherence tomography-based diagnosis and classification. *Clin Ophthalmol.* 2016;10:527–534
6. Ozturk M, Guven D, Kacar H, Karapapak M, Demir M. Functional and morphological results of epiretinal membrane surgery in idiopathic versus diabetic epiretinal membranes. *Semin Ophthalmol.* 2021;36:399–372.
7. Harada C, Mitamura Y, Harada T. The role of cytokines and trophic factors in epiretinal membranes: involvement of signal transduction in glial cells. *Prog Retin Eye Res.* 2006;25(2):149–164.
8. Appiah AP, Hirose T. Secondary causes of premacular fibrosis. *Ophthalmology.* 1989;96(3):389–392.
9. Iannetti L, Accorinti M, Malagola R, et al. Role of the intravitreal growth factors in the pathogenesis of idiopathic epiretinal membrane. *Invest Ophthalmol Vis Sci.* 2011;52(8):5786.
10. Kampik A. Epiretinal and vitreous membranes. *Arch Ophthalmol.* 1981;99(8):1445.
11. Chang W, Lajko M, Fawzi AA. Endothelin-1 is associated with fibrosis in proliferative diabetic retinopathy membranes. Ljubimov AV, editor. *PLoS One.* 2018;13(1):e0191285.
12. Romaniuk D, Kimsa MW, Strzalka-Mrozik B, et al. Gene expression of IGF1,IGF1R, and IGFBP3 in epiretinal membranes of patients with proliferative diabetic retinopathy: preliminary study. *Mediators Inflamm.* 2013;2013:1–7.
13. Bringmann A, Wiedemann P. Involvement of Müller glial cells in epiretinal membrane formation. *Graefes Arch Clin Exp Ophthalmol.* 2009; 247(7):865–883. Available from: <https://pubmed.ncbi.nlm.nih.gov/19415318/>.
14. Govetto A, Lalane RA, Sarraf D, Figueroa MS, Hubschman JP. Insights into epiretinal membranes: presence of ectopic inner foveal layers and a new optical coherence tomography staging scheme. *Am J Ophthalmol.* 2017;175:99–113.
15. Iovino C, Au A, Chhablani J, et al. Choroidal anatomic alterations after photodynamic therapy for chronic central serous chorioretinopathy: a multicenter study. *Am J Ophthalmol.* 2020;217:104–113.
16. Iovino C, Pellegrini M, Bernabei F, et al. Choroidal vascularity index: an in-depth analysis of this novel optical coherence tomography parameter. *J Clin Med.* 2020;9(2):595.
17. Singh SR, Vupparaboina KK, Goud A, Dansingani KK, Chhablani J. Choroidal imaging biomarkers. *Surv Ophthalmol.* 2019;64(3):312–333.
18. Breher K, Terry L, Bower T, Wahl S. Choroidal biomarkers: a repeatability and topographical comparison of choroidal thickness and choroidal vascularity index in healthy eyes. *Transl Vis Sci Technol.* 2020;9:8.
19. Jonas JB, Forster TM, Steinmetz P, Schlichtenbrede FC, Harder BC. Choroidal thickness in age-related macular degeneration. *Retina* 2014;34:1149–1155.
20. Ahn SJ, Woo SJ, Park KH. Choroidal thickness change following vitrectomy in idiopathic epiretinal membrane and macular hole. *Graefes Arch Clin Exp Ophthalmol.* 2015;254(6):1059–1067.
21. Michalewska Z, Michalewski J, Adelman RA, Zawiślak E, Nawrocki J. Choroidal thickness measured with swept source optical coherence tomography before and after vitrectomy with internal limiting membrane peeling for idiopathic epiretinal membranes. *Retina.* 2015;35(3):487–491.
22. Casini G, Loiudice P, Lazzeri S, et al. Analysis of choroidal thickness change after 25-gauge vitrectomy for idiopathic epiretinal membrane with or without phacoemulsification and intraocular lens implantation. *Ophthalmologica.* 2017;237(2):78–84.
23. Agrawal R, Chhablani J, Tann KA. Choroidal vascularity index in central serous chorioretinopathy. *Retina.* 2016;36:1646–1651.
24. Sonoda S, Sakamoto T, Yamashita T, et al. Choroidal structure in normal eyes and after photodynamic therapy determined by binarization of optical coherence tomographic images. *Investig Ophthalmol Vis Sci.* 2014;55:3893.
25. Toto L, Ruggeri ML, Evangelista F, et al. Choroidal and retinal imaging biomarkers in different types of macular neovascularization. *J Clin Med.* 2023;12(3):1140.
26. Agrawal R, Salman M, Tan KA, et al. Choroidal vascularity index (CVI) - a novel optical coherence tomography parameter for monitoring patients with panuveitis? Paul F, editor. *PLoS One.* 2016;11(1):e0146344.
27. Bernabei F, Pellegrini M, Taroni L. Choroidal vascular changes after encircling scleral buckling for rhegmatogenous retinal detachment. *Eye.* 2020;35(9):2619–2623.

28. Rizzo S, Savastano A, Finocchio L, Savastano MC, Khandelwal N, Agrawal R. Choroidal vascularity index changes after vitreomacular surgery. *Acta Ophthalmol.* 2018;96(8):e950–e955.
29. Gediz BS, Doguizi S, Ozen O, Sekeroglu MA. Is choroidal vascularity index a useful marker in different stages of idiopathic epiretinal membranes? *Photodiagnosis Photodyn Ther.* 2021;33:102110.
30. Yao H, Gao S, Liu X, Zhou Y, Cheng Y, Shen X. Choroidal structural changes assessed with swept-source optical coherence tomography after cataract surgery in eyes with diabetic retinopathy. Nassisi M, editor. *J Ophthalmol.* 2020;2020:1–9.
31. Chun H, Kim JY, Kwak JH, et al. The effect of phacoemulsification performed with vitrectomy on choroidal vascularity index in eyes with vitreomacular diseases. *Sci Rep.* 2021;11(1):19898.