

# Alectinib Induced Regression of Renal and Hepatic Cysts Caused by Crizotinib

This article was published in the following Dove Press journal:  
International Medical Case Reports Journal

Pietro Di Marino<sup>1</sup>  
Gianluca Mannetta<sup>2</sup>  
Consiglia Carella<sup>3</sup>  
Antonino Grassadonia<sup>3</sup>  
Nicola Tinari<sup>3</sup>  
Clara Natoli<sup>3</sup>  
Michele De Tursi<sup>3</sup>

<sup>1</sup>Clinical Oncology Unit, S.S. Annunziata Hospital, Chieti, Italy; <sup>2</sup>Department of Neuroscience, Imaging and Clinical Sciences, "G. d'Annunzio" University, Chieti, Italy; <sup>3</sup>Department of Medical, Oral and Biotechnological Sciences University "G. D'Annunzio", Chieti-Pescara, Italy

**Background:** Crizotinib is the first tyrosine kinase inhibitor approved for the treatment of anaplastic lymphoma kinase (*ALK*) rearranged non-small cell lung cancer (NSCLC). An increased incidence of renal cysts has been described during the crizotinib treatment.

**Case Presentation:** We herein report the case of a 74-year-old woman who received crizotinib for metastatic *ALK*-positive NSCLC. During the crizotinib treatment, complex renal cystic lesions with invasion of perirenal spaces and iliopsoas muscle appeared; two complex hepatic cysts were also observed. Almost all lesions disappeared after switching to alectinib, a second-generation *ALK* inhibitor.

**Conclusion:** It would seem that alectinib is able to reduce in size and number hepatic and renal cysts caused by the crizotinib treatment. Nevertheless, further studies are needed to clarify the role of both crizotinib in the onset of renal and hepatic cysts and alectinib in their disappearance.

**Keywords:** anaplastic lymphoma kinase, crizotinib, alectinib, non-small-cell lung cancer, renal cysts, hepatic cysts

## Introduction

About 3–5% of NSCLC has a gene rearrangement of anaplastic lymphoma kinase (*ALK*).<sup>1,2</sup> Crizotinib is an oral first-generation tyrosine kinase inhibitor of *ALK*, ROS1 and MET, and it is the first drug shown to be superior to first-line platinum-pemetrexed chemotherapy in patients with advanced *ALK* positive NSCLC.<sup>3,4</sup> The most common and known side effects of crizotinib are vision disorders, diarrhea, edema, vomiting, elevation of alanine and aspartate aminotransferase levels, constipation and fatigue.<sup>5</sup> Renal cysts induced by crizotinib are rare, although they were first described by Lin et al in 2014; no guidelines for their management have been codified.<sup>6</sup>

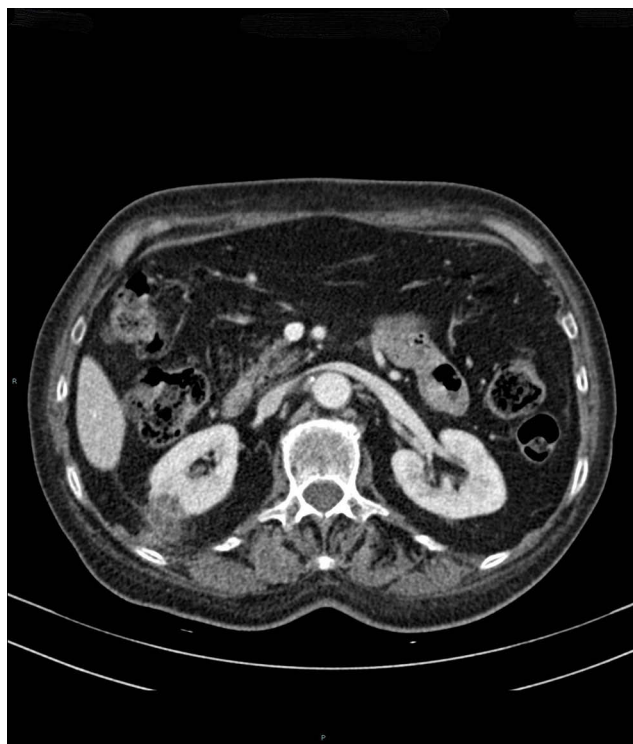
Here, we describe a case of a patient who developed renal and hepatic cysts during the crizotinib treatment for *ALK*-positive metastatic NSCLC. The cysts decreased in size and almost disappeared when changing the therapy to alectinib. Alectinib is a second generation of *ALK* inhibitors for the treatment of NSCLC. In the ALUR trial, alectinib significantly improved efficacy versus standard chemotherapy in *ALK* positive NSCLC patients who were intolerant or resistant to crizotinib.<sup>7</sup>

In the ALEX trial, alectinib showed superior efficacy and lower toxicity compared to crizotinib in untreated *ALK* positive NSCLC patients. To date, alectinib is the first-line standard of care for *ALK*- positive metastatic NSCLC.<sup>8</sup>

Correspondence: Pietro Di Marino  
Clinical Oncology Unit, PO SS  
Annunziata, Via Dei Vestini 5, Chieti  
66100, Italy  
Tel +39 871 35 8005  
Fax +39 871 35 8476  
Email pietrodimarino@gmail.com

## Case Report

A 74-year-old non-smoker woman was admitted to our hospital for acute confusional state with rapid onset of amnesia and dyspnea in July 2017. She had no significant medical history. Brain magnetic resonance imaging (MRI) scan and a whole-body computed tomography (CT) scan documented a pulmonary mass, mediastinal lymphadenopathies and multiple brain metastases, the largest one of 5.6 cm was in the left temporal lobe. An adenocarcinoma of the lung was diagnosed by biopsy performed via bronchoscopy. Fluorescent in situ hybridization (FISH) analysis of biopsied tumor tissue revealed the presence of *ALK* gene rearrangement. In August 2017, the patient started the crizotinib treatment after the whole brain radiotherapy. After 3 months, a CT scan showed a partial response of the disease in the chest and brain metastases were stable. After 8 months of the crizotinib therapy, a CT scan confirmed the stable disease for all lesions but it showed the appearance of multilocular cysts in both kidneys, the biggest of 3 cm, and a multilocular cyst starting from the right kidney to the perirenal adipose tissue and the posterior renal fascia (Figure 1). The patient had an Eastern Cooperative Oncology Group (ECOG) Performance Status 0; serum creatinine, C-reactive protein (CRP) and erythrocyte sedimentation rate were within normal ranges; blood cultures

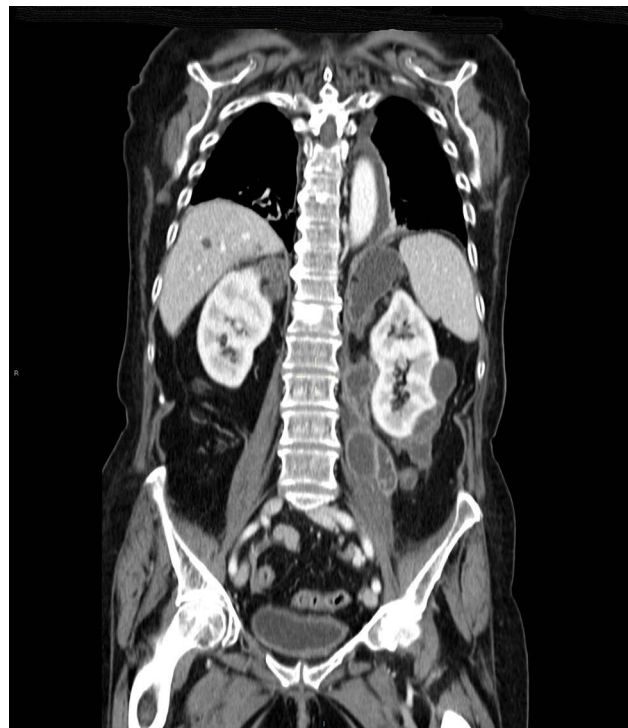

**Figure 1** During crizotinib treatment multilocular cysts appear in both kidneys.

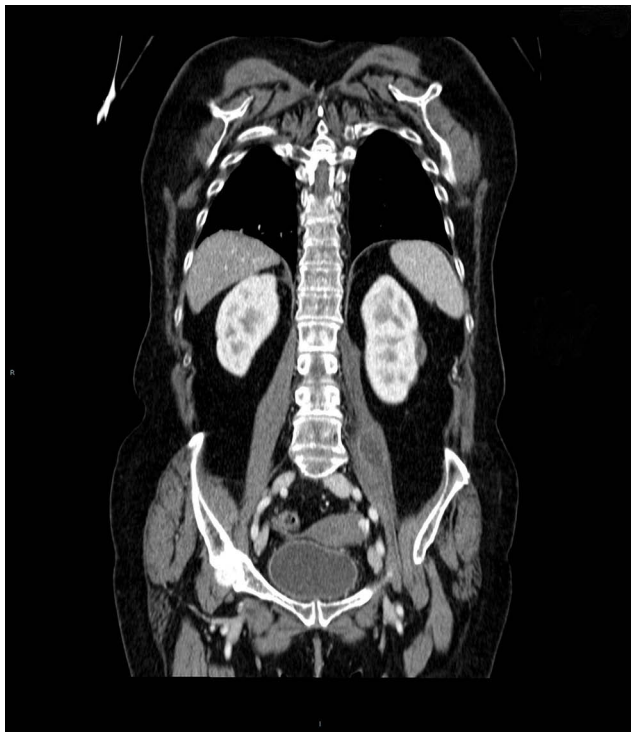were negative for both bacteria and fungi. Taking into account the clinical benefit, the patient continued the crizotinib treatment. In September 2018 a CT scan confirmed that the disease was stable, but it documented confluent cystic formations bounded by solid walls, extended posteriorly and bilaterally from the kidneys along the perirenal and paranrenal spaces: a cyst of 8 cm infiltrated the diaphragm and another one of 12 cm invaded the left iliopsoas muscle; two cystic hepatic lesions with thick walls also appeared, the biggest of 3 cm (Figure 2). The patient reported abdominal pain. Thus, the therapy was changed from crizotinib to alectinib, a second generation of *ALK* inhibitor approved for the treatment of metastatic NSCLC. In December 2018, after 3 months of the alectinib therapy, a CT scan confirmed that the disease was stable for the metastases affecting the brain, the chest and the abdomen and it showed the regression of cystic lesions in the kidneys, in the perirenal space and in the liver with a relevant reduction in size of the cystic lesion of the left iliopsoas muscle (2.8 cm versus 12 cm) (Figure 3).

## Discussion

The mechanisms underlying simple and complex cystic renal lesions during the crizotinib treatment are still



**Figure 2** By continuing the crizotinib treatment the confluent cystic formations extend from the kidneys to the diaphragm, to perirenal spaces, to the left iliopsoas muscle; two hepatic cysts appear.



**Figure 3** The cysts decreased in size and number by switching therapy to alectinib.

unknown. Crizotinib has been originally studied as an inhibitor of *c-MET* and subsequently tested for *ALK* and *ROS1*-rearranged NSCLCs.<sup>3</sup>

The development of renal cysts has been documented in about 4% of patients treated with crizotinib.<sup>6,9</sup> The molecular pathway of cystic formation is still not clear, but it has been previously reported that the activation of the *c-MET* pathway could be able to promote the onset of renal cysts.<sup>10</sup>

In mice kidneys, *c-MET* activation pathway decreased during the crizotinib treatment; it would seem to be a paradox.<sup>11</sup> Therefore by inhibiting *c-MET* pathway, crizotinib might stop the growth of pre-existing cystic lesions and prevent the onset of new renal ones.<sup>9</sup> This suggests that alternative pathways may be involved in cysts onset during the crizotinib treatment.<sup>10</sup>

Schnell et al reviewed 1375 patients enrolled in 4 large clinical trials and observed that 17 of these patients developed new renal cysts and the invasion of adjacent structures was reported in 7 patients.<sup>9</sup> It has been suggested only a close laboratory and radiological monitoring are necessary in asymptomatic cysts; although, in rare cases, crizotinib dose reduction or discontinuation is mandatory.<sup>9,12</sup> Here we report the onset of complex renal cysts, perirenal cysts that invaded adjacent structures such as the iliopsoas muscle, and two

hepatic cysts during the crizotinib treatment. The local extension of the cysts to adjacent tissues would require percutaneous drainage if the mass effect became clinically relevant.<sup>5</sup> During the crizotinib treatment when renal cysts appear, a concomitant reduction of glomerular filtration rate could occur.<sup>13</sup> In our case, at the onset of cysts, it was decided to continue the crizotinib treatment, considering the normal renal function, the absence of inflammatory indexes, the negative blood cultures and the absence of clinical symptoms such as abdominal pain, especially evaluating the possibility of the spontaneous regression continuing the crizotinib treatment.<sup>6,14,15</sup>

A superinfection of crizotinib-induced cysts was reported, so blood cultures were performed to exclude this condition.<sup>11,12</sup>

The hepatic cysts had the same radiological aspect as the renal ones, so biopsy had not been deemed necessary to exclude their metastatic nature.

To our best knowledge, only Halpenny et al have described the onset of hepatic cystic lesions during the treatment with crizotinib in 2017.<sup>16</sup> According to Lin et al the appearance of cysts during the crizotinib treatment could seem to be associated with a better progression-free survival and clinical benefit, therefore in our case, it was decided to continue the crizotinib treatment when the cysts appeared.<sup>6</sup> Abdominal pain and the invasive growth led us to switch to alectinib which rapidly induced regression of cystic lesions both in the kidneys and in the liver. After 3 months of alectinib, a CT scan showed a stable disease and brain metastases were also stable although this drug has a superior activity at intracranial level compared to crizotinib.<sup>8</sup>

Alectinib is a second-generation inhibitor of *ALK* and *RET*, and it does not inhibit *c-MET* unlike crizotinib.<sup>17</sup> It is more effective than standard chemotherapy in patients with metastatic NSCLC who are resistant or intolerant to crizotinib.<sup>8</sup> In 2014 Lin et al reported a case of renal cysts regression in a patient that was given alectinib for an *ALK* positive NSCLC which was resistant to crizotinib: during the alectinib treatment in 4 months, a small residual cyst remained.<sup>6</sup> In 2017, Taima et al reported a regression of a cystic lesion caused by crizotinib when they switched their therapy to alectinib: a 56-year-old man during the crizotinib treatment developed a complex cystic lesion from the right kidney to the iliopsoas muscle showing fever, anemia, hypoproteinemia and elevated CRP levels. When they switched to alectinib, the complex cyst rapidly regressed, fever disappeared, blood changes returned to

the normal range.<sup>18</sup> In our case, both kidney and hepatic cysts decreased in size and number during the alectinib treatment: this is the first report of regression of hepatic cysts caused by crizotinib during the alectinib therapy. However, we cannot exclude spontaneous cysts regression due to crizotinib discontinuation.<sup>6,14</sup>

In fact, the renal cysts caused by crizotinib can disappear by stopping the treatment if they become clinically symptomatic.<sup>14</sup> Spontaneous regression of cysts induced by crizotinib was reported during continuous crizotinib therapy.<sup>15</sup> In our case, the crizotinib discontinuation and the simultaneous changing of therapy to alectinib could have accelerated the disappearance of the cysts, which they could decrease in size and number in several months after crizotinib discontinuation.<sup>6,15</sup>

Advances in the molecular biology of crizotinib-induced cytogenesis may provide an insight into the future management of this condition.

## Conclusion

In this case report, alectinib confirms the possibility to reduce renal cysts in size and number and could reduce hepatic cysts caused by crizotinib treatment, but spontaneous cysts regression due to the crizotinib discontinuation cannot be excluded. Further studies are needed to explain molecular pathways involved in the crizotinib-induced cytogenesis and to clarify the role of alectinib in cysts disappearance.

## Acknowledgments

This work was supported by the Consorzio Interuniversitario Nazionale per la Bio Oncologia (CINBO).

## Disclosure

The patient has provided written informed consent for the details of the case and the accompanying images and the institutional approval of the Oncology Unit (S.S. Annunziata Hospital, Chieti, Italy) was required to publish the case details. The authors report no conflicts of interest in this work.

## References

- Soda M, Choi YL, Enomoto M, et al. Identification of the transforming EML4-ALK fusion gene in non-small-cell lung cancer. *Nature*. 2007;448:561–566. doi:10.1038/nature05945

- Solomon B, Varella-Garcia M, Camidge DR. ALK gene rearrangements. A new therapeutic target in a molecularly defined subset of non-small cell lung cancer. *J Thorac Oncol*. 2009;4(12):1450–1454. doi:10.1097/JTO.0b013e3181c4ddeb
- Christensen JG, Zou HY, Arango ME, et al. Cytoreductive antitumor activity of PF-2341066, a novel inhibitor of anaplastic lymphoma kinase and c-Met, in experimental models of anaplastic large-cell lymphoma. *Mol Cancer Ther*. 2007;6(12 Pt1):3314–3322. doi:10.1158/1535-7163.MCT-07-0365
- Solomon BJ, Mok T, Kim DW, et al. First line Crizotinib versus chemotherapy in ALK-positive lung cancer. *N Engl J Med*. 2014;371(23):2167. doi:10.1056/NEJMoa1408440
- Cappuzzo F, Moro-Sibilot D, Gautschi O, et al. Management of crizotinib therapy for ALK-rearranged non-small cell lung carcinoma: an expert consensus. *Lung Cancer*. 2015;7(2):89–95. doi:10.1016/j.lungcan.2014.12.010
- Lin YT, Wang YF, Yang JC, et al. Development of renal cysts after crizotinib treatment in advanced ALK-positive non-small-cell lung cancer. *J Thorac Oncol*. 2014;9(11):1720–1725. doi:10.1097/JTO.0000000000000326
- Novello S, Mazières J, Oh JI, et al. Alectinib versus chemotherapy in crizotinib-pretreated anaplastic lymphoma kinase (ALK)-positive non-small-cell lung cancer: results from the phase III ALUR study. *Ann Oncol*. 2018;29(6):1409–1416. doi:10.1093/annonc/mdy121
- Peters S, Camidge DR, Shaw AT, et al. Alectinib versus crizotinib in untreated ALK-positive non-small-cell lung cancer. *N Engl J Med*. 2017;377(9):829–838. doi:10.1056/NEJMoa1704795
- Schnell P, Bartlett CH, Solomon BJ, et al. Complex renal cysts associated with crizotinib treatment. *Cancer Med*. 2015;4(6):887–896. doi:10.1002/cam4.437
- Horie S, Higashihara E, Nutahara K, et al. Mediation of renal cyst formation by hepatocyte growth factor. *Lancet*. 1994;344(8925):789–791. doi:10.1016/S0140-6736(94)92344-2
- Yasuto Y, Isamu O, Masako AO, et al. Infected complex renal cysts during crizotinib therapy in a patient with non-small cell lung cancer positive for ALK rearrangement. *Invest New Drug*. 2015;33(2):510–512. doi:10.1007/s10637-014-0195-1
- Chan WY, Ang MK, Tan DS, Koh WL, Kwek JW. Imaging features of renal complication after crizotinib treatment for non-small lung cancer: a case report. *Radiol Case Rep*. 2016;11(3):245–247. doi:10.1016/j.radcr.2016.04.010
- Yasuma T, Kobayashi T, D'Alessandro-Cabazza CN, et al. Renal injury during long-term crizotinib therapy. *Int J Mol Sci*. 2018;19(10):2902. doi:10.3390/ijms19102902
- Cameron LB, Jiang DH, Moddie K, Mitchell C, Solomon B, Parameswaran BK. Crizotinib associated renal cysts (CARS): incidence and pattern evolution. *Cancer Imaging*. 2017;17(1):7. doi:10.1186/s40644-017-0109-5
- Klempner SJ, Aubin G, Dash A, Ou S-HI. Spontaneous regression of crizotinib-associated complex renal cysts during continuous crizotinib treatment. *Oncologist*. 2014;19(9):1008–1010. doi:10.1634/theoncologist.2014-0216
- Halpenny DF, McEvoy S, Li A, et al. Renal cyst formation in patients treated with crizotinib for non-small cell lung cancer-incidence, radiological features and clinical characteristics. *Lung Cancer*. 2017;106:33–36. doi:10.1016/j.lungcan.2017.01.010
- Vavalà T, Novello S. Alectinib in the treatment of ALK-positive non-small cell lung cancer: an update on its properties, efficacy, safety and place in therapy. *Ther Adv Med Oncol*. 2018;3(10):1–12.
- Taima K, Tanaka H, Tanaka Y, Ittoga M, Takanashi S, Tasaka S. Regression of crizotinib-associated complex cystic lesions after switching to alectinib. *Intern Med*. 2017;56(17):2321–2324. doi:10.2169/internalmedicine.8445-16

### International Medical Case Reports Journal

Dovepress

#### Publish your work in this journal

The International Medical Case Reports Journal is an international, peer-reviewed open-access journal publishing original case reports from all medical specialties. Previously unpublished medical posters are also accepted relating to any area of clinical or preclinical science. Submissions should not normally exceed 2,000 words or 4

published pages including figures, diagrams and references. The manuscript management system is completely online and includes a very quick and fair peer-review system, which is all easy to use. Visit <http://www.dovepress.com/testimonials.php> to read real quotes from published authors.

Submit your manuscript here: <https://www.dovepress.com/international-medical-case-reports-journal-journal>