

# Histological aspects of cellulite: shedding light on 100 years of uncertainties

M.S. DI CARMINE<sup>1</sup>, D. AMUSO<sup>1</sup>, A. GRECO LUCCHINA<sup>2</sup>, L. VALBONETTI<sup>3</sup>,  
F. LORUSSO<sup>1</sup>, A. SCARANO<sup>1</sup>

<sup>1</sup>Department of Innovative Technologies in Medicine and Dentistry, University of Chieti-Pescara, Chieti-Pescara, Italy

<sup>2</sup>Research Laboratory in Regenerative Medicine and Tissue Engineering, Saint Camillus International University of Health Sciences, Rome, Italy

<sup>3</sup>Faculty of Biosciences and Technology for Food, Agriculture and Environment, University of Teramo, Teramo, Italy

**Abstract.** – Cellulite is a common topographic condition of the skin manifested as lumpy, dimpled flesh resembling an orange peel on some zones such as the thighs, hips, buttocks and abdomen.

The aetiology of this cosmetic issue is multifactorial, with hormonal, anatomical, environmental and genetic factors influencing its origin, although the exact mechanisms which cause this condition are still unknown. In the present work, a bibliographic analysis of the cellulite etiology has been updated and exposed, as well as the multiple classification grade scales established over the decades. In addition, a new method to classify cellulite severity, in which the clinical manifestations are correlated to the histological aspects more frequently found in the patients, has been presented.

Several theories regarding its appearance, structure and clinical aspects have arisen with the aim of developing and establishing a valuable therapeutic approach. However, the lack of a consensus regarding the classification of cellulite severity has complicated the developments within this field.

*Key Words:*

Cellulite, Panniculitis, Gynoid Lipodystrophy, Edematofibrosclerotic Panniculopathy, Histology, Etiology.

## Introduction

Cellulite, also known as edematofibrosclerotic panniculopathy, panniculitis or gynoid lipodystrophy, depending on the morbidity, is a common condition of the skin, characterized by a lump and dimpled aspect of the thighs and buttocks, resembling an orange peel<sup>1</sup>. Even though the exact prevalence of this condition is currently unknown due

to the absence of epidemiological works, cellulite is estimated to affect approximately the 80-90% of women in the post-pubertal age, being mainly localized on the posterolateral thighs, buttocks and abdomen, and affecting preferentially women than men<sup>2</sup>. This condition is associated with several uncertainties related to its etiology, the wide variety of treatments and the selection of a histological model common to all patients, among others. In fact, one of the most discussed issues about cellulite remains its consideration as a pathology or not, being described as an aesthetic condition or a systemic issue depending on the authors<sup>3,4</sup> and the presence of comorbid disorders such as lipoedema. Even if cellulite is not a critical condition from a medical point of view, it is one of the most widespread and least tolerated aesthetic disorders among women<sup>5</sup>. The first evidence of scientific works on this aim date back to 1992, when Alquier and Pavot<sup>6</sup> defined it as a dystrophy of the mesenchymal tissues characterized by interstitial fluid retention, which was considered to be an elementary reaction of the connective tissue caused by multiple stimuli (trauma, infections, endocrine disruptions). Today, it is widely accepted that the etiology of cellulite is heterogeneous, with environmental, genetic, anatomical and hormonal factors influencing its origin. For instance, a sedentary lifestyle with a high intake of fats, preservatives and salt has been related to an accelerated appearance of cellulite due to an excess of subcutaneous fat<sup>7</sup>, probably by increasing the underlying inflammation and disturbing the correct microcirculation<sup>8</sup>. The genetic background of this condition is still unclear, although a multi-locus genetic study demonstrated an independent role of two different genes in predisposing to cellulite<sup>9</sup>.

Hormonal imbalances, such as high concentration of estrogens compared to progesterone, are also crucial for the development of cellulite, a situation occurring during pregnancy, maturation, menopause and hormone replacement therapy<sup>10</sup>. However, despite of the knowledge acquired throughout the last 70 years, the exact mechanism by which cellulite appears and the specific causes triggering this condition in every individual are unknown at the moment. Furthermore, the great quantity of works published in a language different from English (e.g., Polish, Spanish, Italian, French) complicates the communication and the information exchange between researchers and clinicians working into this field, hampering the elucidation of the exact etiology and thus also the establishment of appropriate treatments. Although several recent works have focused in enumerating the vast availability of treatments currently applied to reduce or eliminate this condition, the information regarding the histology aspects and the establishment of a suitable classification depending on the severity is scarce to date. Thus, all the published data in the present work regarding the etiology of this condition have been reviewed to offer an updated and synthetic report. While the differences among normal skin (dermis, epidermis and adipocytes) and imbalanced skin are exposed and graphically represented, the main focus of this review is the establishment of a valuable classification that could be used as a guide to classify cellulite by its severity, gathering all the information regarding the grade-scales and based on the histology aspects of this condition.

### **Etiology of Cellulite**

Cellulite is considered as a multifactorial condition that can be manifested by several reasons and with an unknown clear etiology. However, to date it is possible to classify the causes in four main groups which may act alone or in combination: genetic, environmental, anatomical and hormonal factors.

#### **Genetic Fqrs**

The genetic background of cellulite is still unknown, although genetic factors have been proposed to play a key role. Around the 85% of females are affected by this condition, which is rarely present in men. Moreover, it affects mostly Caucasian/white women, with a lower prevalence in African Ameri-

can/black and Asian women<sup>3,11</sup>, and it is transmitted from mother to daughters. Interestingly, genetic variants in two different genes (*ACE*, codifying for angiotensin-converting enzyme and *HIF1A*, codifying for hypoxia-inducible factor 1) have been associated with cellulite in healthy women<sup>9</sup>. While *ACE* has been proposed to affect angiotensin II formation also in the subcutaneous adipose tissue, a high *HIF1A* expression has seen to be able to initiate a fibrosis process in the adipose tissue, promoting local inflammation and impairing the endocrine function of healthy adipocytes<sup>12</sup>. However, further studies are still needed to investigate the presence of these genes and others in human adipose and dermal tissues of women presenting or not this condition, as well as the interactions between these genes and the environment.

### **Environmental Factors**

The assumption of salt and preservatives in high quantities and an imbalanced diet plenty of fat products is strongly correlated to the appearance of this cosmetic issue, which worsens with the increase of the body mass index (BMI) and obesity. A sedentary lifestyle is critical in this condition, and due to the ability of alcohol to stimulate the lipogenesis and dehydration, its frequent assumption may contribute to the increased severity<sup>3</sup>. Smoking tobacco constitutes another precipitant of cellulite by inducing oxidative stress, which may induce the release of proteolytic enzymes able to alter the production of the skin connective tissue. Interestingly, it seems to be correlated to an *ACE* polymorphism<sup>13,14</sup>.

### **Anatomical Factors**

To date, it is well-accepted the implication of the dermis alone or in combination with subcutaneous tissues<sup>15</sup>. As already stated by Nurnberger and Muller in 1978<sup>4</sup>, the dermis in women is thinner than in males, with the subcutaneous fat organized in vertical sections and wider and taller compared to males. The fibrous septae that separates the fat compartments are as well vertically positioned, which predispose females to the appearance of cellulite due to the protrusion of the subcutaneous fat, as recently reviewed by Arora et al<sup>16</sup>. In addition, the disturbance of the microvascular and lymphatic circulation of the subcutaneous fat tissue in which the lymphatic drainage and vascular circulation are

low predisposes to an increase in the fat layers and thus the appearance of this cosmetic issue.

### Hormonal Factors

Sex hormones, and especially estrogens, play a key role in the development and progression of gynoid lipodystrophy. Hypoestrogenism appears physiologically during pregnancy, puberty and menopause, or following a hormone replacement therapy and systemic hormone contraceptive intake. An increase in this hormone concentration may induce a vascular relaxation, blood stasis, swelling ischemia and hypoxia in the subcutaneous tissue<sup>3</sup>, which could be magnified with a lack of progesterone and thus a hormonal imbalance. Although estrogens are the major triggers of this issue, an imbalance of the endocrine system can also contribute to its appearance<sup>10</sup>. For instance, adiponectin expression was found to be reduced<sup>17</sup> in areas affected by cellulite. Considering its anti-inflammatory and vasodilatory roles in the adipocytes, researchers<sup>17</sup> hypothesized its reduction as a contributor of the altered microcirculation of these regions that could lead to the progression of the issue.

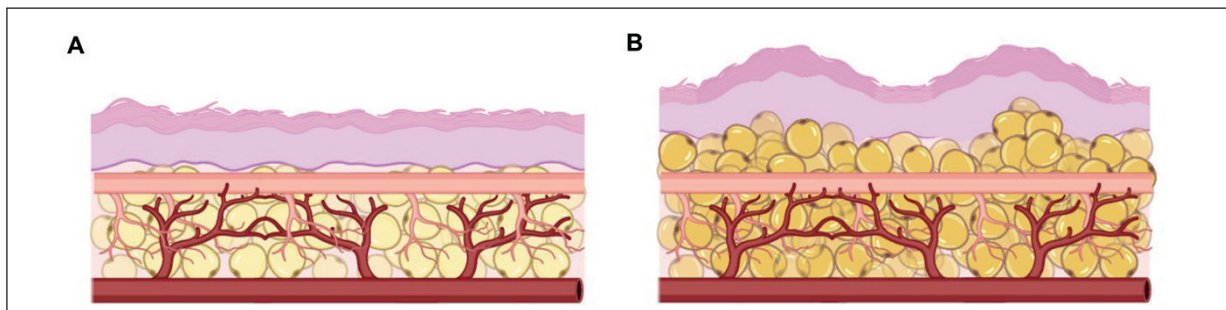
### Female Subcutaneous Composition and Architecture

The adipose tissue is constituted by adipocytes, which are dispersed within a matrix of collagen fibers and surrounded by other cell types as preadipocytes, endothelial cells, myocytes, fibroblasts, leukocytes and macrophages.

The presence of white blood cells is an indicator of the important function of this tissue, beyond its role in lipid storage. Two main functions characterize the adipocytes: their implication in the correct metabolism of the fatty acids and the regulation endocrine system, achieved in part due to the great quantity of endocrine receptors and hormones secreted by this cell type<sup>3</sup>. The development and progression of cellulite is strongly influenced by two processes, normally occurring in fat cells: lipogenesis and lipolysis. While lipogenesis contributes to the increase of the fatty tissue, lipolysis is defined as the metabolic process causing the decomposition of the stored fatty acids. The correct balance between these two processes is necessary to avoid or contain the progression of cellulite. As stated by Rudolph et al<sup>18</sup> in their work focused on the architecture arrangement of the gluteal subcutaneous tissue and its biomechanical forces, the presence or absence of cellulite depends on the balance between the dermis, the septal connections and the architecture of the superficial and deep adipocytes layers, which can be considerably higher in cases of a high BMI. Figure 1 shows a schematical representation of the subcutaneous composition and architecture.

### Classification of Cellulite: Grade-Scales and the Absence of Consensus

Evaluating and grading the severity of gynoid lipodystrophy with a consensus is crucial to determine the best treatment choice and monitoring the outcomes. However, one of the biggest concerns of this field is the absence of a clear and precise meth-



**Figure 1.** Graphical representation of the subcutaneous tissue with (A) and without (B) the presence of cellulite. From external to internal: the epidermis, dermis and the subcutaneous tissue. Subcutaneous tissue is formed by adipocytes embedded in a collagen matrix, in absence of cellulite (A) and with the presence of cellulite (B). In (B), adipocytes are higher and irregular, and the epidermis and dermis present depressed crypts due to the biomechanical forces caused by the extrusion of the adipose tissue into the dermal tissues. Created with BioRender.com.

**Table I.** Classification of Binazzi and Grilli Cicilioni<sup>19</sup>.

Stage	Clinical manifestations	Histological examination
I	Adiposity, irregularity of the cutaneous surface of buttocks, thighs, abdomen and shoulders (“mattress effect”).	Anisopoichilocytosis*, dermis oedema, dilation of lymphatic vessels, patches of follicular hyperkeratosis).
II	Nodular lesions on palpation, mobile and painful, diameter 1 to 6 mm.	Deep subversion of the subcutaneous tissue with connective bands encircling adipose lobules; hemorrhagic or thrombotic vessel alterations.

\*Anisopoichilocytosis: intended as the extreme variability in the size and form of the adipocytes.

od to evaluate the severity of this condition. Several grade-scales have been proposed since 1977, when Binazzi and Grilli Cicilioni<sup>19</sup> and Binazzi and Papini<sup>20</sup> set the basis for the interpretation of the histopathological aspects of cellulite establishing a 2 stages-scale, as defined in Table I.

In 1978, Nürnberger and Müller<sup>4</sup> suggested the division into three grades (Table II).

Some years later, Curri et al<sup>21</sup> established in 1993 a four-stage scale to evaluate cellulite severity, which is still considered as a landmark. Following this classification, the main factor has been identified to be a chronic “microcirculatory maldistribution” which may be due to

a defect of the arterial device modulating the normal blood flow or even to an inadequate vasomotion. Thus, cellulite severity can be divided in edematose, fibrous, soft sclerotic and sclerotic (Table III).

This classification was later improved by Bartoletti et al<sup>22</sup> differentiating the cellulite from peritrochanteric adiposity, which was considered as morphological and physiologically normal. Moreover, the authors<sup>22,23</sup> re-examined the clinical classification including the salient points, general examination, phlebological study, postural evaluation and ultrasound, establishing the most followed therapeutic protocols to date<sup>23</sup>. The studies

**Table II.** Classification of cellulite severity by Nürnberger and Müller<sup>4</sup>.

Grade	Skin appearance	Subgroups
I	Smooth at rest	-
II	Mattress or orange peel at rest	Mild, moderate, severe
III	Mattress or orange peel with nodules intermixed with raised and depressed areas at rest	Mild, moderate, severe

**Table III.** Classification of cellulite severity by Curri<sup>21</sup>.

Stage	Clinical manifestations	Pathogenesis	Histological aspects
I (Edematose)	Pale and pasty skin	Microcirculatory maldistribution and defective vasomotion	Lipoedema, anisopoichilocytosis, membrane rupture
II (Fibrous)	Cutaneous hyperelasticity, hyperthermia, paresthesia	Stasis, sludge, microvessal ectasia, abnormal hypovolemia, and zonal hypoxia	Regressive adipocyte manifestations, massive microvessal dilatation, fibrillopoiesis
III (Soft sclerotic)	Orange peel skin and palpable small lumps	Reduction in capillary flow, increase in the areas of hypoxia	Neofibrillogenesis, adipocytes encapsulated in micronodules
IV (Sclerotic)	Painful nodules	Stasis, hypovolemia, teleangectasia and microvaricosity	Macronodules surrounded by sclerotic connecting collagen bundles and local dystrophic dermis and epidermis

performed *in vivo* and *in vitro* by Rosenbaum et al<sup>24</sup> showed some interesting gender-related differences, as the diffuse pattern of discontinuous and irregular connective tissue below the dermis layer of women, which was more evidenced in affected individuals. As stated by the authors<sup>24</sup>, a sexual dimorphism in the structure of the subdermal connective tissue exists, predisposing women to develop the characteristic irregular extrusion of the adipose tissue into the dermis. In 2000, based on the classification established by Bartoletti et al<sup>25</sup>, Rossi and Vergnanini<sup>26</sup> gathered in a complete review work the classification of Curri<sup>21</sup>, updated and integrated with the classification by skin consistency previously established by Bartoletti et al<sup>25</sup>. The clinical and histopathological manifestation graded from I to IV (Table IV)<sup>26</sup>, while the skin consistency was classified as follows:

- Hard: mostly observed in young athletic women and teenagers. Skin appearance is compact and firm, with peel orange evident only after palpation.
- Flaccid: mainly observed in sedentary women. Related to muscular hypotonia and flaccidity or sudden weight loss. Evident padded surface with skin shakes when in movement. Circulatory disturbances are normal (telangiectasias, varices).
- Edematous: most severe and least frequent form. Increased volume of the lower limbs, tissue de-

pression after fingertip palpation. Thinner and brighter skin, sense of heaviness and sore legs.

- Mixed: most common form, mixing two or more forms among the above described.

Lotti et al<sup>27</sup> described the existence of an anomalous connective response that can result in an increased collagen deposition in the subcutaneous tissue due to the retention of liquids in the interstitial matrix<sup>27</sup>. Some years later, in 2009, Hexsel et al<sup>28</sup> established a new photonumeric method to grade cellulite, the so-called cellulite severity scale (CSS)<sup>28</sup>. This grade scale was divided into five clinical and morphological aspects taken from 55 patients previously photographed (Table V). However, this method was only based on the clinical manifestations, without being correlated to the histological aspects of the issue.

To follow the classification proposed by Nürnberger and Müller<sup>4</sup>, the patients should be evaluated in the standing position, with the possibility to apply the pinch test in case of no evident depressions. By following the above classification, authors<sup>4</sup> established a new score system in which a score of 1-5 corresponded to a mild form of cellulite, 6-10 to a moderate form, and 11-15 to the severe form of this condition. As stated by de la Casa Almeida et al<sup>29</sup>, this scale is reliable when evaluating the cellulite severity of the posterior thighs and buttocks, although the laxity score is consid-

**Table IV.** Classification of cellulite severity by Rossi and Vergnanini<sup>26</sup>.

Grade	Clinical manifestations	Histology
I	No clinical manifestations	Increased thickness of the areolar layer, increased capillary permeability, adipocyte anisopoikilocytosis, diapedetic microhemorrhages, capillary ectasia and fusiform microaneurysms within the postcapillary venules
II	Clinically unapparent at rest, with dimples evidents after muscular contraction or skin pinching	Hyperplasia and hypertrophy of the periadipocyte and pericapillary argentaffin fibril framework, capillary dilatation, microhaemorrhages and increased thickness of the capillary basement membrane
III	Mild clinical manifestations at rest, palpable sensation of thin granulations in the deep levels, pain to palpation, decreased elasticity, pallor and decreased temperature	Micronodules, sclerosis and thickening of small arteries, dilation of venules and small veins, microaneurysms and dilation of venules and small veins, microaneurysms and x capillaries, obliteration of the border between the dermis and subcutaneous tissue, sclerosis with inclusion of adipocytes within the connective tissue of the deep dermis
IV	Severe clinical manifestation at rest, with more palpable, visible and painful nodules and obvious wavy appearance of the skin surface	Disappeared lobular structure of the fatty tissue, encapsulated nodules by dense connective tissue, diffuse liposclerosis (microcirculatory alterations), telangiectasias, microvarices and varices, epidermal atrophy

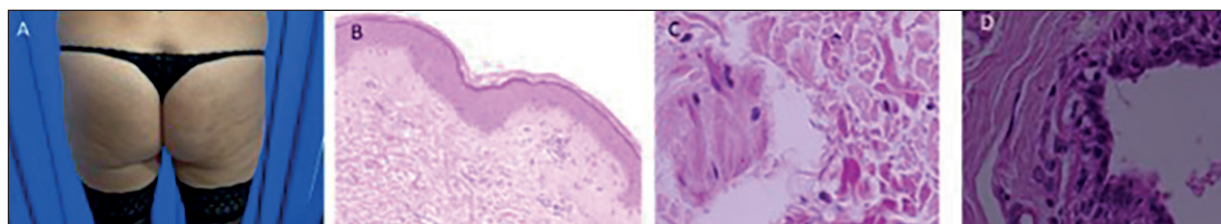
**Table V.** Classification of cellulite severity by Hexsel et al<sup>28</sup>.

Grade		Scores
I	Number of evident depressions	0 = No depressions 1 = small amount (1-4 depressions) 2 = moderate amount (5-9 depressions) 3 = large amount (10 or more depressions)
II	Depth of depressions	0 = No depressions 1 = Superficial depressions 2 = Medium depth depressions 3 = Deep depressions
III	Morphological appearance of skin surface alterations	0 = No raised areas 1 = Orange peel appearance 2 = Cottage cheese appearance 3 = Mattress appearance
IV	Grade of laxity, flaccidity or sagging skin	0 = Absence of laxity, flaccidity or sagging skin 1 = Slight draped appearance 2 = Moderate draped appearance 3 = Severe draped appearance
V	Classification scale by Nürnberger and Müller	0 = Zero grade 1 = First grade 2 = Second grade 3 = Third grade

ered not essential and may reduce the internal consistency scores of the grade scale<sup>29</sup>. The scientific developments in terms of instruments and technology have step by step contributed to improve our knowledge about this condition. For instance, the development of techniques, such as the magnetic resonance imaging (MRI) and spectroscopy, have allowed Querleux et al<sup>30</sup> to quantify the deeper indentations of the adipose tissue into the dermis, evidencing the increased thickness of the inner layer of the fat in women presenting cellulite, also showing the higher percentage of fibrous septae perpendicular to the skin surface of women<sup>30</sup>.

### In Search of Consensus: Combining Clinical and Histological Aspects

The most recent work focused on the evaluation of cellulite severity has established the presence of five clinical aspects based on a pilot study<sup>31</sup> conducted on 60 patients, in which the presence of cellulite was evaluated by clinical examination, instrumental analysis and ultrasounds and then correlated to the histological aspects<sup>31,32</sup>. The authors<sup>31</sup> showed a pattern shared among most of the individuals participating in the study, confirming the histological evaluation reported by Curri in 1993<sup>21</sup> but with a novelty: the histological evidence



**Figure 2.** Histological aspects from the same patient.

**Table VI.** Classification of cellulite severity by Scarano et al<sup>32</sup>.

Clinical aspect	Epidermis	Dermis	Hypodermis
1	No alterations	No alterations	No alterations
2	No alterations	Mild edema in the reticular dermis	Anisopoikilocytosis and edema in the adipose tract next to the dermis
3	Islands of keratinocyte hypertrophy alternated with flattening of the stratum corneum; depth reduction of the dermal spines; alteration of cell replication at baseline	Alteration of the quality of hyaluronic acid; subversion of the regular structural architecture of collagen (disordered orientation) and elastic fibers (shortened and fragmented in some points); alteration of the presence of skin appendages; alteration of the microcirculation with collapse of the arterioles and venules; dilation of the lymphatics; edema in the reticular dermis; thickening of the connective fibers in some points; presence of adipocytes different in shape and size from the subcutaneous adipocytes	Presence of anisopoikilocytosis, concentric organization of the adipose cells that participate in the formation of micronodules; alteration of the microcirculation both for the arterioles and the venules that appeared collapsed and or destructured; lymphatic vessels both dilated and absent in the perimeter points of the microns.
4	Similar to aspect 3	Similar to aspect 3 with the presence of adipocytes	Further thickening of the connective shoots delimiting the micronodules with areas of adipose tissue where the connective shoots appeared lysed; presence of micronodules that merge with each other; completely altered microcirculation with arterioles and veins devoid of blood content, non-existing lymphatics
5	Similar to aspect 3	Similar to aspect 3 but with the presence of adipocytes organized	Complete subversion in the organization of the adipose tissue with a notable presence of macronodules, in the area with giant adipose cells presenting calcified concretions inside; absence of organization of the microcirculation; dermal nodules mostly composed of adipocytes trapped between type I collagen fibers

does not characterize the different states of cellulite, but several different histological aspects were present in the same patient (Table VI, Figure 2).

## Conclusions

All the clinical and histological elements described in literature were found in the samples analyzed in recent literature<sup>31,32</sup>, without correlation with the clinical and histological aspects, confirming that cellulite is really a multifactorial condition whose pathophysiology is not fully known.

## Conflict of Interest

The Authors declare that they have no conflict of interests.

## Funding

This study did not receive any specific grant from funding agencies in the public, commercial, or not-for-profit sectors.

## Availability of Data and Materials

All data generated or analyzed during this study are included in this published article.

### Authors' Contribution

All authors were involved with the literature review and performance of the surgery. All authors read and approved the final manuscript.

### ORCID ID

Domenico Amuso: 0000-0002-1841-5277;  
 Alberta Greco Lucchina: 0000-0002-1985-4263;  
 Luca Valbonetti: 0000-0001-5914-615X;  
 Felice Lorusso: 0000-0002-2660-9231;  
 Antonio Scarano: 0000-0003-1374-6146.

### References

- 1) Hexsel D, Soirefmann M. Cellulite: Definition and Evaluation. In: Humbert, P., Fanian, F., Maibach, H., Agache, P. (eds) *Agache's Measuring the Skin*. Springer Cham 2017; 28: 695-702.
- 2) Luebberding S, Krueger N, Sadick NS. Cellulite: An Evidence-Based Review. *Am J Clin Dermatol* 2015; 16: 243-256.
- 3) Tokarska K, Tokarski S, Woźniacka A, Syssa-Jędrzejowska A, Bogaczewicz J. Cellulite: a cosmetic or systemic issue? Contemporary views on the etiopathogenesis of cellulite. *Adv Dermatol Allergol Dermatol Alergol* 2018; 35: 442.
- 4) Nürnberger F, Müller G. So-called cellulite: an invented disease. *J Dermatol Surg Oncol* 1978; 4: 221-229.
- 5) Bacci PA, Leibaschoff G. Pathophysiology of Cellulite. *Cellulite* 2006; 22: 62-95.
- 6) Terranova F, Berardesca E, Maibach H. Cellulite: nature and aetiopathogenesis. *Int J Cosmet Sci* 2006; 28: 157-167.
- 7) Roe E, Serra E, Guzman G, Sajoux I. Structural Changes of Subcutaneous Tissue Valued by Ultrasonography in Patients with Cellulitis Following Treatment with the PnKCellulitis® Program. *J Clin Aesthetic Dermatol* 2018; 11: 20.
- 8) Lupi O, Semenovitch IJ, Treu C, Bottino D, Bouskela E. Evaluation of the effects of caffeine in the microcirculation and edema on thighs and buttocks using the orthogonal polarization spectral imaging and clinical parameters. *J Cosmet Dermatol* 2007; 6: 102-107.
- 9) Emanuele E, Bertona M, Geroldi D. A multilocus candidate approach identifies ACE and HIF1A as susceptibility genes for cellulite. *J Eur Acad Dermatol Venereol* 2010; 24: 930-935.
- 10) Leszko M. Cellulite in menopause. *Przegląd Menopauzalny Menopause Rev* 2014; 13: 298.
- 11) Tanzi EL, Capelli CC, Robertson DW, LaTowsky B, Jacob C, Ibrahim O, Kaminer MS. Improvement in the appearance of cellulite and skin laxity resulting from a single treatment with acoustic subcision: Findings from a multicenter pivotal clinical trial. *Lasers Surg Med* 2022; 54: 121-128.
- 12) Halberg N, Khan T, Trujillo ME, Wernstedt-Asterholm I, Attie AD, Sherwani S, Wang ZV, Landskroner-Eiger S, Dineen S, Magalang UJ, Brekken RA, Scherer PE. Hypoxia-inducible factor 1alpha induces fibrosis and insulin resistance in white adipose tissue. *Mol Cell Biol* 2009; 29: 4467-4483.
- 13) Stavroulaki A, Pramantiotis G. Cellulite, smoking and angiotensin-converting enzyme (ACE) gene insertion/deletion polymorphism. *J Eur Acad Dermatol Venereol* 2011; 25: 1116-1117.
- 14) Pérez Atamoros FM, Alcalá Pérez D, Asz Sigall D, Ávila Romay AA, Barba Gastelum JA, de la Peña Salcedo JA, Escalante Salgado PE, Gallardo Palacios GJ, Guerrero-Gonzalez GA, Morales de la Cerda R, Ponce Olivera RM, Rossano Soriano F, Solis Tinoco E, Welsh Hernandez EC. Evidence-based treatment for gynoid lipodystrophy: A review of the recent literature. *J Cosmet Dermatol* 2018; 17: 977-983.
- 15) Bass LS, Kaminer MS. Insights Into the Pathophysiology of Cellulite: A Review. *Dermatol Surg Off Publ Am Soc Dermatol Surg AI* 2020; 46: 77-85.
- 16) Arora G, Patil A, Hooshanginezhad Z, Fritz K, Salavastru C, Kassir M, et al. Cellulite: Presentation and management. *J Cosmet Dermatol* 2022;21: 1393-1401.
- 17) Emanuele E, Minoretti P, Altabas K, Gaeta E, Altabas V. Adiponectin expression in subcutaneous adipose tissue is reduced in women with cellulite. *Int J Dermatol* 2011; 50: 412-416.
- 18) Rudolph C, Hladik C, Hamade H, Frank K, Kaminer MS, Hexsel D, Gotkin R, Sadick NS, Green JB, Cotofana S. Structural Gender Dimorphism and the Biomechanics of the Gluteal Subcutaneous Tissue: Implications for the Pathophysiology of Cellulite. *Plast Reconstr Surg* 2019; 143: 1077-1086.
- 19) Binazzi M, Grilli Cicilioni E. A proposito della cosiddetta cellulite e della dermato-pannicolopatia edemato-fibrosclerotica 1977; 31: 121-134.
- 20) Binazzi M, Papini M. Aspetti clinico-istomorfologici. In: *La cellulite*, Rome: Salus Internaz Ed 1983; 7-15.
- 21) Curri SB. Cellulite and Fatty Tissue Microcirculation. *Cosmetics & Toiletries* 1993; 108: 51-58.
- 22) Bartoletti C. *Medicina Estetica- Metodologie diagnostiche, preventive e correttive*. Ed Salus Internazionale 1998; 405-423.
- 23) Viero G, Savastano M, Maggiori S, Bartoletti CA. Le adiposità localizzate: aspetti di anatomia e fisiologia. In: *La Med Est* 1999; 165-168.
- 24) Rosenbaum M, Prieto V, Hellmer J, Boschmann M, Krueger J, Leibel RL, Ship AG. An exploratory investigation of the morphology and biochemistry of cellulite. *Plast Reconstr Surg* 1998; 101: 1934-1939.
- 25) Bartoletti CA, Gualtierotti R, Rota M, Tomaselli F, Circosta AM. Utilizzazione dell'estrato di centella asiatica nel trattamento della "cellulite" edematosa degli arti inferiori. In: *La Med Est* 1983; 97-103.



- 26) Rossi ABR, Vergnanini AL. Cellulite: a review. *J Eur Acad Dermatol Venereol JEADV* 2000; 14: 251-262.
- 27) Lotti T, Ghersetich I, Grappone C, Dini G. Proteoglycans in so-called cellulite. *Int J Dermatol* 1990; 29: 272-274.
- 28) Hexsel DM, Dal'forno T, Hexsel CL. A validated photonic cellulite severity scale. *J Eur Acad Dermatol Venereol* 2009; 23: 523-528.
- 29) de la Casa Almeida M, Suarez Serrano C, Rebollo Roldán J, Jiménez Rejano J j. Cellulite's aetiology: a review. *J Eur Acad Dermatol Venereol* 2013; 27: 273-278.
- 30) Querleux B, Cornillon C, Jolivet O, Bittoun J. Anatomy and physiology of subcutaneous adipose tissue by in vivo magnetic resonance imaging and spectroscopy: relationships with sex and presence of cellulite. *Skin Res Technol Off J Int Soc Bioeng Skin ISBS Int Soc Digit Imaging Skin ISDIS Int Soc Skin Imaging ISSI* 2002; 8: 118-124.
- 31) Scarano A, Petrini M, Sbarbati A, Amore R, Iorio EL, Marchetti M, Amuso D. Pilot study of histology aspect of cellulite in seventy patients who differ in BMI and cellulite grading. *J Cosmet Dermatol* 2021; 20: 4024-4031.
- 32) Scarano A, Amuso D, Amore M, Ferraro G, Iorio EI, Sbarbati A, Lorusso F, Petrini M. Carboxytherapy with oxygen propulsion treatment of cellulite is more effective in women not affected by periodontal disease. *J Biol Regul Homeost Agents* 2020; 34: 2337-2342.