

Intra-articular osteoid osteoma mimicking juvenile psoriatic dactylitis

Sirs,

Osteoid osteoma (OO) is a painful, benign bone tumour usually occurring in childhood and adolescence, particularly prevalent in the male population (1, 2).

Intra-articular OO (IAOO) accounts for about 12% of all OO and occurs mainly in the hip (3, 4). OO consists of a core called “nidus”, surrounded by a cortico-periosteal sclerotic reaction with low growth tendency (2, 3). Typically, OO presents with nightly pain, responsive to non-steroid anti-inflammatory drugs (NSAIDs) (1, 2, 4). Diagnosis is based on radiography, computed tomography (CT) and/or magnetic resonance imaging (MRI) (1).

A 10-year-old boy presented to the Paediatric Rheumatology Unit at the University of Chieti with a 3-month history of pain and swelling of the third finger of the right hand. The only relevant anamnestic data was a family history of psoriasis (father and paternal grandfather).

Physical examination showed swelling of the third right finger with a “sausage” appearance and pain on movements. Laboratory findings, including ESR, CRP, blood cell count, rheumatoid factor and antinuclear antibodies, were within normal range; HLAB27 was absent. Tuberculin skin test, pharyngeal swab and blood culture were negative.

Hand radiograph was negative for pathologies. Musculoskeletal ultrasound (MSUS) examination showed thickening of the joint capsule of the third proximal interphalangeal joint and a slight synovial effusion. Juvenile psoriatic dactylitis was suspected and MSUS-guided methylprednisolone injection was performed. Some weeks later, a nearly complete resolution of joint swelling and pain was observed.

Two months later, a relapse occurred with frequent pain exacerbations even during nighttime. The patient needed progressive increasing dosage of ibuprofen. The patient underwent a second intra-articular methylprednisolone injection and additional methotrexate was given 10 mg a week. Given the persistence of symptoms, a second radiography showed distal metaphyseal widening of the proximal phalanx with a central radiolucent zone.

CT and MRI confirmed the diagnosis of OO showing a 5 mm oval-shaped sequestrum along with an extensive area of intra-spongious bone oedema (Fig. 1). The patient underwent radiofrequency ablation of the tumour with complete clinical resolution.

IAOO, characterised by its position inside the insertion of the joint capsule, is a diagnostic challenge for several reasons. First of all, IAOO can manifest symptoms such as local heat, swelling and joint effusion

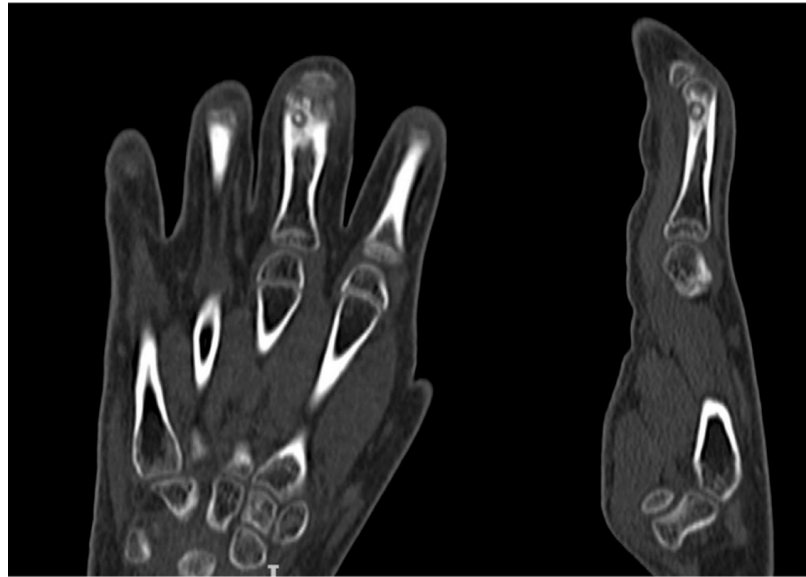


Fig. 1. CT images showing a small IAOO within the proximal phalanx of the third finger of the hand.

which are indistinguishable from arthritis (5). Diagnostic imaging in many cases have reported synovitis, narrowing of the joint space and other signs of arthritis. The underlying mechanism of synovitis is currently attributed to both the hypervascularity of the tumour and the production of prostaglandins, which are responsible for vasodilatation and oedema in the surrounding tissues (1, 5). For these reasons, IAOO is often misdiagnosed as juvenile arthritis or rheumatoid arthritis (5).

In addition, as occurred in our patient, IAOO is difficult to identify on radiographs due to the less marked cortico-periosteal reaction especially in the fingers where the lesion is smaller and the nidus is often missed. In all cases, CT is the best diagnostic modality when OO is suspected. The typical CT features of OO consist of a “vascular groove” or “CT vessel” sign representing enlarged vessels arising from the periosteum and irrigating the hyper-vascular nidus. Biopsy is recommended at the time of the treatment, especially for lesions with atypical presentation, even though it can be non-diagnostic in approximately one-third of cases (1).

Other factors contributing to the diagnostic delay in our patient were the family history for psoriasis and the “sausage digit” appearance. Indeed, dactylitis or “sausage digit” is a very suggestive symptom associated to psoriatic arthritis both in children and in adults: the differential diagnosis includes infectious disease, sickle cell disease, tuberculosis and IAOO (6).

In conclusion, OO is a benign bone tumour characterised by intermittent pain worsening at night and relieved by NSAIDs. IAOO should be considered in children with suspected juvenile idiopathic arthritis who do not respond to first-line therapies, particularly intra-articular corticosteroid injection.

L. BREDA, MD
G. SASSANO, MD
S. LA BELLA, MD
C. GENTILE, MD
L. SANSONE, MD
F. CHIARELLI, PhD

Department of Pediatrics,
University of Chieti-Pescara, Chieti, Italy.

Please address correspondence to:
Luciana Breda,
Servizio Regionale di Reumatologia
Pediatria, Clinica Pediatrica,
Via dei Vestini 5,
66100 Chieti (CH), Italy.

E-mail: luciana.bredach@gmail.com

Competing interests: none declared.

© Copyright CLINICAL AND
EXPERIMENTAL RHEUMATOLOGY 2022.

References

- CARNEIRO BC, DA CRUZ IAN, ORMON FILHO AG *et al.*: Osteoid osteoma: the great mimicker. *Insight Imaging* 2021; 12: 32.
- SWEE RG, MCLEOD RA, BEABOUT JW: Osteoid osteoma. *Radiology* 1979; 130: 117-23.
- JAFFE HL: Osteoid-osteoma. *Proc R Soc Med* 1953; 1007:1012.
- SZENDROI M, KOLLO K, ANTAL I, LAKATOS J, SZOKE G: Intraarticular osteoid osteoma: clinical features, imaging results, and comparison with extraarticular localization. *J Rheumatol* 2004; 31: 957-64.
- KAWAGUCHI Y, SATO C, HASEGAWA T, OKA S, KUWAHARA H, NORIMATZU H: Intraarticular osteoid osteoma associated with synovitis: a possible role of cyclooxygenase-2 expression by osteoblasts in the nidus. *Mod Pathol* 2000; 13: 1086-91.
- HAMARD A, BURNS R, MIQUEL A *et al.*: Dactylitis: a pictorial review of key symptoms. *Diagn Interv Imaging* 2020; 101: 193-207.