

# Pneumovesicoscopic management of bladder neoplasms in children: three case reports

Giovanni Cobellis,<sup>1,2</sup> Giovanni Torino,<sup>1</sup> Gabriele Lisi,<sup>3</sup> Michele Ilari,<sup>1</sup> Edoardo Bindi<sup>1,2</sup>

<sup>1</sup>Pediatric Surgical Unit Salesi Children's Hospital, Ancona; <sup>2</sup>Università Politecnica delle Marche, Ancona; <sup>3</sup>University of G. d'Annunzio Chieti and Pescara, Italy

## Abstract

Urothelial bladder neoplasms (UBN) are uncommon in children and are poorly understood. Their management is contentious, and there are currently no pediatric guidelines available, making it diffi-

cult to envision a surgical approach that can be defined as the gold standard for the treatment of these diseases. Pneumovesicoscopy, which has already been used to treat other urological diseases, could be a promising treatment option for selected cases of this group of pathologies. We present our experience with three pediatric UBN cases in which pneumovesicoscopy was used for complete excision of a perimeatal papilloma in two cases and biopsy of a botryoid rhabdomyosarcoma in one. The pneumovesicoscopic approach, in our experience, provided a viable alternative technique for the management of selected cases of UBN.

Correspondence: Edoardo Bindi, Pediatric Surgery Unit, Salesi Children's Hospital, Via F. Corridoni 11, 60123 Ancona, Italy.  
Tel.: +39.0715.962321.  
E-mail: edo.bindi88@hotmail.it

Key words: bladder neoplasms; laparoscopic intravesical approach; pneumovesicoscopy; pneumovesicum; pediatric surgery.

Contributions: EB, GC, conceptualization; EB, MI, GT, data curation; EB, GC, methodology; GC, supervision, and validation; GT, GL, visualization; EB, GC, original draft; EB, MI, review& editing. All authors have read and agreed to the published version of the manuscript.

Conflict of interest: the authors declare no potential conflict of interest, and all authors confirm accuracy.

Ethics approval and consent to participate: no ethical committee approval was required for this case report by the Department because this article does not contain any studies with human participants or animals. Informed consent was obtained from the patient included in this study.

Patient consent for publication: the patients' guardians gave their written consent to use their data for the publication of this case report and any accompanying images.

Availability of data and materials: all data underlying the findings are fully available.

Acknowledgments: This work is the result of the work of our Pediatric Surgery team, to whom great recognition is due.

Received: 12 January 2023.  
Accepted: 16 June 2023.

Publisher's note: all claims expressed in this article are solely those of the authors and do not necessarily represent those of their affiliated organizations, or those of the publisher, the editors and the reviewers. Any product that may be evaluated in this article or claim that may be made by its manufacturer is not guaranteed or endorsed by the publisher.

©Copyright: the Author(s), 2023  
Licensee PAGEPress, Italy  
La Pediatria Medica e Chirurgica 2023; 45:307  
doi:10.4081/pmc.2023.307

This work is licensed under a Creative Commons Attribution-NonCommercial 4.0 International License (CC BY-NC 4.0).

## Introduction

Bladder neoplasms (BN) occur in adults, related to smoking and occupational exposure. These diseases are rare in the pediatric age group, with an incidence of 0.1-0.4 in the first two decades.<sup>1</sup> Due to their rarity, BN in children are poorly known, their management is controversial and pediatric guidelines are currently unavailable.<sup>2</sup> This lack of information makes also difficult to think about a surgical approach that can be defined as the gold standard for the treatment of these diseases in children. In recent years, minimally invasive surgery has found more and more space in the treatment of pathologies in the pediatric field and the evolution of laparoscopic instruments has provided surgeons with the possibility of new effective approaches, with minimal impact on the patient.<sup>3</sup> Recently, the development of these techniques has also extended to the treatment of urological pathologies. In 2005, Yeung *et al.*<sup>4</sup> described a laparoscopic intravesical approach for ureteral reimplantation. The laparoscopic approach for intravesical surgery, known also by the term pneumovesicoscopy is a novel technique in which bladder insufflation of the gas is performed and trocars, under cystoscopic or direct camera vision, are inserted inside the bladder.<sup>5</sup> Pneumovesicoscopy has demonstrated excellent results and has been employed in various aspects of urological diseases beyond vesicoureteral reflux (VUR) management. Recently, in the pediatric population, many of the intravesical procedures such as ureteral reimplantation, bladder neck surgery, removal of bladder stones, ureterocele or bladder foreign bodies, and diverticulectomy are performed utilizing pneumovesicoscopy.<sup>6</sup> In this study, we describe the feasibility of pneumovesicoscopic treatment of two cases of parametatal papilloma and biopsy of a botryoid rhabdomyosarcoma by creating a pneumovesicum using CO<sub>2</sub> insufflation of the bladder in three children.

## Surgical technique

Patients were placed in the lithotomy position with abducted thighs and the pelvis tilted with a cushion placed below the buttocks. Standard cystoscopy (Pediatric Storz Cystoscope) recogni-

tion was performed to verify the condition of the urethra and the ureteric orifices. The bladder was then filled at its maximum capacity, and a first 5 mm balloned trocar was introduced for a 0°\30° telescope at the bladder dome; two lateral 5 mm trocars were then inserted under visual control into the bladder at the level of the mid-clavicular line. With the use of 5 mm trocars, with the bladder filled, the bladder wall was suspended to the anterior abdominal wall by two percutaneous transfixing sutures placed under cystoscopic control. This allowed keeping the bladder wall close to the abdominal wall, to stabilize the bladder and facilitate the introduction of the trocars. A urethral catheter was then left in place removing the cystoscope and the bladder was filled with CO<sub>2</sub> at a pressure of 10-12 mmHg cm H<sub>2</sub>O and a volume of 2L/min via the dome port.

## Case Reports

### Patient 1

A 15-year-old boy suffered from glandular hypospadias for which he underwent meatoplasty. In the postoperative period, the patient presented a meatal stenosis, for which we performed a urethral dilatation and subsequent cystoscopic control. During this examination, the presence of a bladder papilloma located on the right ureteral meatus was detected. Resection of the neoplasm was not performed by cystoscopy because we considered the risk of ureteral damage. A biopsy was performed, and a diagnosis of urothelial papilloma was made. Two months later the patient underwent surgical excision of the papilloma by pneumovesicoscopy. The procedure started as previously described. After its identification near the right ureteral meatus, a wide-margin resection of the papilloma was performed. The histological results confirmed the diagnosis of urothelial papilloma. Postoperative recovery was uneventful, the urethral catheter was removed on the second postoperative day and the patient was discharged home on the same postoperative day.

Follow-up was performed with cystourethroscopy and ultrasonography. Cystourethroscopy examination 3 months after surgery and the ultrasonography 16 months after surgery didn't show pathological findings.

### Patient 2

A 7-years old-boy performed an abdominal ultrasound following a traumatic fall, during which the presence of a lesion (1x0.6 cm) in the bladder was detected. The patient underwent a cystoscopy, which showed a papillary lesion on the left ureteral meatus. A biopsy was performed, with which a diagnosis of urothelial papilloma was made. One month after, the patient underwent pneumovesicoscopic excision of the tumor (Figure 1). Surgical procedure was the same as the previous patient. The postoperative period was uneventful. The catheter was removed on day 2 after surgery. The patient was able to void adequately and was discharged. A histological examination confirmed the diagnosis of urothelial papilloma. Currently, the patient performs periodic ultrasound examinations in our department and does not show signs of recurrence.

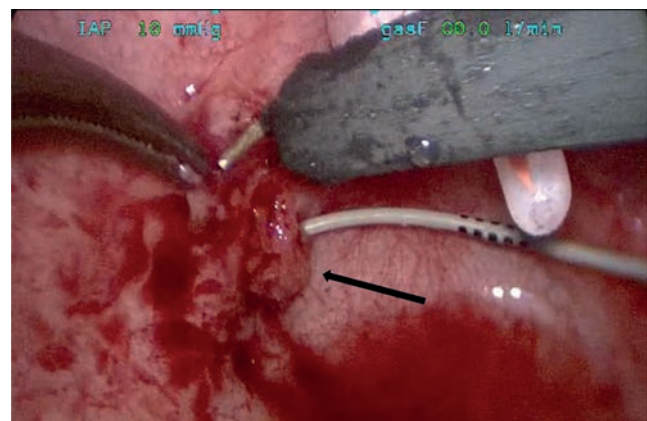
### Patient 3

A 19-month-old boy, presented to our hospital for macroscopic haematuria and dysuria. A pelvic ultrasound scan revealed a mass in the bladder. An abdominal MRI scan was performed showing an intravesical enhancing soft tissue mass (35x30x35 mm) arising from the prostatic urethra. A thoracic CT scan and bone scan showed no evidence of disease. Because of the urethral obstruction

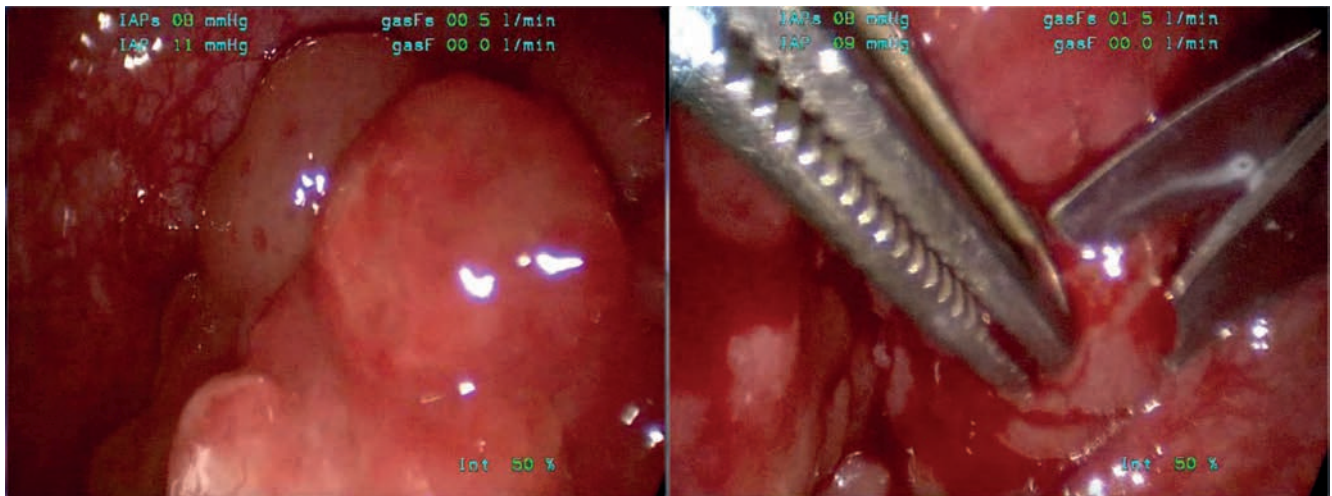
and the difficulty to pass the cystoscope the patient underwent a surgical biopsy of the lesion by pneumovesicoscopy using the same technique previously described (Figure 2). The histological examination confirmed the diagnosis of botryoid rhabdomyosarcoma (RMS). After 8 months of chemotherapy and a reduction in the size of the tumor, he underwent partial cystectomy (left side) and partial prostatectomy with bilateral ureteral reimplantation, posterior bladder wall repair, and neck reconstruction. Follow-up was performed with thoracic X-ray, abdominal MRI scan, and cystoscopy every six months. Three years after surgery the patient showed no evidence of disease.

## Discussion

In pediatric urology, many pathologies requiring surgical treatment are malformations. Vesicoureteral reflux is a good example in this sense, as it represents a pathology at the base of which there are genetic and malformation elements, and which, in the most serious cases, must be surgically corrected.<sup>7</sup> Ureteral reimplantation was the surgery that has evolved most with the advent of laparoscopy first and then of robot-assisted surgery, allowing it to be carried out even in low-weight patients.<sup>8</sup> The same operation was the first to be performed with pneumovesicoscopy which is a laparoscopic intravesical technique<sup>4</sup> in which insufflation of the gas is performed and trocars are inserted inside the bladder under direct vision. The bladder is a naturally occurring cavity that is easily distensible and is therefore ideally suited for providing surgical access after gas insufflation and to offering an alternative to open cystotomy or cystoscopy. Many studies have shown that pneumovesicoscopy has potential benefits over traditional techniques, including improving cosmesis, reducing postoperative pain and postoperative ileus, fewer wound complications, and shorter hospital stays.<sup>9,10</sup> However, the application of this technique requires considerable laparoscopic skill and a good learning curve. Working into the bladder, although it is easily distensible, exposes some difficulties in creating and working in a limited space. Anyway, this technique continued to find applications and, since 2005, many kinds of surgical interventions were performed in children with pneumovesicoscopy, such as ureteral reimplantation for vesicoureteral reflux, and other indications.<sup>12</sup> Papilloma is a benign exophytic lesion characterized by papillary fronds classified into urothelial bladder neoplasms (UBN). A recent study by Berrettini *et al.*<sup>2</sup> reported a



**Figure 1. Pneumovesicoscopic treatment of a papilloma located on the left ureteral meatus.**



**Figure 2.** Pneumovesicoscopic biopsy of a botryoid rhabdomyosarcoma arising from the prostatic urethra.

cystoscopic resection of UBN performed in 18 patients. The study, consistent with previous reports, showed that all the tumors resected were non-muscle invasive and no recurrence was reportedly in five years enabling a conservative surgical treatment. In this study, we reported the application of pneumovesicoscopy for the treatment of papilloma located on the ureteral meatus, which is particularly difficult to remove using the endoscopic approach. Pneumovesicoscopy in the treatment of these diseases, has several theoretical advantages, including radical removal of the entire specimen and excellent visualization of the bladder.<sup>14</sup> In our limited experience, perinatal papilloma excision was performed without intraoperative complications and recurrences.

RMS is the most common malignancy of the bladder in children. In recent decades, the management of these tumors has shifted away from immediate radical extirpative surgery to more conservative therapy, which combines biopsy, bladder-sparing treatment, chemotherapy, and/or radiotherapy. Initial biopsy of bladder RMS is mainly performed endoscopically but the amount of tissue obtained is small and obtaining adequate tissue samples is critical in the diagnosis of pediatric BT. Patient 3 of our study, affected by bladder RMS, underwent urethroscopy showing an extending tumor which did not permit them to have good vision and to perform an adequate biopsy. Therefore, pneumovesicoscopy enabling to obtain voluminous specimens was performed. The patient was later submitted to open partial cystectomy (left side) and partial prostatectomy. At 5 years of oncological follow-up, the patient is alive.

## Conclusions

Pediatric guidelines about intravesical mass management are currently lacking.

The pneumovesicoscopic approach provides a valid alternative technique for a safer perimeatal vesical urothelial papilloma treatment and for mass biopsies ensuring voluminous specimens of tumoral tissue that is critical in the diagnosis of pediatric intravesical tumors although it is more invasive compared to cystoscopy pneumovesicoscopy permits a safer and effective approach in very selected cases intravesical vision and a greater precision because of the use of two working instruments. We think that pneumovesicoscopy should be in the surgical armamentarium of the pediatric

surgeon dedicated to minimally invasive surgery. The main limitations in acquiring this technique are a longer learning curve and the rarity of cases to be treated surgically. Therefore, there is a need to centralize all patients with this type of pathology in pediatric centers with particularly experienced pediatric urologists.

## References

1. Alanee S, Shukla AR. Bladder malignancies in children aged <18 years: results from the surveillance, epidemiology, and results database. *BJU Int* 2009;106:557e60.
2. Berrettini A, Castagnetti M, Salerno A, et al. Bladder urothelial neoplasms in pediatric age: experience at three tertiary centers. *J Pediatr Urol* 2015;11:26.e1-5.
3. Molinaro F, Krasniqi P, Scolletta S, et al. Considerations regarding pain management and anesthesiological aspects in pediatric patients undergoing minimally invasive surgery: robotic vs laparoscopic-thoracoscopic approach. *J Robot Surg* 2020;14:423-430.
4. Yeung CK, Sihoe JD, Borzi PA. Endoscopic cross-trigonal ureteral reimplantation under carbon dioxide bladder insufflation: A novel technique. *J Endourol* 2005;19:295-9.
5. Chung PH, Tang DY, Wong KK, et al. Comparing open and pneumovesical approach for ureteric reimplantation in pediatric patients--a preliminary review. *J Pediatr Surg* 2008;43:2246-9.
6. Symons S, Kurien A, Desai M. Laparoscopic ureteral reimplantation: A single center experience and literature review. *J Endourol* 2009;23:274.
7. Nino F, Ilari M, Noviello C, et al. Genetics of vesicoureteral reflux. *Curr Genomics* 2016;17:70-9.
8. Molinaro F, Angotti R, Bindi E, et al. Low weight child: can it be considered a limit of robotic surgery? Experience of two centers. *J Laparoendosc Adv Surg Tech A* 2019;29:698-702.
9. Soh S, Kobori Y, Shin T, et al. Transvesicoscopic ureteral reimplantation: Politano-Leadbetter versus Cohen technique. *Int J Urol* 2015;22:394-9.
10. Hong CH, Kim JH, Jung HJ, et al. Single-surgeon experience with transvesicoscopic ureteral reimplantation in children with vesicoureteral reflux. *Urology* 2011;77:1465-9.

11. Xiang B, Liu JX, Sung HB, et al. The effect of CO2 pneumovesicum on the upper urinary tract. *J Pediatr Surg* 2010;45: 1863-7.
12. Przudzik M, Borowik M, Łesiów R, et al. Transvesicallaparoscopic single-site surgery (T-LESS) to remove an unusual foreign body from the bladder. *Cent European J Urol* 2016; 69:312.
13. Xylinas E, Rink M, Cha EK, et al. Impact of distal ureter management on oncologic outcomes following radical nephroureterectomy for upper tract urothelial carcinoma. *Eur Urol* 2014;65:210-7.
14. Phé V, Cussenot O, Bitker MO, Rouprêt M. Does the surgical technique for management of the distal ureter influence the outcome after nephroureterectomy? *BJU Int* 2011;108:130-8.

Non-commercial use only