Oral Oncology EXTRA (2005) 41, 216–218

ELSEVIER

ORAL ONCOLOGY EXTRA

http://intl.elsevierhealth.com/journal/ooex

CASE REPORT

Cartilaginous choristoma of the gingiva

Vittoria Perrotti [a], Massimiliano Fioroni [b], Corrado Rubini [c], Adriano Piattelli [d,*]

[a] *Dental School, University of Chieti-Pescara, Italy*
[b] *Dental School, University of Ancona, Italy*
[c] *Institute of Pathologic Anatomy and Histopathology, University of Ancona, Italy*
[d] *Dental School, University of Chieti-Pescara, Via F. Sciucchi 63, 66100 Chieti, Italy*

Received 7 June 2005; accepted 7 June 2005

KEYWORDS
Cartilaginous choristoma;
Hamartomatous lesions of the gingiva;
Osteocartilaginous choristoma

Summary Cartilaginous choristomas of the gingiva are rare lesions. These lesions can derive from metaplastic osseous or chondroid formation, stimulation of cartilaginous embryonic rests, pluripotent cells, development of a mixed tumor with predominance of osseous tissue or cartilage, other neoplasms and teratomas with preponderance of bone and cartilage. A 60-year-old male was referred for diagnostic evaluation of a nodule involving the adherent gingiva of the maxillary premolar region, present for about 6 months and extending into the vestibular mucosa. Microscopically, the overlying mucosa was acanthotic; the submucosal mass was composed by mature cartilage. Neither nuclear atypia nor mitoses were evident. In some areas, the chondrocytes appeared to be surrounded by dense connective tissue (pseudo-capsule). The diagnosis was cartilaginous choristoma. There was no evidence of recurrence at 2 years follow-up. The treatment of oral choristomas consists of a simple excision.

Introduction

The complex embryology of the head and neck region renders it prone to developmental malformations.[1] The term ''choristoma'' refers to a hamartomatous tumor-like lesion composed of normal tissue in an abnormal location.[2–4,21] These lesions may be composed of different types of tissues whose only similarity is their close association in fetal development,[5] and are designated according to the tissues from which they derive (e.g. salivary gland, cartilage, bone, lingual thyroid, glia, gastric mucosa).[3,4] There is some debate concerning whether choristomas are developmental, neoplastic or reparative in nature.[3] Cartilaginous choristomas of the gingiva are rare lesions.[4–11]

* Corresponding author. Tel.: +11 39 0871 355 4083; fax: +11 39 0871 355 4076.
E-mail address: apiattelli@unich.it (A. Piattelli).

1741-9409/$ - see front matter
doi:10.1016/j.ooe.2005.06.003

These lesions may derive from inflammatory stimulation leading to:

- metaplastic osseous or chondroid formation;
- stimulation of cartilaginous embryonic rests;
- pluripotent cells;
- development of a mixed tumor with predominance of osseous tissue or cartilage;
- other neoplasms and teratomas with preponderance of bone and cartilage.[3,4,11]

An additional case of a cartilaginous choristoma of the gingiva is reported.

Case description and results

A 60-year-old male was referred for diagnostic evaluation of a nodule involving the adherent gingiva of the maxillary premolar region, present for about 6 months and extending into the vestibular mucosa (Fig. 1). The lesion was 1 cm in diameter and caused problems during chewing but was otherwise asymptomatic. On palpation, the lesion was of hard consistency. Radiologically, neither erosion of the underlying bone nor endodontic and periodontal lesions were present. Excisional biopsy of the lesion was performed with the patient under local anesthesia, and the tissue (1.2×1 cm) was sent for histological evaluation. When removed, the lesion presented in the central area a nodule of about 0.5 cm of diameter with a reddish cut surface. Microscopically, the overlying mucosa was acanthotic; the submucosal mass was composed by mature cartilage. Neither nuclear atypia nor mitoses were evident (Fig. 2). In some areas, the chondrocytes appeared to be surrounded by dense connective tissue (pseudo-capsule) (Fig. 3). The surrounding connective tissue was not infiltrated and presented a high vessels density. The diagnosis was cartilaginous choristoma. There was no evidence of recurrence at 2 years follow-up.

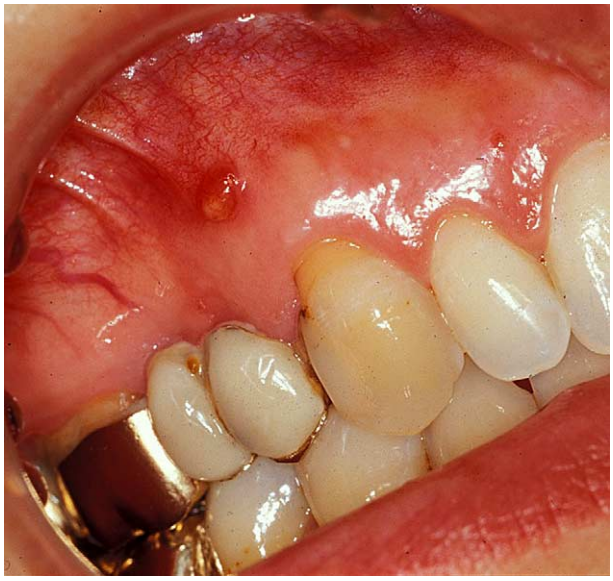

Figure 1 Initial presentation, cartilaginous choristoma. A slight elevation is evident in the adherent gingiva.

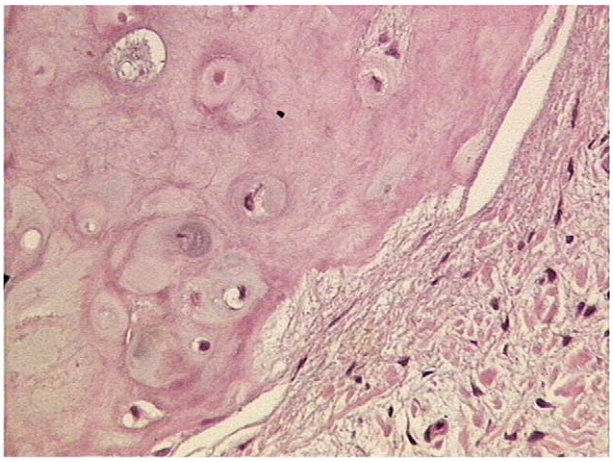

Figure 2 The lesion is composed of mature cartilaginous with areas of dense acellular matrix. Nuclear atypia and mitotic figures are absent. Hematoxylin & Eosin ×250.

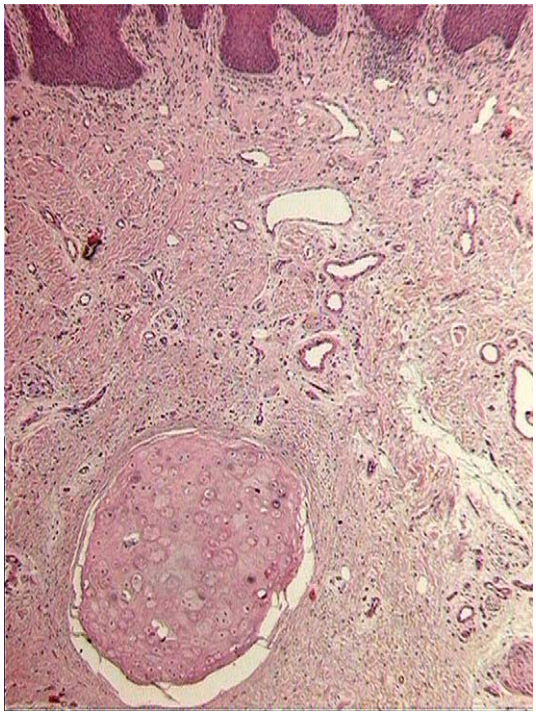

Figure 3 Presence of cartilaginous tissue in the submucosal connective tissue. Hematoxylin & Eosin ×160.

Discussion

Many authors support embryonic rests as an origin of gingival choristomas.[5] It is also believed that pluripotent mesenchymal cells differentiate into osteocytes or chondrocytes.[5] Metaplastic ossification can also result from trauma or chronic inflammation.[4,12] Oral choristomas were described for the first time in 1890 by Berry,[13] and the majority of lesions reported to date are located on the tongue: these are more than 60 cases of bony, cartilaginous or mixed lesions of the tongue: 20 cases of cartilaginous lesions, 36 cases of bony lesions and 6 cases of mixed lesions.[14,15] In the present case, however, lesion is located in a rare site; only few cases have been reported.[2,16] Cartilaginous choristomas usually arise in adults as asymptomatic submucosal mass in the distal extremities and rarely in the soft tissue of oral cavity, covered by normal-appearing mucosa.[4,7–9] Histologically, there may be an admixture of mature adipocytes or myxoid tissue plus islands of cartilage within a well-defined capsule.[7] Although a majority of the cases represent pure cartilaginous proliferations, some lipocartilaginous and osteocartilaginous lesions have also been reported.[4] Cartilage-containing lesions of the oral soft tissues must be differentiated from pleomorphic adenoma with a significant chondroid component, ectomesenchymal chondromyxoid tumors, malignant cartilaginous tumors[8,15,17] and cartilaginous metaplasia, which usually occurs in the soft tissue beneath ill-fitting dentures.[18] The treatment of oral choristomas is simple excision.[15,19–23] The lesions do not recur.

Acknowledgments

This work was partially supported by the National Research Council (C.N.R.), Rome, Italy and by the Ministry of the University, Research, Science and Technology (M.U.R.S.T.), Rome, Italy, and by AROD (Research Association for Dentistry and Dermatology), Chieti, Italy.

References

1. Odell EW, Morgan PR. *Biopsy pathology of the oral tissues*. London: Chapman and Hall Medical; 1998, p. 140.
2. Seckin T, Unal T, Bir Y. Osteocartilaginous choristoma of the gingiva. *Dent Update* 1996;**23**:248–9.
3. Psomopoulou M, Antoniades K. Submental osseous choristoma: a case report. *J Oral Maxillofac Surg* 1998;**56**:666–7.
4. Mosqueda-Taylor A, Gonzalez-Guevara M, De La Piedra-Garza JM, Diaz-Franco MA, Toscano-Garzia I, Cruz-Leon A. Cartilaginous choristomas of the tongue: review of the literature and report of three cases. *J Oral Pathol Med* 1998;**27**:283–6.
5. Chou L, Hansen LS, Daniels TE. Choristoma of the oral cavity a review. *Oral Surg Oral Med Oral Pathol* 1991;**72**:584–93.
6. West CB, Atkins JS. Choristomas of the intraoral soft tissues. *Otolaryngol Head Neck Surg* 1988;**99**:528–30.
7. Trowbridge M, McCabe B, Reznicek M. Cartilaginous choristoma of the tongue. A case report and literature review. *Arch Otolaryngol Head Neck Surg* 1989;**115**:627–9.
8. Blum MR, Danford M, Speight PM. Soft tissue chondroma of the cheek. *J Oral Pathol Med* 1993;**22**:334–6.
9. Gardner Dg, Paterson JC. Chondroma or metaplastic chondrosis of the soft palate. *Oral Surg Oral Med Oral Pathol* 1968;**26**:601–4.
10. Matsushita K, Tahara M, Sato H, Nakamura E, Fujiwara T. Cartilaginous choristoma deep in the upper midline oral vestibule. *Br J Oral Maxillofac Surg* 2004;**42**:436–8.
11. Weitzner S, Stimson PG, McClendon JL. Cartilaginous choristoma of the tongue. *J Oral Maxillofac Surg* 1987;**45**: 185–7.
12. Ling KC. Chondroma of the tongue. *J Oral Maxillofac Surg* 1986;**44**:156–8.
13. Berry J. Fibro-chondroma of tongue. *Trans Pathol Soc Lond* 1990;**41**:81–2.
14. Shimono M, Tsuji T, Iguchi Y, Yamamura T, Ogasawara M, Honda T, et al. Lingual osseous choristoma. Report of two cases. *Int J Oral Surg* 1984;**13**:355–9.
15. Van der Wal N, Van der Waal I. Osteoma or chondroma of the tongue: a clinical and postmortem study. *Int J Oral Surg* 1987;**16**:713–7.
16. Unal T, Erturk S. Cartilaginous choristoma of the gingiva. Report of two cases; review of the literature of both gingival choristomas and intraoral chondromas. *Ann Dent* 1994;**53**:19–27.
17. Van der Wal JE, Van der Waal I. Ectomesenchymal chondromyxoid tumor of the anterior tongue. Report of a case. *J Oral Pathol Med* 1996;**25**:456–8.
18. Cutright DE. Osseous and chondromatous metaplasia caused by dentures. *Oral Surg Oral Med Oral Pathol* 1972;**34**: 625–33.
19. Sultani FA, Krolls SO, Heckler FR. Cartilaginous choristoma of buccal mucosa: a case report. *Br J Plast Surg* 1983;**36**: 395–7.
20. Weitzner S. Osseous choristoma of the tongue. *South Med J* 1986;**79**:69–70.
21. Tohill MJ, Green JG, Cohen DM. Intraoral osseous and cartilaginous choristomas: report of three cases and review of the literature. *Oral Surg Oral Med Oral Pathol* 1987;**63**: 506–10.
22. Malis DJ, Breisch EA, Billman GF. Cartilaginous choristoma of the nasopharynx. *Clin Anat* 2000;**13**:263–6.
23. Toida M, Sugiyama T, Kato Y. Cartilaginous choristoma of the tongue. *J Oral Maxillofac Surg* 2003;**61**:393–6.