PREFERRED COLLAGEN FIBER ORIENTATION IN HUMAN PERI-IMPLANT BONE AFTER A SHORT- AND LONG-TERM LOADING PERIOD: A CASE REPORT

Tonino Traini, DDS, PhD
Gabriele Pecora, MD, DDS
Giovanna Iezzi, DDS, PhD
Adriano Piattelli, MD, DDS

KEY WORDS

Immediate loading
Birefringence
Circularly polarized light
Collagen fiber orientation
Dental implants

Gabriele Pecora, MD, DDS, *is in private practice in Rome, Italy.*

Tonino Traini, DDS, PhD, *is a researcher,* ***Giovanna Iezzi, DDS, PhD,*** *is a research fellow, and* ***Adriano Piattelli, MD, DDS,*** *is a professor of Oral Pathology and Medicine in the Dental School, University of Chieti-Pescara, Chieti, Italy. Address correspondence to Prof Adriano Piattelli, Via F. Schiucchi 63, 66100 Chieti, Italy (e-mail: apiattelli@unich.it).*

Immediate loading of dental implants offers treatment cost advantages to patients and avoids the functional and psychological problems caused by the wearing of provisional dentures. There is evidence that the amount of transverse collagen fiber orientation in bone is influenced by mechanical stresses and strains. Two osseointegrated dental implants in humans were used in the present study. Two implants inserted in the maxilla were analyzed: 1 short-term implant (implant A) immediately loaded and retrieved after 4 months of loading and 1 long-term implant (implant B) immediately loaded and retrieved after 12 years. We hypothesized that the bone functional strain caused by immediate loading correlated well with the collagen fiber organization occurring after both short- and long-term functional healing. Circularly polarized light (CPL) was used to assess the area fraction extension related to the transverse collagen fiber orientation in the bone matrix. After evaluating a total of 68 digitized images taken at ×50 magnification, birefringence measurements were performed all around the implant surfaces by using 2 central sections from each implant. The results showed that the bone-to-implant contact (BIC) percentage for implant A was 67.9% ± 9.5% (mean ± SD), whereas the BIC percentage for implant B was 74.6% ± 11.2% (mean ± SD). The area fraction extension was 2.7% ± 1.4 % (mean ± SD) for implant A, whereas the area fraction extension was 4.7% ± 1.2% (mean ± SD) for implant B. The CPL measurements of the birefringence for transverse collagen fibers of implant A vs implant B indicated that the bone fraction area difference was not high. In the bone near both dental implants, no differences were found in the amount of transverse collagen fibers. Immediate loading seemed to determine and maintain the collagen fiber's orientation over a long period.

INTRODUCTION

The immediate loading concept provides several advantages, among them a 1-stage surgical approach. Additionally, the implants are splinted together so that the patient does not need to wear a removable restoration during the transitional period. Several authors have published clinical reports with 95% to 100% success rates with immediate loading.[1–18] Piattelli et al[6] evaluated bone-titanium interface in early loaded and unloaded implants in monkeys and detected no statistically significant differences in the bone-to-implant contact (BIC) percentage after an 8-month loading period. They also noted fewer marrow spaces and more compact bone in the loaded implants. In later studies,[7,8] it was demonstrated greater bone contact in immediately loaded implants after 9 months without fibrous tissue at the bone-implant interface and almost twice as much direct bone contact at the interface of loaded implants after 15 months. Furthermore, the early loaded implants showed thicker lamellar and cortical bone than did unloaded ones, suggesting that early occlusal loading may enhance bone remodeling and density. Romanos et al[9] reported no statistical differences between immediately loaded and delayed loaded implants. We have previously shown that the collagen fiber organization depends on both loading types and regimens.[10,11]

According to classical histology, bone tissue may be classified in relation to the spatial orientation of collagen fibers. Two different types of bone have been recognized: woven-fibered bone and parallel-fibered bone (lamellar or nonlamellar). Woven bone has a poorly structured matrix that is formed rapidly in response to wounding or hypertrophic adaptation. The slower the appositional rate, the more highly organized the matrix and greater strength of the bone; the degree of mineralization is also related to the stiffness and strength of the bone. Both the role of bone cells and the appearance of lamellar bone have never been explained in a satisfactory manner. The osteotomy for implant placement produces a regional accelerating phenomenon that exists throughout the healing process and accelerates the angiogenesis, callus formation, and remodeling and modeling phases.[12] Initially, a soft fracture callus forms with a conspicuous neoangiogenesis supporting the precursor cells. Osteoblasts, forming woven bone, fill the gaps between the implant surface and existing bone. After the callus mineralizes, remodeling basic multicellular units (BMUs) begin to replace it with packets of new lamellar bone, usually in relation to the strain direction.[13,14]

The aim of this study was to compare the BIC percentage and the collagen fiber organization in 2 immediately loaded implants, 1 retrieved after 4 months and 1 retrieved after 12 years of function.

METHODS

The short-term loaded implant (implant A) was retrieved from the upper left maxilla of a 35-year-old female patient who had received 3 permanent implants (LaserLok, Biolok International, Deerfield, Fla) and 3 temporary implants (Silhouette LaserLok, Biolok International). The temporary implants were loaded immediately with a provisional acrylic restoration. Before retrieval, all temporary implants appeared to have become clinically osseointegrated, and there was no mobility. After 4 months, the implants were retrieved during the second surgical stage of the permanent implants with a 5-mm trephine bur. During retrieval, detachment of the bone from the implant surface occurred in 2 of the implants, so only 1 was used for the evaluation.

The long-term loaded implant (implant B) was retrieved from a 42-year-old female patient, a heavy smoker, who came to our department with a complaint of advanced periodontal disease. In the maxilla there was a single standing screw implant (Figure 1). This implant had been inserted 12 years previously and had been loaded the same day with a resin crown in occlusal contact; after 3 months, a definitive prosthesis had been inserted. The implant functioned well for all 12 years. The peri-implant soft tissues appeared to be healthy, and no pain was present upon percussion. Because the patient wanted to have an implant-supported overdenture in the maxilla, it was decided to retrieve the implant with a 4-mm trephine bur. Upon removal, mineralized tissue appeared to be attached to the implant surface.

The implants were immediately immersed in 10% buffered formalin to be processed for histology. Undecalcified cut and ground sections were prepared by using the Precise 1 Automated System (Assing, Rome, Italy). Two central sections were taken from each sample. Sections were ground to a final thickness of 100 ± 5 μm (mean ± SD), mounted on glass microscope slides, and observed under circularly polarized light (CPL) at ×50 magnification with an Axio-

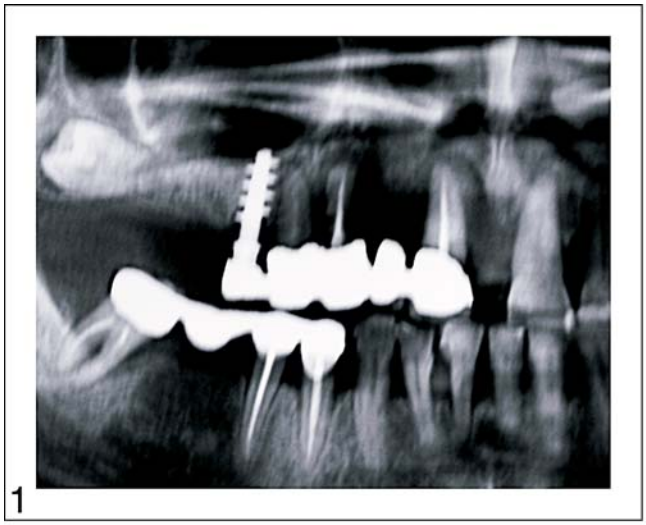

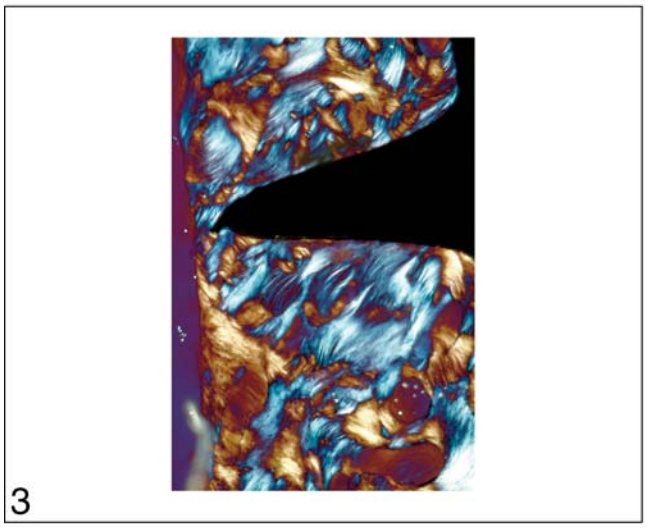



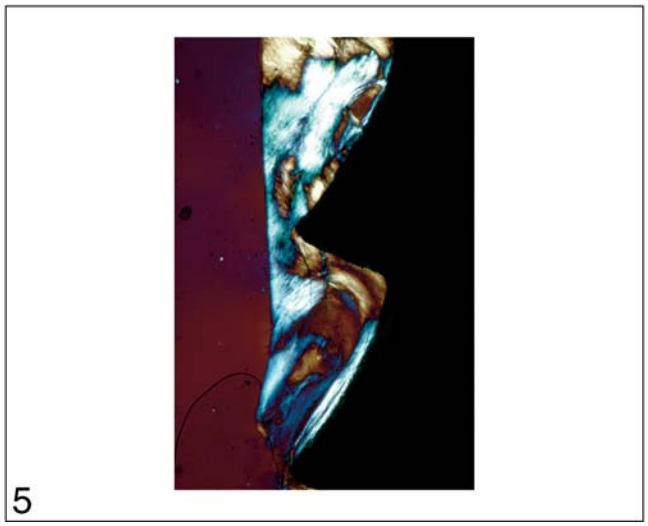

FIGURES 1–5. FIGURE 1. Panoramic x-ray: An immediately loaded screw implant has been loaded for a 12 year period. FIGURE 2. Implant B. The images detected under circularly polarized list (CPL) show the transverse collagen fibers in white (magnification ×50). FIGURE 3. Implant B. Transverse collagen fibers in white near an implant thread, under CPL light (magnification ×100). FIGURE 4. Implant A. The images detected under CPL light show transverse collagen fibers in white (magnification ×50). FIGURE 5. Implant A. Transverse collagen fibers in white near the implant threads, under CPL light (magnification ×50).

lab microscope (Zeiss Inc, Jena, Germany). The microscope was connected to a digital camera (FinePix S2 Pro, Fuji Co Ltd, Tokyo, Japan) interfaced to a monitor and PC (Intel Pentium IV HT, Santa Clara, Calif). This optical system was used with a software package with image-capturing capabilities (Image-Pro Plus 4.5, Media Cybernetics Inc, Silver Springs, Md; Immagini & Computer Snc, Milano, Italy).

Circularly polarized light was generated by combining a quarter-wave pulse and a polarizing filter. One circular polarizing filter was positioned directly underneath the glass below the specimen, and the other was positioned on the superior end of the objective above the specimen. Images from this process were saved as high-resolution 24-bit JPEGs.

To create a map reconstruction, 17 digital images were taken for each implant at ×50 magnification and again saved as high-resolution 24-bit JPEGs. Collagen fiber orientation measurements were then taken and analyzed by using image-managing software (Adobe Photoshop 8.1, Adobe Systems Inc, San Jose, Calif). Before measuring, each image was converted to greyscale, where each cell was assigned a pixel value between 0 (black) and 225 (white). The method used for quantification of the birefringence involved the semiquantitative digital densitometry of the black areas related to the transverse collagen fiber by using software image analysis (Sigma Scan Pro 5, SPSS Inc, Chicago, Ill). To ensure accuracy, we calibrated the software at each experimental stage. The Pythagorean theorem was used for distance calibration, which calculated the number of pixels between 2 selected points. Linear remapping of the pixel values was used to calibrate the density of the images.

RESULTS

The BIC percentage in implant A was 67.9% ± 9.5% (mean ± SD), whereas the BIC percentage in implant B was 74.6% ± 11.2% (mean ± SD). Under CPL, the area fraction extension of the peri-implant bone relating to the transverse collagen fibers of both implants appeared in yellow-orange (Figures 2 through 5). In implant A, the area fraction extension was 2.7% ± 1.4% (mean ± SD), whereas the area fraction extension in implant B was 4.7% ± 1.2% (mean ± SD) (Figure 4). The CPL measurements of the birefringence for the transverse collagen fibers of both implants showed a slight difference.

DISCUSSION

Until now, most of the histological analyses in implant dentistry were based on the BIC percentage without also considering bone matrix organization. However, the mechanical properties of the bone and its spatial arrangement are considered to be very important factors; long-term survival of the osseointegrated implants is dependent on the ability of bone to effectively function under occlusal loads rather than the quality of the peri-implant tissue. The different loading environment affects the collagen orientation: bone under compression shows oblique- or transversely oriented collagen, whereas bone under tension shows longitudinally oriented collagen.[16] The observation that immediate loading is able to orient the collagen fibers during early osseointegration and that this orientation is also present around an osseointegrated implant after 12 years of function is certainly of interest. To maintain this orientation throughout a long-term period, BMUs must have been influenced during the remodeling processes.

These findings must be considered alongside the limitations of this study, such as the small sample size and differences between the implant surfaces and morphologies. However, it should be acknowledged that human samples are very rare and difficult to ethically obtain for prospective studies. The differences between implant surfaces and morphologies are important for the stability of implants under load and are also of major importance for the bone-forming osteoblast to promote matrix mineralization in the vicinity of the implant. When considered with early or immediate implant loading, accelerated bone healing around implants should result in an interfacial matrix with a composition, structure, and biomechanical profile characteristic of normal bone. The particular mechanical environment surrounding implants is dependent on the specific forces imposed as well as the interaction between bone and surface. Certain implant designs may promote osseointegration by providing a favorable local mechanical environment for bone formation.[17,18]

Despite the limitations of the present study, the results point out that immediate loading was able to orient and maintain the orientation of collagen fibers from the mineralized bone matrix near dental implants.

ACKNOWLEDGMENTS

This work was partially supported by the National Research Council (Rome, Italy); by the

Ministry of Education, University, and Research (Rome, Italy); and by the Research Association for Dentistry and Dermatology (Chieti, Italy).

References

1. Scortecci G. Anchored disk-design implants without bone augmentation in moderately to severely resorbed edentulous maxillae. *J Oral Implantol.* 1999; 25:37–79.

2. Randow R, Ericsson I, Nilner K, Petersson A, Glantz PO. Immediate functional loading of Branemark dental implants. An 18-month clinical follow-up study. *Clin Oral Implants Res.* 1999;10:8–15.

3. Horiuchi K, Uchida H, Yamamoto K, Sugimura M. Immediate loading of Branemark system implants following placement in edentulous patients: a clinical report. *Int J Oral Maxillofac Implants.* 2000;15:824–830.

4. Ganeles J, Rosenberg MM, Rolt RL, Rechman LH. Immediate loading of implants with fixed restorations in the completely edentulous mandible: report of 27 patients from a private practice. *Int J Oral Maxillofac Implants.* 2001;16:418–426.

5. Jaffin RA, Kumar A, Berman CL. Immediate loading of implants in partially and fully edentulous jaws: a series of 27 case reports. *J Periodontol.* 2000; 71:833–838.

6. Piattelli A, Corigliano M, Scarano A, Quranta M. Bone reactions to early occlusal loading of two-stage titanium plasma-sprayed implants: a pilot study in monkeys. *Int Periodontics Restor Dent.* 1997;17:162–169.

7. Piattelli A, Corigliano M, Scarano A, Costigliola G, Paolantonio M. Immediate loading of titanium plasma-sprayed implants: an histologic analysis in monkeys. *J Periodontol.* 1998;69:321–327.

8. Piattelli A, Ruggeri A, Franchi M, Romasio N, Trisi P. An histologic and histomorphic-metric study of bone reactions to unloaded and loaded non-submerged single implants in monkeys: a pilot study. *J Oral Implantol.* 1993;19:314–320.

9. Romanos G, Tok CG, Siar CH, et al. Peri-implant bone reactions to immediately loaded implants. An experimental study in monkeys. *J Periodontol.* 2001; 72:506–511.

10. Traini T, Degidi M, Caputi S, Strocchi R, Di Iorio D, Piattelli A. Collagen fiber orientation near dental implants in human bone: do their organization reflect differences in loading? *J Biomed Mater Res B Appl Biomater.* 2005;76:83–89.

11. Traini T, Degidi M, Strocchi R, Caputi S, Piattelli A. Collagen fiber orientation in human peri-implant bone: do their organization reflect differences in loading? *J Biomed Mater Res B Appl Biomater.* 2005;74:538–546.

12. Frost HM. The regional acceleratory phenomenon: a review. *Henry Ford Hosp Med J.* 1983;31:3–9.

13. Frost HM. Mechanical adaptation of Frost's mechanostat theory. In: Martin DB, Burr DB, eds. *Structure, Function, and Adaptation of Compact Bone.* New York, NY: Raven Press; 1989:179–181.

14. Roberts WE, Smith RK, Zilerman Y, Magary PG, Smith RS. Osseous adaptation to continuous loading of rigid endosseous implants. *Am J Orthod.* 1984;86:95–111.

15. Roberts WE, Turley PK, Brezniak N, Fielder PJ. Implant: bone physiology and metabolism. *CDA J.* 1987;15:54–61.

16. Riggs CM, Lanyon LE, Boyde A. Functional associations between collagen fiber orientation and locomotor strain direction on cortical bone of the equine radius. *Anat Embryol (Berl).* 1993;187:231–238.

17. Misch CE, Bidez MW, Sharawy M. A bioengineered implant for a predetermined bone cellular response to loading forces: a literature review and case report. *J Periodontol.* 2001;72:1276–1286.

18. Simmons CA, Meguid SA, Pilliar RM. Mechanical regulation of localized and appositional bone formation around bone-interfacing implants. *J Biomed Mater Res.* 2001;55:63–71.