

# Astigmatism Correction With Toric IOL: Analysis of Visual Performance, Position, and Wavefront Error

Lisa Toto, MD, PhD; Luca Vecchiarino, MD; Erminia D'Ugo, MD; Daniela Cardone, PhD; Alessandra Mastropasqua, MD; Rodolfo Mastropasqua, MD; Marta Di Nicola, PhD

## ABSTRACT

**PURPOSE:** To evaluate astigmatism correction, visual performance, intraocular lens (IOL) position, and wavefront error after implantation of toric IOLs in patients with cataract.

**METHODS:** This prospective study comprised 30 eyes of 30 patients with cataract who were candidates for phacoemulsification and implantation of the AcrySof toric IOL (Alcon Laboratories, Inc., Fort Worth, TX). Mean preoperative corneal keratometric and subjective refractive cylinder were  $2.10 \pm 0.47$  and  $2.17 \pm 0.41$  diopters (D), respectively.

**RESULTS:** The refractive cylinder decreased significantly from  $2.17 \pm 0.41$  to  $0.73 \pm 0.45$  D ( $P = .001$ ) at 180 days postoperatively. The difference between preoperative corneal astigmatism and postoperative refractive astigmatism was statistically significant ( $P < .05$ ). At 180 days postoperatively, the uncorrected distance visual acuity was 0.20 logMAR (Snellen 20/32) in 100% of patients and 0.0 logMAR (Snellen 20/20) in 64% of patients. The root mean square of internal coma and trefoil aberrations showed a trend toward reduction; internal spherical aberration significantly decreased, whereas corneal trefoil aberration significantly increased ( $P < .05$ ). A low amount of IOL decentration and tilt were detected at 30 and 180 days postoperatively, respectively.

**CONCLUSIONS:** Toric IOL implantation is an effective procedure for correction of preexisting corneal astigmatism, improving visual performance, and inducing a low amount of higher-order aberrations. Moreover, the toric IOLs are well positioned early after surgery and stable over time.

[*J Refract Surg.* 2013;29(7):476-483.]

**T**oric IOLs provide an alternative method for correcting corneal astigmatism in pseudophakic patients. Several studies have reported the efficacy of different toric IOL models, particularly with low and moderate corneal astigmatism.<sup>1-7</sup> Nevertheless, one of the most important problems associated with implantation of these lenses has been the rotation of the toric IOL after implantation.<sup>2,4,7-9</sup> A new generation of toric IOLs with different materials and modified haptic designs have demonstrated good efficacy and greater stability compared to previous IOLs models.<sup>10-15</sup>

The purpose of this prospective study was to assess the astigmatic reduction, visual performance, IOL position, and higher-order aberration (HOA) pattern after implantation of AcrySof toric IOLs (Alcon Laboratories, Inc., Fort Worth, TX).

## PATIENTS AND METHODS

This prospective study comprised 30 eyes of 30 patients with cataract with documented preoperative corneal cylinder between 1.5 and 2.50 diopters (D) who were candidates for phacoemulsification and implantation of a toric IOL. At the time of surgery, patients who had this range of cylinder were offered the option of having implantation of an AcrySof T3, T4, or T5 toric IOL (with cylindrical power at the corneal plane ranging from 1.03 to 2.06 D).

The exclusion criteria were anterior segment pathological alterations such as keratoconus, chronic uveitis, zonular

*From the Department of Medicine and Science of Ageing Eye Clinic, G. d'Annunzio University Chieti-Pescara, Chieti-Pescara, Italy (LT, LV, ED); Center of Excellence on Aging and Department of Biomedical Science, Laboratory of Biostatistics, G. d'Annunzio University Foundation, G. d'Annunzio University Chieti-Pescara, Chieti-Pescara, Italy (MD); Department of Neuroscience and Imaging, Institute of Advanced Biomedical Technologies, G. d'Annunzio University Foundation, G. d'Annunzio University Chieti-Pescara, Chieti-Pescara, Italy (DC); Ophthalmic Clinic, Campus Biomedico, University of Rome, Rome, Italy (AM); and Ophthalmic Clinic, University of Verona, Verona, Italy (RM).*

Submitted: December 21, 2012; Accepted: March 18, 2013

The authors have no financial or proprietary interest in the materials presented herein.

Correspondence: Lisa Toto, MD, PhD, Clinica Oftalmologica, Centro di Eccellenza in Oftalmologia, Ospedale Clinicizzato, Via dei Vestini, 66100 Chieti, Italy. E-mail: [totalisa@hotmail.com](mailto:totalisa@hotmail.com)

doi:10.3928/1081597X-20130617-06

dialysis mellitus, pseudoexfoliation syndrome, glaucoma, and diabetes mellitus; other ocular pathologies impairing visual function; previous anterior or posterior segment surgery; and intraoperative or postoperative complications.

Before cataract surgery, patients had a complete ophthalmologic examination including manifest refraction, manual keratometry, and topography by OPD-Scan II and OPD-Station software (NIDEK Co. Ltd., Gamagori, Japan), slit-lamp examination, applanation tonometry, and ophthalmoscopy through dilated pupils. Axial length was measured with IOLMaster (Carl Zeiss Meditec, Jena, Germany). IOL spherical power was calculated using the SRK/T formula with targeted refraction for emmetropia by the IOLMaster. IOL cylinder power and axis of placement were calculated using a program available from the IOL manufacturer ([www.acrysoftoriccalculator.com](http://www.acrysoftoriccalculator.com)).

Preoperative keratometry and biometric data, incision location, and the surgeon's estimated surgically induced corneal astigmatism of 0.50 D were used to determine the appropriate AcrySof toric IOL model, spherical equivalent lens power, and axis of placement in the eye.

In all cases, standardized uneventful small-incision phacoemulsification with IOL implantation was performed by the same surgeon using topical anesthesia. With the patient seated at the slit lamp and with a coaxial thin slit turned to the 0° to 180° axis, the corneal limbus was marked at the 0° and 180° positions with a sterile marker after vertical alignment of the patient's head. Next, with the patient lying on the surgical table, the steep corneal meridian was identified and marked using a Mendez ring with the aid of the preplaced reference points. After a 2.75-mm clear corneal tunnel was made, a 5.5-mm curvilinear capsulorrhexis was created.

Phacofracture in the capsular bag was followed by automated irrigation/aspiration of the cortical remnants. The IOL was implanted in the capsular bag and aligned along the corneal steep axis using the corneal marks as reference. The incision was not sutured. Postoperative therapy consisted of ofloxacin 0.3% and dexamethasone 0.2% eye drops four times daily for 3 weeks.

The main outcome measures were uncorrected and corrected distance visual acuity, subjective refractive sphere at the spectacle plane, subjective refractive cylinder at the spectacle plane, and topographic keratometric cylinder. In addition, a power vector analysis of refractive and keratometric astigmatic change between preoperative and postoperative values was performed. To visualize the change in astigmatism induced by surgery, the astigmatic components of the power vector were graphically analyzed by the two-dimensional

vector ( $J_0, J_{45}$ ), which is the projection of the three-dimensional power vector into the astigmatism plane formed by the coordinate axes ( $J_0, J_{45}$ ).<sup>16</sup> In all cases, the root mean square (RMS) of ocular, corneal, and internal HOA (HOA RMS, RMS  $Z_4^0$ , RMS  $Z_3^1$ , and RMS  $Z_3^3$ ) and IOL tilt (degrees in x and y axis) and decentration (mm in x and y axis) were evaluated.

Although this was a prospective study, patient treatment was not modified by the study protocol. Therefore, our departmental institutional review board deemed approval by the ethics committee was not necessary. The study adhered to the tenets of the Declaration of Helsinki. All patients signed an informed written consent form after both surgical methods were explained. The scheduled follow-up examinations of the main parameters evaluated in the study were set at 30 and 180 days postoperatively.

#### WAVEFRONT ABERRATION ANALYSIS

The HOAs were measured using OPD-Scan II and OPD-Station software based on retinoscopic principles using infrared light, as previously described.<sup>17</sup> The OPD-Scan II measured the corneal topography and ocular wavefront, enabling the determination of corneal and internal aberration of the eye. It calculated ocular, corneal, and internal aberrations in terms of Zernike polynomials up to the sixth order, measured in microns. The ocular, corneal, and internal total (from first to sixth order) and higher-order wavefront error (from third to sixth order) expressed in RMS represent the average of the square root of the wavefront errors, measured in microns.

Aberration measurements were obtained at the baseline preoperative visit and during scheduled follow-up examinations after pupil dilation with phenylephrine chlorhydrate and tropicamide. In each patient, a 5.0-mm pupil diameter was chosen as reference pupil diameters to obtain comparable data. The ocular, corneal, and internal RMS of total HOAs and of single third-order coma ( $Z_3^1, Z_3^{-1}$ ), third-order trefoil ( $Z_3^3, Z_3^{-3}$ ), and fourth-order spherical ( $Z_4^0$ ) aberrations were calculated at each evaluation for each patient as the mean value of three reliable consecutive measurements.

#### IOL POSITION ASSESSMENT

To assess IOL tilt and decentration, single best images obtained for 0° to 180° and 90° to 270° meridians by the Pentacam Scheimpflug System (Oculus, Inc., Berlin, Germany) at 30 and 180 days postoperatively were collected for each patient. The images were blinded for patient information and randomized. A single reader (LT) then evaluated the tilt and decentration with an in-house closed-source software devel-

oped in MatLab 2009b (MathWorks, Inc., Natick, MA) (see [www.ophtalmology.unich.it](http://www.ophtalmology.unich.it) for further details). For each image, the mean and standard error among different measures and the intraclass correlation coefficient (ICC) was evaluated (data not shown). The ICC is a measure of the reproducibility of repeated measures and indicates the true variance as a fraction of its total. We considered repeated measurements with an ICC value in excess of 0.75 as being clinically useful. Confidence intervals for ICC were calculated according to Scheffe's methods. In case of low reproducibility, the three measurements were repeated.

#### POSTOPERATIVE TORIC IOL AXIS ALIGNMENT ASSESSMENT AND CAPSULE FIBROSIS ASSESSMENT

Postoperative toric IOL axis alignment was assessed at 1, 30, and 90 days postoperatively using a Haag-Streit slit lamp. The thinnest coaxial slit was projected in front of the eye and rotated until the thin slit projection overlapped the axis marks of the IOL with the patient sitting in the upright position, after obtaining proper patient head alignment. The IOL axis position was determined using the vertical arm readings of the slit lamp. Three measurements per eye were taken and averaged. Anterior capsule fibrosis was assessed with focal and retroillumination photographs obtained with maximum pupil dilation using a Tomey video-slit lamp. Digital retroillumination photographs for posterior capsule opacification assessment were obtained with the same equipment. All digital images were transferred to a personal computer and stored on hard disk for later evaluation. All analysis was performed by the same observer.

Anterior capsule opacification was subjectively graded as 0 = none, 1 = moderate: mild opacification not involving the whole capsulorrhexis, 2 = severe: complete whitening of the capsule over the IOL optic. The intensity of central posterior capsule opacification (behind the IOL optic) was subjectively scored from 0 to 4: 0 = none, 1 = minimal, 2 = mild, 3 = moderate, 4 = severe.

#### STATISTICAL ANALYSIS

In all patients, the postoperative follow-up of the parameters evaluated in the study was set at 180 days. To detect the departures from normality, the distribution Shapiro-Wilk test was performed and statistical analysis was then performed using non-parametric tests. A non-parametric one-way analysis of variance for repeated measures (Friedman test) and relative multiple comparisons was used to compare the quantitative parameters at different time periods. The statistically significant difference during the follow-up period of tilt

and decentration parameters was evaluated with the Wilcoxon signed rank test (180 vs 30 days); the same statistical test was applied to evaluate the statistically significant difference with respect to zero for tilt and decentration values.

All statistical tests were evaluated at an alpha level of .05. Statistical analysis was performed using SPSS software version 11.0 (SPSS, Inc., Chicago, IL).

## RESULTS

### DEMOGRAPHICS AND PREOPERATIVE DATA

The mean age was  $64.12 \pm 9.20$  years (range: 50 to 75 years). Mean preoperative corneal refractive cylinder was  $1.59 \pm 1.65$  (+D) and mean topographic cylinder was  $2.10 \pm 0.47$  D. Preoperative topographic keratometric cylinder was chosen for comparison with postoperative refractive cylinder values at 30 and 180 days.

### REFRACTIVE OUTCOME

Refractive change is listed in **Table 1**. Postoperative refractive astigmatism was within  $\pm 0.50$  D in 27% of eyes and within  $\pm 1.00$  in 82% of eyes (**Figure 1A**). Postoperative spherical equivalent refraction was within  $\pm 0.50$  D in 45% of eyes and within  $\pm 1.00$  in 100% of eyes (**Figure 1B**). The difference between preoperative corneal keratometric astigmatism and postoperative subjective refractive astigmatism was statistically significant ( $P < .05$ ) (**Figure 2**). The changes in the astigmatic power vector ( $J_0$ ,  $J_{45}$ ) between preoperative and postoperative values of refractive and keratometric astigmatism for all cases are presented in **Figure 3**. The origin in this graph (0,0) represents an eye free of astigmatism. For refractive astigmatism, the points were spread preoperatively and concentrated around the origin after toric IOL implantation (**Figure 3A**). The mean refractive astigmatic change between preoperative and 180 days postoperatively was  $0.66 \pm 0.20$  D for  $J_0$  ( $P < .001$ ) and  $0.10 \pm 0.25$  D for  $J_{45}$  ( $P = .525$ ). For keratometric astigmatism, the points were spread in the scatter plot before and after surgery. The mean keratometric astigmatic change between preoperative and 180 days postoperatively was  $0.63 \pm 0.18$  D for  $J_0$  ( $P < .001$ ) and  $0.13 \pm 0.23$  D for  $J_{45}$  ( $P = .453$ ) (**Figure 3B**).

### VISUAL OUTCOME

At 180 days postoperatively, the uncorrected distance visual acuity was 0.20 logMAR (Snellen 20/32) in 100% of patients and 0.0 logMAR (Snellen 20/20) in 64% of patients (**Figure 4**). All patients gained more than three Snellen lines: 33.3% more than eight lines, 33.3% more than seven lines, and 25% between three and six lines compared to preoperative visual acuity.

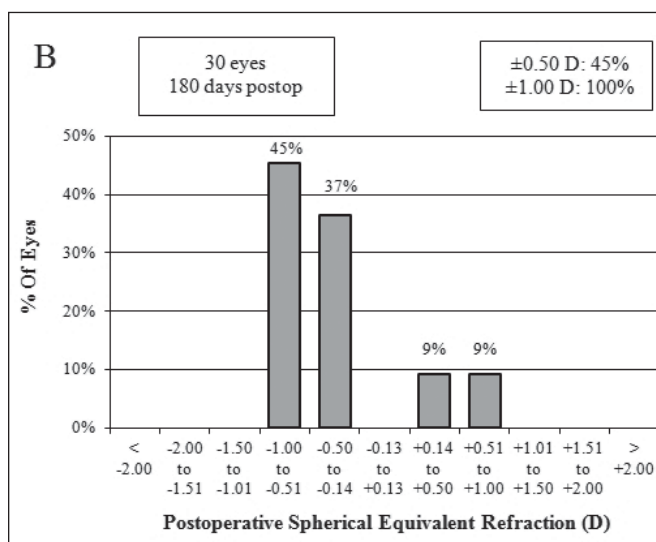
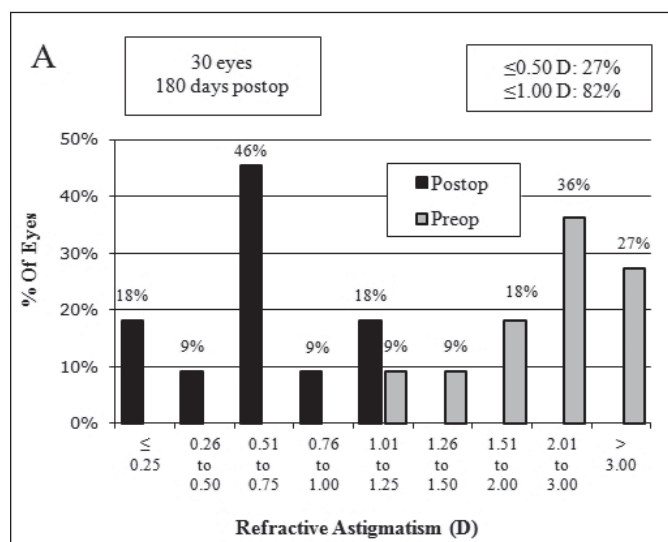
TABLE 1  
**Mean  $\pm$  Standard Deviation of Refractive Parameters Preoperatively and 30 and 180 Days Postoperatively**

Variable	Preoperative	Postoperative		P <sup>a</sup>
		30 Days	180 Days	
Spherical equivalent	-3.48 $\pm$ 2.27	-0.43 $\pm$ 0.40 <sup>b</sup>	-0.42 $\pm$ 0.48 <sup>b</sup>	.001
Refractive sphere (D)	-2.68 $\pm$ 1.68	-0.18 $\pm$ 0.25 <sup>b</sup>	-0.23 $\pm$ 0.26 <sup>b</sup>	.001
Refractive cylinder (+D)	2.17 $\pm$ 0.41	0.68 $\pm$ 0.50 <sup>b</sup>	0.73 $\pm$ 0.45 <sup>b</sup>	.001
Topographic cylinder (D) (OPD)	2.10 $\pm$ 0.47	2.47 $\pm$ 0.74	2.47 $\pm$ 0.68	.368

D = diopters; OPD = optical path difference

<sup>a</sup>Non-parametric Friedman test.

<sup>b</sup>P < .05 multiple comparisons versus preoperative value.



**Figure 1.** Percentage of eyes with cumulative (A) refractive astigmatism and (B) postoperative spherical equivalent refraction.

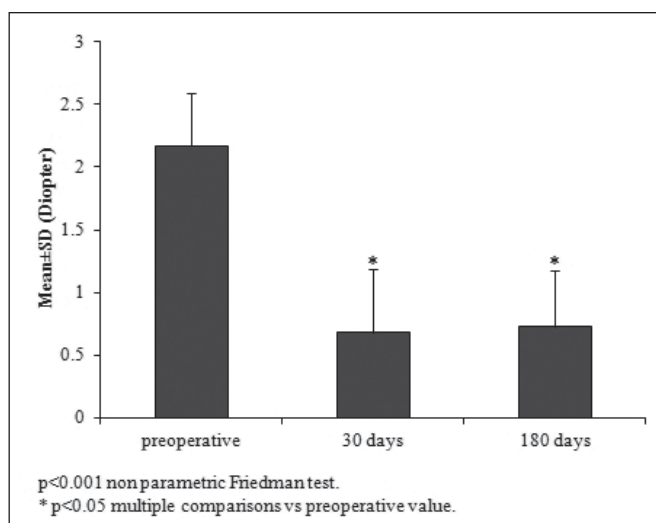
### WAVEFRONT ERROR

Postoperatively, the RMS of ocular total higher-order and RMS of spherical and trefoil aberrations at 5 mm of analysis did not show significant modifications, whereas RMS of total coma aberration significantly decreased ( $P = .042$ ). The RMS of corneal trefoil aberration significantly increased ( $P = .037$ ), whereas other corneal aberrations did not show significant changes. The RMS of internal coma and trefoil aberrations at 5 mm of analysis showed a trend toward reduction and internal spherical aberration significantly reduced compared to preoperative values ( $P = .037$ ) (Table 2).

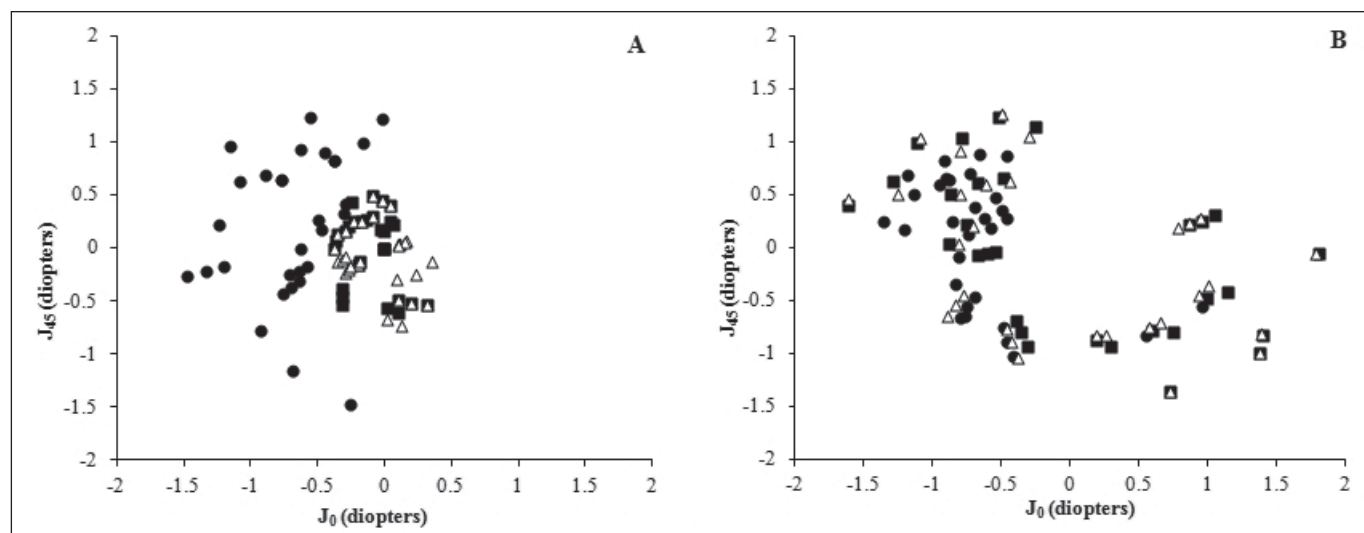
### LENS TILTING AND DECENTRATION

The reliability of the methods was evaluated for tilt around the x (ICC 0.984) and y (ICC 0.852) axis and decentration in the x (ICC 0.933) and y (ICC 0.956) axis.

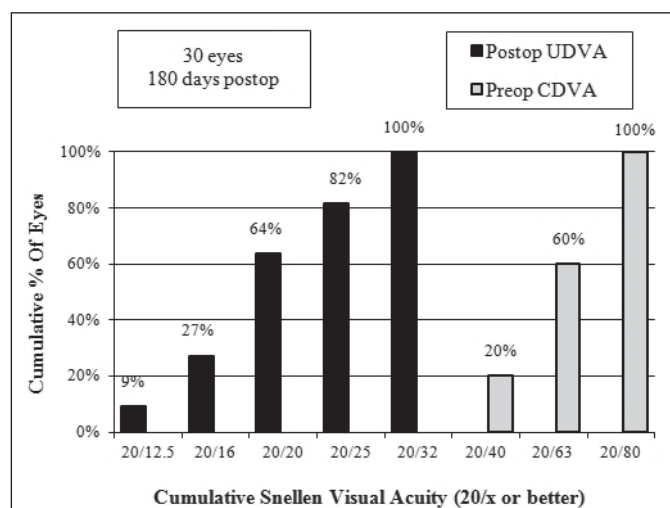
The variation between 30 and 180 days postoperatively resulted in no statistical significance for all tilting and decentration values. At 180 days postopera-



**Figure 2.** Mean  $\pm$  standard deviation of preoperative keratometric cylinder versus postoperative refractive cylinder at 30 and 180 days postoperatively.



**Figure 3.** (A) Vector representation ( $J_0$  and  $J_{45}$ ) of refractive astigmatic change between preoperative and 30 and 180 days postoperatively. (B) Vector representation ( $J_0$  and  $J_{45}$ ) of topographic astigmatic change between preoperative and 30 and 180 days postoperatively. • = preoperative; ■ = 30 days postoperatively; Δ = 180 days postoperatively



**Figure 4.** Percentage of eyes with cumulative Snellen preoperative corrected distance visual acuity (CDVA) and postoperative uncorrected distance visual acuity (UDVA) at 180 days postoperatively.

tively, the value of tilt around the x and y axis and the decentration in the y axis were significantly different to zero ( $P < .05$ ) (Table 3, Figure 5).

**ROTATION STABILITY**

The mean IOL misalignment from intended axes was  $3.1^\circ \pm 3.8^\circ$  (range:  $0^\circ$  to  $10^\circ$ ) at 30 days and  $3.5^\circ \pm 3.6^\circ$  (range:  $0^\circ$  to  $10^\circ$ ) at 180 days postoperatively. The IOL misalignment was within  $5^\circ$  and  $10^\circ$  in 83.3% and 100% of patients, respectively.

**DISCUSSION**

Toric IOLs of different design have been reported to be efficacious for correction of low and moderate astig-

matism. A reduction of refractive astigmatism after toric IOL implantation in percentages of patients included between 54% and 81% with preoperative corneal astigmatism ranging from 2.8 and 3.7 D related to the amount of astigmatism and IOL design was reported.<sup>6,10,18</sup>

Nevertheless, several authors described rotation as a complication limiting surgical success of these lenses for astigmatic correction. Rotation greater than  $10^\circ$  has been reported in between 4.4% and 50% of patients implanted with toric IOLs.<sup>2,7-9</sup> Capsulorrhexis size, IOL design, and material play a significant role in rotational stability.<sup>11,19</sup> In the early postoperative period, IOL rotation is mainly related to a disproportion between IOL and capsular bag dimension with greater IOL stability for longer IOLs and smaller capsular bag size usually related to shorter axial length.<sup>10</sup> In relation to the IOL model, early toric IOL designs with C-loop haptic and plate haptic showed more tendency to rotate, with rotation greater than  $10^\circ$  in a high percentage of patients.<sup>2,8</sup>

Toric IOLs of new designs have been conceived to improve early and late rotation stability of toric IOLs. Modified L- and Z-design haptics toric IOL showed greater rotational stability with rotation lower than  $10^\circ$  in a high percentage of patients.<sup>11,13-15</sup> De Silva et al. showed no rotation of more than  $5^\circ$  with a Z-design haptics (Microsil, HumanOptics AG, Erlangen, Germany) toric IOL.<sup>11</sup> Several studies with medium and long-term follow-up described the efficacy of an AcrySof toric IOL with modified L-design haptics for astigmatism correction with excellent results concerning predictability and stability of achieved correction. Residual refractive astigmatism of 0.50 D or less has been observed in 75%

TABLE 2

**Mean  $\pm$  Standard Deviation of Ocular Internal Wavefront Error Parameters at 5 mm Preoperatively and 30 and 180 Days Postoperatively**

Variable	Preoperative	Postoperative		P <sup>a</sup>
		30 Days	180 Days	
Ocular RMS HOA	0.40 $\pm$ 0.13	0.41 $\pm$ 0.18	0.43 $\pm$ 0.21	.625
Ocular RMS Z <sub>3</sub> <sup>1</sup>	0.23 $\pm$ 0.23	0.09 $\pm$ 0.05 <sup>b</sup>	0.09 $\pm$ 0.06 <sup>b</sup>	.042
Ocular RMS Z <sub>3</sub> <sup>3</sup>	0.28 $\pm$ 0.15	0.34 $\pm$ 0.17	0.30 $\pm$ 0.14	.347
Ocular RMS Z <sub>4</sub> <sup>0</sup>	0.08 $\pm$ 0.07	0.15 $\pm$ 0.05	0.14 $\pm$ 0.04	.244
Corneal RMS HOA	0.28 $\pm$ 0.10	0.34 $\pm$ 0.11	0.30 $\pm$ 0.08	.347
Corneal RMS Z <sub>3</sub> <sup>1</sup>	0.17 $\pm$ 0.09	0.13 $\pm$ 0.12	0.13 $\pm$ 0.10	.889
Corneal RMS Z <sub>3</sub> <sup>3</sup>	0.09 $\pm$ 0.05	0.22 $\pm$ 0.10 <sup>b</sup>	0.20 $\pm$ 0.08 <sup>b</sup>	.037
Corneal RMS Z <sub>4</sub> <sup>0</sup>	0.16 $\pm$ 0.06	0.11 $\pm$ 0.04	0.11 $\pm$ 0.03	.441
Internal RMS HOA	0.34 $\pm$ 0.08	0.29 $\pm$ 0.17	0.31 $\pm$ 0.24	.703
Internal RMS Z <sub>3</sub> <sup>1</sup>	0.13 $\pm$ 0.03	0.10 $\pm$ 0.08	0.11 $\pm$ 0.08	.244
Internal RMS Z <sub>3</sub> <sup>3</sup>	0.21 $\pm$ 0.11	0.16 $\pm$ 0.15	0.15 $\pm$ 0.11	.625
Internal RMS Z <sub>4</sub> <sup>0</sup>	0.11 $\pm$ 0.06	0.04 $\pm$ 0.03 <sup>b</sup>	0.05 $\pm$ 0.03 <sup>b</sup>	.037

RMS = root mean square; HOA = higher-order aberration

<sup>a</sup>Non-parametric Friedman test.

<sup>b</sup>P < .05 multiple comparisons versus preoperative value.

TABLE 3

**Mean  $\pm$  Standard Deviation of Tilt and Decentration Values**

Variable	30 Days Postoperatively	180 Days Postoperatively	P <sup>a</sup>
Tilt around x (degrees)	-1.99 $\pm$ 1.34	-3.76 $\pm$ 1.38 <sup>b</sup>	.057
Tilt around y (degrees)	-0.81 $\pm$ 0.54	-1.63 $\pm$ 0.51 <sup>b</sup>	.184
Decentration in x (mm)	-0.04 $\pm$ 0.03	-0.23 $\pm$ 0.03	.088
Decentration in y (mm)	-0.03 $\pm$ 0.04	-0.12 $\pm$ 0.04	.056

<sup>a</sup>Wilcoxon U test 180 days versus 30 days values.

<sup>b</sup>P < .05 Wilcoxon signed rank test versus value of zero.

to 100% of patients. Rotation less than 10° has been reported in more than 95% of patients.<sup>12,14</sup>

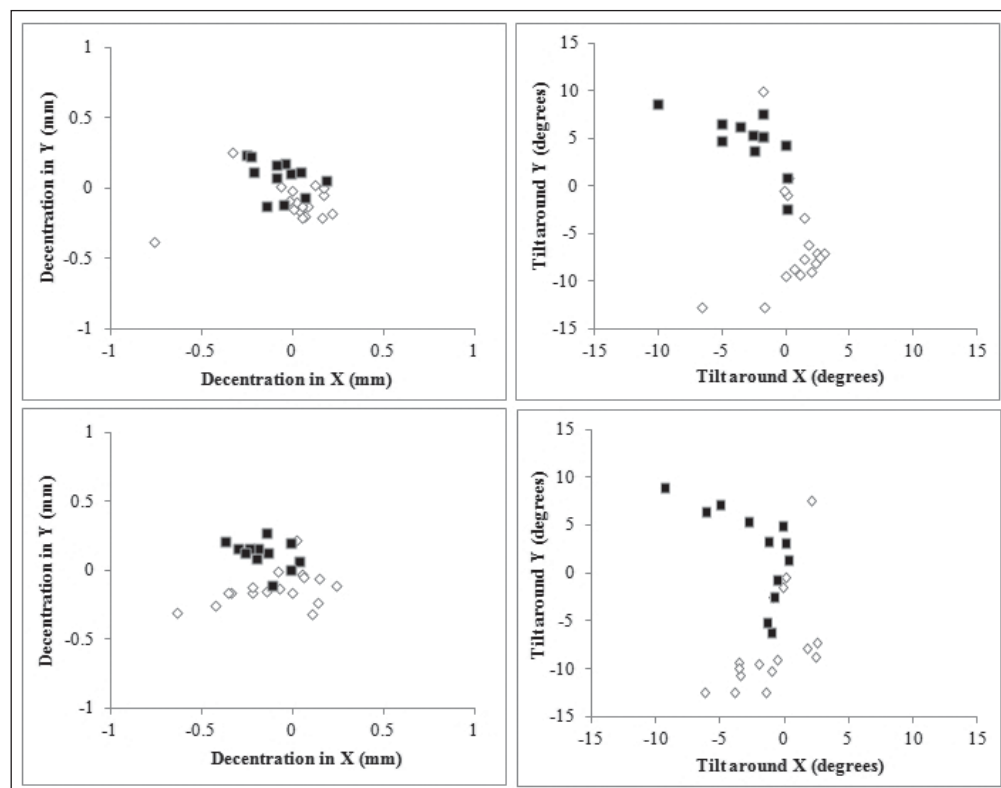
In our study, AcrySof toric IOLs showed excellent efficacy for astigmatism correction, with reduction of refractive subjective cylinder at 180 days postoperatively. The power vector analysis between preoperative and postoperative refractive astigmatism showed concentration of the points after IOL implantation around zero.

Previous studies have reported a reduction of refractive astigmatism after implantation of AcrySof toric IOLs ranging from 64.5% to 71.8%<sup>10,12,15</sup> compared to 68.7% observed in our study. Moreover, when comparing preoperative corneal keratometric astigmatism and postoperative subjective refractive astigmatism in our study, there was a statistically significant difference (P < .001) with mean preoperative corneal astigmatism that was reduced by a factor of 3.1.

Evaluation of the difference between preoperative corneal astigmatism, chosen as reference for toric IOL cylindrical power selection, and postoperative subjective refractive astigmatism is probably more accurate for assessment of correction of preexisting astigmatism than preoperative and postoperative refractive astigmatism evaluation. In fact, preoperative refractive astigmatism is influenced by internal astigmatism due to cataract; thus it considers an amount of astigmatism that modifies the total preoperative refractive astigmatism of the eye and was not present postoperatively after cataract extraction.

Keratometric astigmatism did not show any significant modification between preoperative and postoperative values that was a fundamental requirement when planning astigmatism correction with toric IOL.

In our study, the mean IOL misalignment from intended axes was 3.1°  $\pm$  3.8° at 30 days and 3.5°  $\pm$  3.6° at



**Figure 5.** Decentration and tilt at 30 days (upper panels) and 180 days (lower panels) postoperatively. Solid symbols indicate left eyes and open symbols indicate right eyes.

180 days postoperatively. The IOL misalignment was within  $5^\circ$  in 83.3% and within  $10^\circ$  in 100% of patients. The IOL rotation stability is further confirmed by the stability of cylindrical correction. Mendicutte et al. reported comparable values of rotation of  $3.63^\circ \pm 3.11^\circ$  (range:  $0^\circ$  to  $12^\circ$ ) at 3 months postoperatively with 96.7% of eyes having rotation less than  $10^\circ$  in patients implanted with the three models of AcrySof IOLs.<sup>12</sup> Alió et al. described a mean rotation  $3.35^\circ \pm 3.56^\circ$ ,  $4.80^\circ \pm 5.28^\circ$ , and  $5.06^\circ \pm 4.21^\circ$  at 1, 3, and 6 months after the implantation of AcrySof IOLs, respectively.<sup>15</sup>

It has been demonstrated that the AcrySof hydrophobic acrylic material strongly adheres to the capsule and it has been correlated with low incidence of capsular fibrosis.<sup>20-22</sup> The low incidence of capsular fibrosis mainly correlated to the “tacky” nature of the AcrySof material, suggesting the possible role of this factor in the stabilization of the lens in the capsular bag and thus to the low grade of rotation at 30 and 180 days postoperatively encountered in our study.

Considering visual performance, other authors reported a uncorrected visual acuity of 20/40 or better in between 93% and 95% of patients and of 20/25 in between 70% and 85%.<sup>14,16</sup> In our study, the uncorrected distance visual acuity at 180 days postoperatively was 0.20 logMAR (Snellen 20/32) in 100% of patients and 0.0 logMAR (Snellen 20/20) in 64% of patients. The optical quality of the eye implanted with the toric IOL

was also good, as demonstrated by wavefront error analysis that showed a trend toward reduction of internal total higher-order, coma, trefoil, and spherical aberrations in the postoperative period compared to preoperative values.

Internal aberrations are mainly related to the IOL profile and position after cataract extraction. In our patients, the reduction of spherical aberration after surgery was mainly related to internal reduction of the symmetric spherical high-order error due to the substitution of the aged crystalline lens with the toric IOL. Third-order aberrations are related to IOL tilting and decentration.<sup>23</sup>

In our study, the low amount of tilting and decentration correlated well with the low values of internal third-order aberrations. The slight increase of corneal aberrations was probably related to the corneal incision: thus, a microincision cataract surgery should be considered when planning toric IOL implantation, possibly reducing the increment of corneal wavefront error related to the incision size. AcrySof toric IOLs demonstrated safety and efficacy for the correction of preexisting astigmatism with good postoperative visual performance and low wavefront error. Clinical trials with longer follow-up and larger samples are needed to evaluate the long-term stability of the correction and influence of anterior and posterior capsular fibrosis on IOL rotation and thus on the long-term efficacy of astigmatism correction by toric IOLs.

## AUTHOR CONTRIBUTIONS

Study concept and design (LT); data collection (LV, ED, AM); analysis and interpretation of data (DC, RM, MD); drafting of the manuscript (LT); critical revision of the manuscript (LV, ED, DC, AM, RM, MD); statistical expertise (MD); supervision (DC)

## REFERENCES

- Horn JD. Status of toric intraocular lenses. *Curr Opin Ophthalmol.* 2007;18:58-61.
- Shimizu K, Misawa A, Suzuki Y. Toric intraocular lenses: correcting astigmatism while controlling axis shift. *J Cataract Refract Surg.* 1994;20:523-526.
- Gills JP, Van der Karr M, Cherchio M. Combined toric intraocular lens implantation and relaxing incisions to reduce high preexisting astigmatism. *J Cataract Refract Surg.* 2002;28:1585-1588.
- Novis C. Astigmatism and toric intraocular lenses. *Curr Opin Ophthalmol.* 2000;11:47-50.
- Sun XY, Vicary D, Montgomery P, Griffiths M. Toric intraocular lenses for correcting astigmatism in 130 eyes. *Ophthalmology.* 2000;107:1776-1782.
- Ruhswurm I, Scholz U, Zehetmayer M, Hanselmayer G, Vass C, Skorpik C. Astigmatism correction with a foldable toric intraocular lens in cataract patients. *J Cataract Refract Surg.* 2000;26:1022-1027.
- Leyland M, Zinicola E, Bloom P, Lee N. Prospective evaluation of a plate haptic toric intraocular lens. *Eye (Lond).* 2001;15:202-205.
- Grabow HB. Toric intraocular lens report. *Ann Ophthalmol.* 1997;29:161-163.
- Werblin TP. Do three-piece PMMA IOLs rotate after implantation in the capsular bag? *J Refract Surg.* 1995;11:468-471.
- Chang DF. Early rotational stability of the longer Staar toric intraocular lens: fifty consecutive cases. *J Cataract Refract Surg.* 2003;29:935-940.
- De Silva DJ, Ramkissoon YD, Bloom PA. Evaluation of a toric intraocular lens with a Z-haptic. *J Cataract Refract Surg.* 2006;32:1492-1498.
- Mendicute J, Irigoyen C, Aramberri J, Ondarra A, Montés-Micó R. Foldable toric intraocular lens for astigmatism correction in cataract patients. *J Cataract Refract Surg.* 2008;34:601-607.
- Visser N, Ruíz-Mesa R, Pastor F, Bauer NJ, Nuijts RM, Montés-Micó R. Cataract surgery with toric intraocular lens implantation in patients with high corneal astigmatism. *J Cataract Refract Surg.* 2011;37:1403-1410.
- Chang DF. Comparative rotational stability of single-piece open-loop acrylic and plate-haptic silicone toric intraocular lenses. *J Cataract Refract Surg.* 2008;34:1842-1847.
- Alió JL, Piñero DP, Tomás J, Plaza AB. Vector analysis of astigmatic changes after cataract surgery with implantation of a new toric multifocal intraocular lens. *J Cataract Refract Surg.* 2011;37:1217-1229.
- Thibos LN, Horner D. Power vector analysis of the optical outcome of refractive surgery. *J Cataract Refract Surg.* 2001;27:80-85.
- Ligabue EA, Giordano C. Interpretation of aberrometry measurements in cataract surgery. *J Refract Surg.* 2007;23:S996-S1004.
- Till JS, Yoder PR Jr, Wilcox TK, Spielman JL. Toric intraocular lens implantation: 100 consecutive cases. *J Cataract Refract Surg.* 2002;28:295-301.
- Patel CK, Ormonde S, Rosen PH, Bron AJ. Postoperative intraocular lens rotation; a randomized comparison of plate and loop haptic implants. *Ophthalmology.* 1999;106:2190-2195.
- Tognetto D, Toto L, Sanguinetti G, et al. Lens epithelial cell reaction after implantation of different intraocular lens materials: two-year results of a randomized prospective trial. *Ophthalmology.* 2003;110:1935-1941.
- Tognetto D, Toto L, Minutola D, et al. Hydrophobic acrylic versus heparin surface-modified polymethylmethacrylate intraocular lens: a biocompatibility study. *Graefes Arch Clin Exp Ophthalmol.* 2003;41:625-630.
- Werner L, Pandey SK, Escobar-Gomez M, Visessook N, Peng Q, Apple DJ. Anterior capsule opacification: a histopathological study comparing different IOL styles. *Ophthalmology.* 2000;107:463-471.
- Taketani F, Matuura T, Yukawa E, Hara Y. Influence of intraocular lens tilt and decentration on wavefront aberrations. *J Cataract Refract Surg.* 2004;30:2158-2162.