Joints

Unicompartmental knee replacement: a historical overview

DANILO BRUNI, FRANCESCO IACONO, IBRAHIM AKKAWI, MICHELE GAGLIARDI, STEFANO ZAFFAGNINI, MAURILIO MARCACCI

2nd Orthopedics and Traumatology Clinic, Laboratory of Biomechanics and Technological Innovation, Rizzoli Orthopedics Institute, Bologna, Italy

Abstracts

There is currently a growing demand for unicompartmental knee replacement (UKR) to treat degenerative osteoarthritis or osteonecrosis of a single compartment of the knee.
This procedure has evolved significantly over the past three decades and we here present a brief review of the literature on this topic. This historical overview traces the hypotheses that have led to the modern state of the art in minimally invasive UKR surgery and to the revival of the concept of interpositional hemiarthroplasty.

Key Words: knee replacement, minimally invasive technique.

Ever since its very early development, unicompartmental knee replacement (UKR) has been proposed as a surgical treatment for unicompartmental tibio-femoral (TF) degenerative joint disease, the aim being to "correct deformity, restore stability and relieve pain" (1). Bearing in mind that UKR is realignment surgery involving the insertion of a spacer, these aims, more than half a century on, still accurately encapsulate the fundamental principles of this surgical procedure. In UKR, the proper tension of the ligaments is restored by filling the extension gap with the prosthetic components.
According to the advocates of UKR as a treatment for unicompartmental osteoarthritis (OA) of the knee – as opposed to total knee replacement (TKR) and high tibial osteotomy (HTO) –, this procedure offers a series of advantages: better long-term results, a less aggressive surgical procedure, reduced post-operative morbidity, and faster post-operative recovery, allowing early resumption of daily life activities. These advantages are enhanced through the use of a minimally invasive surgical technique, but they have to be weighed against the need for stricter patient selection, the more technically demanding surgical procedure, and the lack of universal agreement regarding the implant positioning and various implant solutions.
Unicompartmental knee replacement is a suitable option for degenerative joint disease of the medial TF compartment, especially if we consider the natural history of OA. About 25% of patients have isolated antero-medial OA, which remains so for many years (2). Thereafter, joint degeneration progressively leads to osteophyte development in the notch, producing attrition and finally elongation and insufficiency or complete disruption of the anterior cruciate ligament. This leads to TF subluxation and thus to tricompartmental degenerative changes.
The concept of hemiarthroplasty of the knee for the treatment of medial TF degenerative joint disease dates back to the 1950s, when it was developed in order to prevent direct bone-on-bone apposition and provide satisfactory pain relief. The real pioneer was Campbell, who, in 1940, reported his preliminary results on the interposition of vitallium plates in the medial compartment of arthritic knees (3).
Thereafter, McKeever (4), in 1957, introduced his vitallium tibial plateau (**Fig. 1**) prosthesis. Then, in 1958, came MacIntosh's tibial plateau: this was initially acrylic (1) (**Fig. 2**) but was followed, in 1964, by a vitallium one. MacIntosh et al. presented their prelim-

Corresponding Author:
Danilo Bruni, MD
2nd Orthopedics and Traumatology Clinic, Laboratory of Biomechanics and Technological Innovation, Rizzoli Orthopedics Institute, Via di Barbiano, 1/10
40136 Bologna, Italy
Phone: +39 051 6366506 - +39 347 5324790
E-mail: dbruni@biomec.ior.it

Fig. 1. The McKeever interpositional hemiarthroplasty device, consisting of vitallium component to replace the medial tibial plateau.



Fig. 2. The MacIntosh acrylic tibial plateau, developed at around the same time as the McKeever device.

inary results in Switzerland in 1967, while in 1972 the author published a manuscript demonstrating "good results" in terms of overall pain relief in most patients at a mean follow-up of six years (5). MacIntosh noted that the lack of fixation could lead to migration of the device in the unsatisfactory results group. To overcome this problem, McKeever added a keel to his tibial plateau prosthesis.

In the early 1970s, the Gunston and polycentric unicompartmental knee arthroplasty devices were introduced (**Fig. 3**). The revision rate of these early devices at two years was approximately 10%.

Modern UKR implants really started with Marmor, who introduced his modular hemiarthroplasty in 1972 and in 1979 reported a high success rate in 56 patients followed up for a minimum four-year period (6). This was also the period in which the St. Georg sled was introduced in Germany, and in 1976 Engelbrecht et al. (7) reported that 85% of 294 patients achieved a good result after a four-year follow-up. Other authors also produced good initial results following unicompartmental procedures: Scott et al. (8) reported early success with the Brigham prosthesis. Subsequently, both

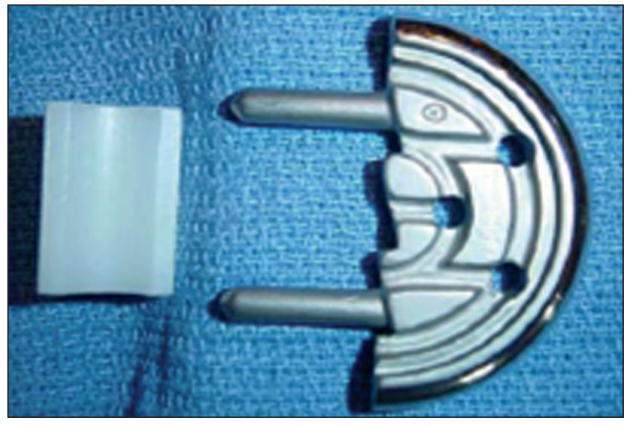

Fig. 3. The Gunston unicompartmental knee replacement: this was the first time a tibial and femoral component was presented as a solution for the resurfacing of both medial compartments.

Larsson and Ahlgren (9) and MacKinnon et al. (10) confirmed satisfactory results with the St. Georg sled. Various authors, from 1973 to 1983, reported success rates varying between 37% and 92 with two- to eight-year follow-ups (6-10). From 1987 to 1991, long-term results were published, showing 87% to 90% survivorship at 13 to 16 years (11, 12).

However, several studies in the 1970s cast doubt on the benefits of UKA as a surgical option for knee OA. In 1980, Insall and Aglietti (13) reported on a series of 22 UKAs that, having been initially successful, had started to fail at the six-year review. Laskin (14) noted poor results with the Marmor prosthesis, and Bucholz and Heinert (15) recorded a high failure rate with the St. Georg sled.

A review of these articles suggested that inappropriate patient selection was a major contributory factor since many of the Insall and Aglietti group had undergone prior patellectomy, and in Germany the prosthesis had frequently been used for bicompartmental disease and often in the presence of rheumatoid arthritis and joint instability. These papers and later reports of mechanical failure of certain prostheses, such as the Brigham one, due to thin polyethylene and possible edge contact, and the PCA Uni, due to poor quality heat-treated polyethylene (16, 17), led to widespread and growing skepticism about the wisdom of using a UKR. Moreover, at the same time, the outcome of TKR was becoming increasingly satisfactory, reproducible and reliable. As a result, in North America and the United Kingdom many surgeons almost abandoned the UKR as an option for the management of unicompartmental OA of the knee and the two principal surgical options became proximal HTO and TKR, the latter being indicated as the easier and

more reliable procedure, always to be performed in knees where an arthroplasty was necessary.

At the same time, however, in mainland Europe many surgeons took the opposite view and continued to perform unicompartmental replacement. In fact, multiple survivorship studies published from 1993 to 2003 continued to report success rates ranging from 87 to 98% at six- to 14-year follow-ups (18, 19). In one series, moreover, 83% of the failures were caused by progressive wear in the un-resurfaced compartment (20).

Recently, increased interest in less invasive surgical treatments for the active, baby-boomer aging population has led to a revival of the concept of hemiarthroplasty, and more and more interpositional devices are being developed for the treatment of medial TF degenerative joint disease.

The more popular modern-day versions of the pioneering hemiarthroplasty devices are the Unispacer (Smith & Nephew, Inc., Memphis, TN) (**Fig. 4**) and the ConforMIS iFORMA (**Fig 5**). As regards the Unispacer, clinical results and success rates at more than two years' follow-up have not been satisfactory (21, 22), while clinical results for the ConforMIS iFORMA (23) are still awaited.

Fig. 4. The Unispacer hemiarthroplasty device.

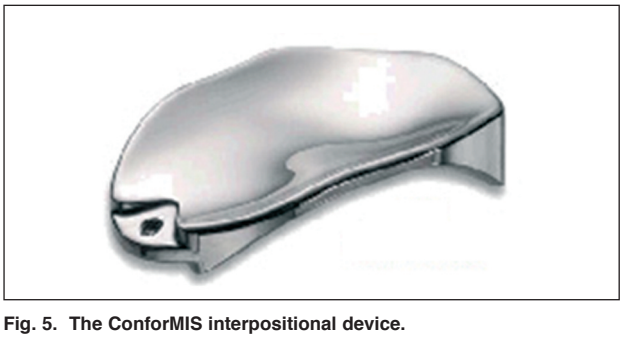

Fig. 5. The ConforMIS interpositional device.

References

1. MacIntosh DL. Hemiarthroplasty of the knee using a space occupying prosthesis for painful varus and valgus deformity. J Bone Joint Surg Am 1958;40:1431.
2. Ackroyd CE. Medial compartment arthroplasty of the knee. J Bone Joint Surg Br 2003;85:937-942.
3. Campbell WC. Interposition of vitallium plates in arthroplasties of the knee: preliminary report. Am J Surg 1940;47:639-641.
4. McKeever DC. Tibial plateau prosthesis. Clin Orthop 18 1960;86-95.
5. MacIntosh DL, Hunter GA. The use of the hemiarthroplasty prosthesis for advanced osteoarthritis and rheumatoid arthritis of the knee. J Bone Joint Surg Br 1972;54:244-255.
6. Marmor L. Marmor modular knee in unicompartmental disease. Minimum four-year follow-up. J Bone Joint Surg Am 1979;61: 347-53.
7. Engelbreclht E, Siegel A, Rottger J, et al. Statistics of total knee replacement: partial and total knee replacement, design St Georg: a review of a 4-year observation. Clin Orthop Relat Res 1976; (120):54-64.
8. Scott RD, Santore RF. Unicondylar unicompartmental replacement for osteoarthritis of the knee. J Bone Joint Surg Am 1981; 63:536-544.
9. Larsson SE, Ahlgren O. Reconstruction with endoprosthesis in gonarthrosis: a report of 111 consecutive cases operated upon from 1973 through 1977. Clin Orthop Relat Res 1979; (145):126-35.
10. Mackinnon J, Young S, Baily RA. The St Georg sledge for unicompartmental replacement of the knee. A prospective study of 115 cases. J Bone Joint Surg Br 1988;70:217-222.
11. Newman JH, Ackroyd CE, Shah NA. Unicompartmental or total knee replacement? Five-year results of a prospective, randomised trial of 102 osteoarthritic knees with unicompartmental arthritis. J Bone Joint Surg Br 1998;80:862-865.
12. Murray DW, Goodfellow JW, O'Connor JJ. The Oxford medial unicompartmental arthroplasty: a ten-year survival study. J Bone Joint Surg Br 1998;80:983-989.
13. Insall J, Aglietti P. A five to seven-year follow-up of unicondylar arthroplasty. J Bone Joint Surg Am 1980;62:1329-1337.
14. Laskin RS. Unicompartmental tibiofemoral resurfacing arthroplasty. J Bone Joint Surg Am 1978;60:182-185.
15. Bucholz HW, Heinert K. Long-term results of cemented arthroplasty. Analysis of complications fifteen years after operation. Orthop Clin North Am 1988;19:531-540.
16. Lindstrand A, Ryd L, Stenström A. Polyethylene failure in two total knees. Wear of thin, metal-backed PCA tibial components. Acta Orthop Scand 1990;61:575-577.
17. Chakrabarty G, Newman JH, Ackroyd CE. The importance of choosing the right prosthesis: the Bristol experience of the PCA uniprosthesis. The Knee 1997;4:167-169.
18. Kennedy WR, White RP. Unicompartmental arthroplasty of the knee. Postoperative alignment and its influence on overall results. Clin Orthop Relat Res 1987;(221):278-285.
19. Squire MW, Callaghan JJ, Goetz DD, et al. Unicompartmental knee replacement. A minimum 15 year follow up study. Clin Orthop Relat Res 1999;(367):61-72.
20. Bert JM. 10-year survivorship of metal-backed, unicompartmental arthroplasty. J Arthroplasty 1998;13:901-905.
21. Scott RD. UniSpacer: insufficient data to support its widespread use. Clin Orthop Relat Res 2003;(416):164-166.
22. Sisto DJ, Mitchell IL. UniSpacer arthroplasty of the knee. J Bone Joint Surg Am 2005;87:1706-1711.
23. Koeck FX, Perlick L, Luring C, et al. Leg axis correction with ConforMIS iForma (interpositional device) in unicompartmental arthritis of the knee. Int Orthop 2009;33:955-960.