CHEST

A 17-Year-Old Male Subject With Chest Pain, Worsening Dyspnea, and a Rare Complication

Alessia Angi, MD; Simone Sferrazza Papa, MD; Sabrina Di Pillo, MD; Francesco Chiarelli, MD, PhD; and Marina Attanasi, MD

CHEST 2020; 158(5):e257-e262

Clinical Evaluation

A 17-year-old male subject with allergic asthma since childhood was transferred from a local hospital to our Department of Pediatrics with reports of chest pain preceded by 3 days of a dry cough and worsening dyspnea. In the last year, he had been controlling his asthma symptoms exclusively with salbutamol, several times a month. The patient had smoked marijuana and tobacco on the previous morning of admission. He denied neurologic complaint, air travel, trauma, or vomiting. On physical examination, the patient was nontoxic appearing but was short of breath and unable to speak in full sentences. He was afebrile with an initial heart rate of 134 beats/min, a respiratory rate of 35 breaths/min, and room air pulse oximetry of 90%. Blood analysis revealed no significant changes, except for a neutrophil count of $14.62 \times 10^3/\mu L$ and a C-reactive protein level of 1.80 mg/dL. Pulmonary examination revealed moderate respiratory distress using accessory muscles of respiration with expiratory wheezing. On neck examination, the patient's trachea was midline with palpable crepitus mainly in the right side with no jugular venous distension. His ECG showed sinus tachycardia with no right ventricular overload data or changes in the ST segment. Furthermore, specific cardiac injury markers were negative.

Chest radiograph (CXR) from the posterior-anterior and lateral angles revealed the presence of free air in the mediastinum with subcutaneous emphysema of the lateral cervical region. CT scan of the neck and chest confirmed extensive subcutaneous emphysema and pneumomediastinum. Noteworthy, there were air bubbles from the sixth cervical vertebra until the ninth thoracic vertebra (Fig 1).

AFFILIATIONS: From the Department of Pediatrics (Drs Angi, Sferrazza Papa, Di Pillo, Chiarelli, and Attanasi) and the Center of Excellence on Aging (Dr Chiarelli), "G. D'Annunzio" University Foundation, University of Chieti, Chieti, Italy.

CORRESPONDENCE TO: Alessia Angi, MD, Department of Pediatrics, University of Chieti, Via dei Vestini 5, Chieti, 66100, Italy; e-mail: alessia.angi@libero.it

DOI: https://doi.org/10.1016/j.chest.2019.11.062

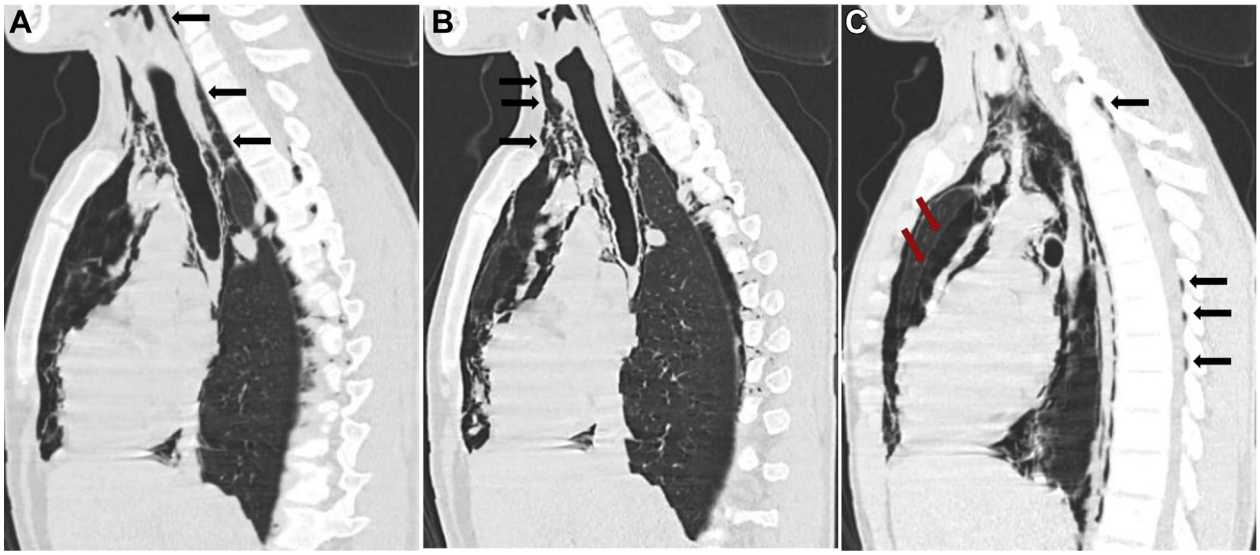

Figure 1 – *Sagittal view of CT scan of the neck and mediastinum. A, Extensive soft tissue abnormality (emphysema) in the retropharynx with loss of normal fat plane with the prevertebral space and possible communication with the oropharynx (black arrows). B, Air is also found in the pre-tracheal tissue (black arrows). C, Air extends into the mediastinum (red arrows). Noteworthy is the presence of the air bubbles from the sixth cervical vertebra until the ninth thoracic vertebra (black arrows).*

Questions: What further imaging tool would aid in the detection of spontaneous pneumomediastinum, minimizing radiation exposure in children? Based on these radiologic findings, what would be a rare complication of spontaneous pneumomediastinum in asthma exacerbation?

Answer: Bedside thoracic ultrasound and epidural pneumorrhachis

Discussion

Radiologic Discussion

Historically, the diagnosis of spontaneous pneumomediastinum (SPM) is made with physical examination and CXR. Importantly, CXR reportedly misses or underestimates the severity of SPM in 10% to 30%.[1,2] When CXR is equivocal but SPM is clinically suspected, chest CT scan is generally considered the diagnostic standard to reveal even small amounts of air in the mediastinum or subcutaneous tissues.[2-4] However, with attempts to minimize radiation exposure, particularly in children, the utility of ultrasound has grown in many pulmonary applications; the detection of SPM by ultrasound is becoming increasingly common even if still in its early stages.[5,6] To date, few case reports of ultrasound identification of SPM have been reported. Sonographic evaluation of the pneumomediastinum was first described in 1983 as the "air gap sign," identified as a broad band of echoes recorded during held respiration due to accumulating air obscuring normal cardiac structures, with drop out of echoes posteriorly.[7]

In the current case, following CXR and chest CT executions, we performed a sonographic examination with a commercial ultrasound scanner (HM70A Diagnostic Ultrasound System, Samsung Healthcare, 2013) equipped with a 3- to 16-MHz linear probe. To better understand this clinical case from the ultrasonography point of view, it is important to remember some physical concepts of the lung ultrasound. The ultrasound beam passes through the tissues explored, interacting with them; in part, the sound is attenuated, in part it comes back to the transducer whenever it strikes acoustic discontinuities. The forces that oppose transmission of the ultrasonic wave inside the medium define the "acoustic impedance." The presence of air makes ultrasound waves almost completely reflected, without being translated into an image. The high acoustic impedance of the air below prevents visualization of the lung parenchyma and produces "reverberation artifacts."

In the current patient, cervical sonography revealed the unusual presence of vertical air artifacts in the anterolateral region, the "comet tails," as first described by Testa et al,[8] constituting a partial acoustic barrier to visualization of the underlying anatomic structures

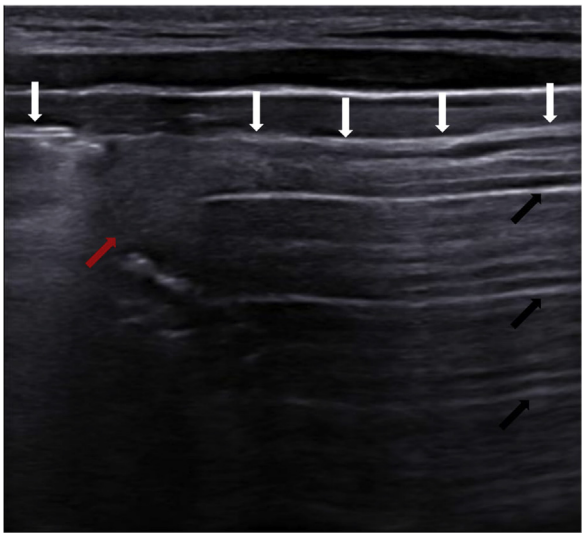

Figure 2 – *On cervical ultrasound, the longitudinal scan of the right thyroid lobe partly shows the apical region of gland (red arrow) due to the acoustic barrier. The latter is created by the presence of air in the tissues (white arrows) producing the ultrasound artifacts, defined as "A-lines" (black arrows).*

(Fig 2). On a coronal scan, this gas artifact altered the typical "butterfly image" of the thyroid (Fig 3, Video 1), suggestive of the presence of subcutaneous emphysema. Lung views showed multiple hyperechoic artifacts among the intercostal fascial planes with a "gaseous band-like" appearance and bilateral pleural sliding, compatibly with pneumomediastinum without evidence of pneumothorax, infiltrate, or effusion (Fig 4, Video 2, Narration Video).

CT imaging is crucial for the detection of pneumorrhachis (PR). Given imaging technology improvements and the increased use of chest CT scanning for SMP cases, it is likely that PR recognition will rise, specifically when SPM is severe and extensive.[9]

Pathologic Discussion

PR describes the clinical finding of air within the spinal canal, and it rarely occurs in patients with SPM.[10] The association between PR and SPM is not fully understood, especially when accompanied by asthma exacerbation. PR may occur directly (trauma), as when atmospheric air enters the epidural space, or indirectly (spontaneous),[11] as in the current case. Air that has gone into the pulmonary perivascular interstitium migrates along fascial planes and moves from the posterior mediastinum (or retropharyngeal space) to the epidural space of the cervical and thoracic spine through the neural foramina.[12] The cause of PR has been associated with alveolar rupture secondary to an acute increase in

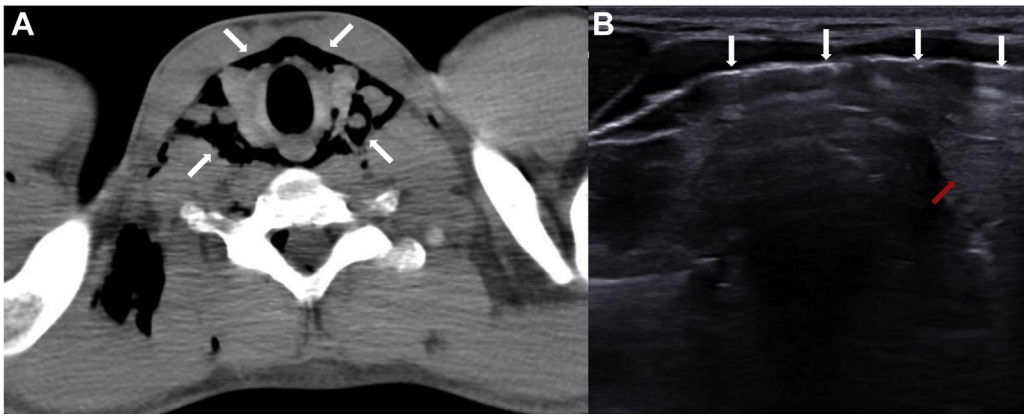

Figure 3 – *The air is visible in the surrounding thyroid parenchyma on the axial view both of cervical CT imaging (white arrows) (A) and cervical ultrasound (B). In the latter, the acoustic barrier prevents the visualization of the underlying tissues (white arrows), with the exception of a portion of the left thyroid lobe (red arrow).*

the transalveolar pressure gradient.[10] It was shown that this damage is responsible for the dissection of bronchovascular sheaths and the subsequent air dissemination; the latter is made possible by the lack of boundaries in muscle bundles.[2,13] This event, called the "Macklin effect," is frequently linked to traumatic injury. However, it can also occur in patients with disorders causing respiratory distress or increased intrathoracic pressure, such as mechanical ventilation or the Valsalva maneuver.[14]

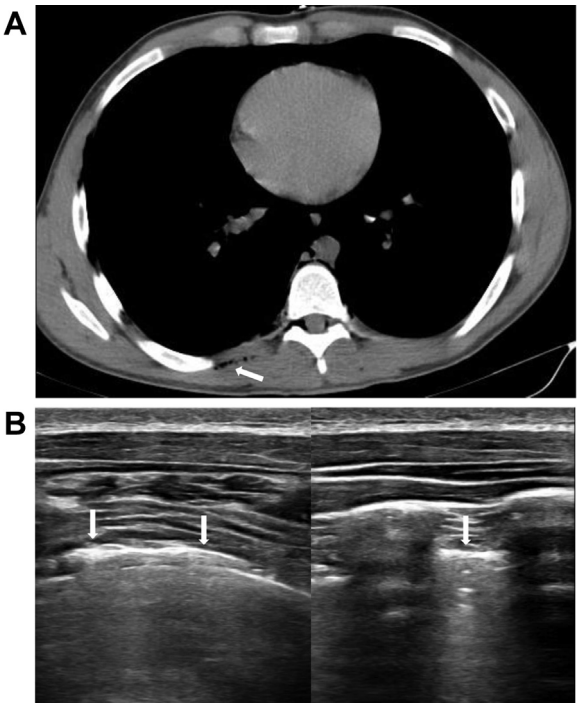

Figure 4 – *A, On the axial view of chest CT imaging, the air is visible among the intercostal fascial planes (white arrow). B, On sagittal and axial scans of ultrasound, the air interposed among the intercostal fascial planes generates a hyperechoic band (white arrows).*

Conclusions

The management of SPM is supportive care because the diagnosis is essentially benign. The patient was treated with oxygen administration (3 L/min), bronchodilators (salbutamol), systemic steroids, and antibiotics. After 24 h, a sonographic examination showed a partial reduction of gas in the neck (Fig 5). The patient was discharged on day 5. Findings from sonographic follow-up 1 month later were normal (Fig 6). Following hospitalization, the patient's spirometry showed an FEV_1/FVC ratio of 94%, with an FEV_1 of 4.77 L (110% of predicted) that improved to 5.33 L (12%) following the bronchodilator test. After the episode presented herein, the patient

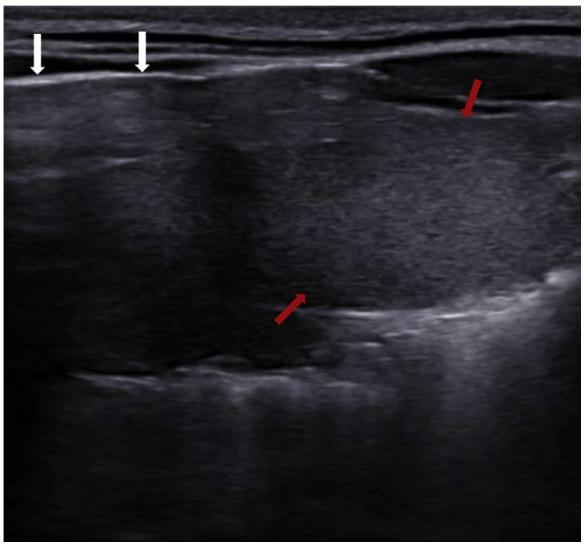

Figure 5 – *After 24 h from hospital admission, the ultrasound cervical sagittal scan shows the reduction of the acoustic barrier (white arrows) due to the air absorption, with major visualization of the right thyroid lobe (red arrows).*

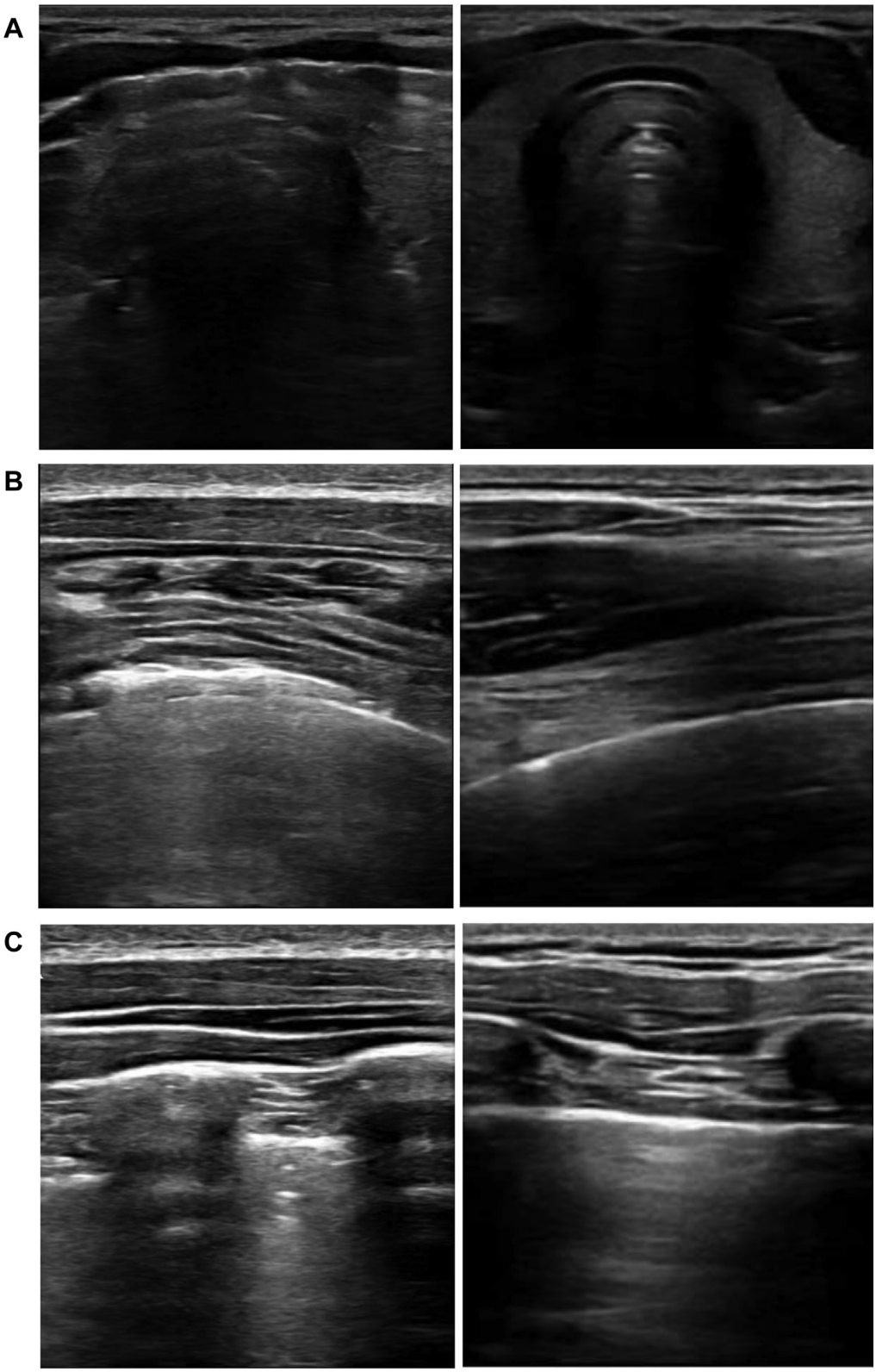

Figure 6 – *A, The ultrasound of the neck on the axial view of the thyroid gland. On the left, the acoustic barrier makes visualization of the "butterfly image" of the thyroid difficult due to the air into the soft tissues of the neck; on the right, following 1 month from hospital admission, the complete resolution of subcutaneous emphysema makes the butterfly image visible. B, The lung ultrasound on the axial view. On the left, the "gaseous band-like" appearance makes complete visualization of the underlying pleural line and regular A-lines difficult due to the air present among the intercostal muscles; on the right, following 1 month from hospital admission, the complete resolution of the pneumomediastinum allows visualization of the underlying tissues and physiological artifacts. C, The lung ultrasound on the sagittal view in the paravertebral site. On the left, the pathological condition due to the gaseous band-like appearance as previously indicated; on the right, following 1 month from hospital admission, the regular ultrasonography pattern.*

started a long-term treatment that was based on inhaled corticosteroids.

This case supports the use of bedside point-of-care ultrasound (POCUS) to aid in the rapid recognition of this less common cause of chest pain and to reduce the execution of serial radiographs in the follow-up of the patient. When investigating chest pain, SPM may be suspected when an echocardiogram shows poor visualization of the butterfly image of the thyroid and multiple hyperechoic artifacts among the intercostal fascial planes with a "gaseous band-like" appearance in the chest wall. Finally, we highlight the uncommon association between epidural PR, which is rarely reported in literature, and asthma exacerbation.

Reverberations

1. *POCUS is a useful diagnostic tool that can be obtained nearly immediately, and the clinician can use real-time dynamic images, allowing findings to be directly correlated with the patient's clinical status.*
2. *POCUS can aid in the rapid recognition of SPM and reduce the execution of serial CXR in the follow-up of patients with SPM.*
3. *Direct ultrasound signs of SPM include the presence of hyperechoic artifacts among the intercostal fascial planes with a gaseous band-like appearance and bilateral pleural sliding.*
4. *Indirect ultrasound signs of SPM include the unusual presence of vertical comet tails in the anterolateral region of the neck and the poor visualization of the butterfly image of the thyroid.*
5. *PR is a rare complication of SPM and might be triggered in patients with an asthma exacerbation.*

Acknowledgments

Financial/nonfinancial disclosures: None declared.

Other contributions: The authors thank the patient and his parents for their support of this study, as well as all the investigators and nurses of the Department of Pediatrics, University of Chieti, for their daily support in clinical research and care of children. They thank Dr Rosa Lucia Patea, MD, and Dr Manuela Mereu, MD, for their contribution in the radiologic diagnosis. Furthermore, they thank Prof. Simon Cunningham for providing language help. Finally, the authors thank the investigators of the Department of General and Thoracic Surgery for their support in the management of the patient. *CHEST* worked with the authors to ensure that the Journal policies on patient consent to report information were met.

Additional information: To analyze this case with the videos, see the online version of this article.

References

1. Megremis S, Stefanaki S, Tsekoura T, Tsilimigaki A. Spontaneous pneumomediastinum in a child: sonographic detection in a case with minimal findings on chest radiography. *J Ultrasound Med.* 2008;27(2):303-306.
2. Okada M, Adachi H, Shibuya Y, Ishikawa S, Hamabe Y. Diagnosis and treatment of patients with spontaneous pneumomediastinum. *Respir Investig.* 2014;52(1):36-40.
3. Sahni S, Verma S, Grullon J, Esquire A, Patel P, Talwar A. Spontaneous pneumomediastinum: time for consensus. *N Am J Med Sci.* 2013;5(8):460-464.
4. Wong KS, Wu HM, Lai SH, Chiu CY. Spontaneous pneumomediastinum: analysis of 87 pediatric patients. *Pediatr Emerg Care.* 2013;29(9):988-991.
5. Ng L, Saul T, Lewiss RE. Sonographic evidence of spontaneous pneumomediastinum. *Am J Emerg Med.* 2013;31(2):462.e3-462.e4.
6. Newman B, Callahan MJ. ALARA (as low as reasonably achievable) CT 2011—executive summary. *Pediatr Radiol.* 2011;41:453-455.
7. Reid CL, Chandraratna AN, Kawanishi D, et al. Echocardiographic detection of pneumomediastinum and pneumopericardium: the air gap sign. *J Am Coll Cardiol.* 1983;1(3):916-921.
8. Testa A, Candelli M, Pignataro G, Costantini AM, Pirronti T, Silveri NG. Sonographic detection of spontaneous pneumomediastinum. *J Ultrasound Med.* 2008;27(10):1507-1509.
9. Liu YW, Kao CN, Wang YM. Pneumorrhachis: an under-recognized entity correlates with severity of spontaneous pneumomediastinum. *J Thorac Dis.* 2018;10:e149-e151.
10. Pérez Frutos MD, Cerezo Arias MO, Córdoba López A, Granado Martínez D. Neumorraquis: una rara complicacion de una crisis asmatica [in Spanish]. *Med Intensiva.* 2011;35(2):130-131.
11. Borem LMA, Stamoulis DNJ, Ramos AFM. A rare case of pneumorrhachis accompanying spontaneous pneumomediastinum. *Radiol Bras.* 2017;50:345-346.
12. Sadarangani S, Patel DR, Pejka S. Spontaneous pneumomediastinum and epidural pneumatosis in an adolescent precipitated by weight lifting: a case report and review. *Phys Sportsmed.* 2009;37:147-153.
13. Macklin CC. Transport of air along sheaths of pulmonic blood vessels from alveoli to mediastinum: clinical implications. *Arch Intern Med.* 1939;64:913-926.
14. Wintermark M, Schnyder P. The Macklin effect: a frequent etiology for pneumomediastinum in severe blunt chest trauma. *Chest.* 2001;120(2):543-547.