

## Platelet-rich plasma (PRP) intra-articular ultrasound-guided injections as a possible treatment for hip osteoarthritis: a pilot study

Sirs,

Osteoarthritis (OA) of the hip is the most common joint disorder, with a prevalence of 17% in men and 9% in women in the white population over 60 years of age (1). The initial treatment usually comprehends reduced activity, weight loss, supports, physiotherapy, analgesic and non-steroidal anti-inflammatory drugs (2). Intra-articular injections of corticosteroids or hyaluronic acid can also be administered as a symptomatic treatment (2). Nevertheless, these therapies are associated with important side effects and are not able to change the progression of the degenerative process. Prosthesis remains the ultimate solution (2).

The increasing knowledge of cartilage reparative mechanisms and the pathogenesis of OA have given rise to new possible therapeutic targets (3). Growth factors contained in platelets  $\alpha$ -granules have been found to have a positive effect on cartilage regeneration and down-regulation of inflammatory mediators (4). Based on these evidences, an increasing interest has been shown in the use of platelet-rich plasma (PRP), an autologous product derived from the centrifugation of whole blood, which contains a platelet concentration four to eight times higher than that of normal blood, and high levels of growth factors. Recent studies have demonstrated the efficacy of PRP intra-articular injections in patients affected with knee OA (5).

The primary objective of this pilot study was to evaluate the safety and efficacy of PRP ultrasound-guided injections in patients affected with hip OA, through the evaluation of clinical outcomes. To our knowledge, this is the first report related to this method in hip OA.

Twenty patients (13 men and 7 women) were enrolled in a prospective clinical trial. The mean age was  $52 \pm 13$  (range 28–69) years and the mean BMI was  $25 \pm 3$ . All patients presented chronic unilateral symptomatic osteoarthritis of the hip, proved by antero-posterior radiograph of the pelvis and classified according to Kellgren and Lawrence score (6) as early stage or grade II (4 patients), moderate stage or grade III (8 patients) and severe stage or grade IV (8 patients). A unit of 5 ml of PRP was administered by ultrasound-guided injections, one every two weeks, for a total of 3 times. The assistance of real-time ultrasound-guidance for intra-articular hip injections has been recommended by various authors (7).

The patients were clinically evaluated at baseline and at the 1-, 3-, 6- and 12-month

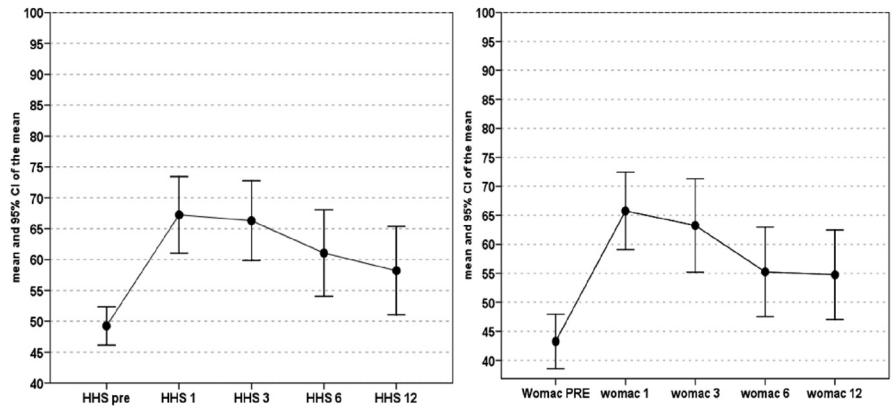


Fig. 1. Clinical results of HHS and WOMAC score.

follow-up after the third injection using the Harris Hip score (HHS) (8) and Western Ontario and McMaster Universities Osteoarthritis Index (WOMAC) (9).

No major complications or adverse events occurred at the moment of injection or in the follow-up period. Ten patients reported a slight pain during or after the injection, which spontaneously resolved in 1 or 2 days.

The administration of PRP is associated with a general statistically significant clinical improvement. Both HHS and WOMAC scores improved (Fig. 1) from  $49 \pm 7$  and  $43 \pm 10$  to  $58 \pm 15$  and  $54 \pm 17$ , respectively, at the 12-month follow-up ( $p=0.001$  HHS,  $p=0.005$  WOMAC). In any case, from an initial peak of clinical improvement observed at the 1- to 3-month follow-up ( $p<0.0005$ ), an abrupt decrease of the results was noticed from the 3- to 6-month follow-up for the WOMAC score ( $p=0.004$ ), while the HHS score showed a slight progressive worsening over time. Overall, both scores remained significantly higher at the 12-month follow up with respect to the basal level.

In contrast with a previous study on the knee in which young patients with a lower BMI and OA grade had a better outcome after PRP injections (5), in our study no correlation was found between sex, age, BMI, AO grade and clinical outcomes.

These preliminary results show that PRP injections are safe and effective in reducing pain, improving articular function and quality of life in patients affected by hip osteoarthritis.

M. BATTAGLIA MD<sup>1</sup>  
 F. GUARALDI, MD<sup>2</sup>  
 F. VANNINI, MD, PhD<sup>3</sup>  
 T. BUSCIO, MD<sup>3</sup>  
 R. BUDA, MD<sup>3</sup>  
 S. GALLETI, MD<sup>1</sup>  
 S. GIANNINI, MD<sup>3</sup>

<sup>1</sup>Service of Ecography and Radiology, Rizzoli Orthopaedic Institute, Bologna, Italy;

<sup>2</sup>Department of Pathology, The Johns Hopkins University School of Medicine, Baltimore, MD, USA;

<sup>3</sup>Clinical Orthopaedic and Traumatology Unit II, Rizzoli Orthopaedic Institute, Bologna, Italy.

Please address correspondence and reprint requests to: Milva Battaglia, MD, Servizi di Ecografia e Radiologia, Istituto Ortopedico Rizzoli, Via Pupilli, 2 40136 Bologna, Italy.  
 E-mail: milva.battaglia@ior.it

Competing interests: none declared.

### References

- ROUX CH, SARAUX A, MAZIERES B *et al.*: KHOALA OSTEOARTHRITIS GROUP: Screening for hip and knee osteoarthritis in the general population: predictive value of a questionnaire and prevalence estimates. *Ann Rheum Dis* 2008; 67: 1406-11 [Epub 2007 Dec 12].
- HOCHBERG MC, ALTMAN RD, BRANDT KD *et al.*: Guidelines for the medical management of osteoarthritis. Part I. Osteoarthritis of the hip. American College of Rheumatology. *Arthritis Rheum* 1995; 38: 1535-40.
- LOESER RF: Aging and osteoarthritis: the role of chondrocyte senescence and aging changes in the cartilage matrix. *Osteoarthritis Cartilage* 2009; 17: 971-9.
- ANITUA E, ANDIA I, ARDANZA B *et al.*: Autologous platelets as a source of proteins for healing and tissue regeneration. *Thromb Haemost* 2004; 91: 4-15.
- FILARDO G, KON E, BUDA R *et al.*: Platelet-rich plasma intra-articular knee injections for the treatment of degenerative cartilage lesions and osteoarthritis. *Knee Surg Sports Traumatol Arthrosc* 2010; Aug 26 [Epub ahead of print].
- KELLGREN JH, LAWRENCE JS: Radiological assessment of osteoarthritis. *Ann Rheum Dis* 1957; 16: 494-502.
- QVISTGAARD E, KRISTOFFERSEN H, TERSLEV L *et al.*: Guidance by ultrasound of intra-articular injections in the knee and hip joints. *Osteoarthritis Cartilage* 2001; 9: 512-7.
- HARRIS WH: Traumatic arthritis of the hip after dislocation and acetabular fractures: treatment by mold arthroplasty. An end-result study using a new method of result evaluation. *J Bone Joint Surg Am* 1969; 51: 737-55.
- THEILER R, SPIELBERGER J, BISCHOFF HA *et al.*: Clinical evaluation of the WOMAC 3.0 OA Index in numeric rating scale format using a computerized touch screen version. *Osteoarthritis Cartilage* 2002; 10: 479-81.