

## CASE REPORT

# Safe clinical technique for increasing the occlusal vertical dimension in case of erosive wear and missing teeth

Camillo D'Arcangelo | Mirco Vadini | Matteo Buonvivere | Francesco De Angelis 

Department of Medical, Oral and Biotechnological Science, Unit of Restorative Dentistry and Endodontics, School of Dentistry, "G. D'Annunzio" University of Chieti, Chieti, Italy

## Correspondence

Francesco De Angelis, Unit of Restorative Dentistry and Endodontics, Department of Medical, Oral and Biotechnological Science, School of Dentistry, "G. D'Annunzio" University of Chieti, Via dei Vestini 31, 66100, Chieti, Italy.  
Email: fda580@gmail.com

## Abstract

A safe method to increase the occlusal vertical dimension (OVD) in patients with mild temporomandibular symptoms (such as tenderness upon palpation) is described. After a temporomandibular joint magnetic resonance (MR), an OVD increase was sought, pursuing pure rotational movement without condyle displacement. Prior to definitive rehabilitation, an additional MR confirmed steady and healthy condyle-disc-fossa relationships.

## KEYWORD

dentistry,

## 1 | INTRODUCTION

In modern dentistry, the esthetic outcome has to be considered an inherent element of every restorative and prosthetic treatment. Achieving a pleasant aspect is definitely as important as restoring a proper function or preserving an optimal biology. In the most simple clinical cases involving the esthetics of frontal teeth, there is no need to bring any change to the patient occlusal vertical dimension (OVD): The occlusion is already properly balanced and there is enough interocclusal space to esthetically improve the patient smile.<sup>1</sup> In other cases, on the contrary, the presence of generalized tooth wear and/or significant occlusal irregularities (ie, malocclusions) frequently involving both anterior and posterior teeth, might complicate or prevent the introduction of esthetic improvements if the OVD is left unchanged.<sup>2-4</sup> Despite the existence of a broad consensus regarding a limited OVD increase as a clinically safe procedure, there is still considerable debate in the literature concerning the proper procedures to successfully and reliably increase the OVD.<sup>5-9</sup>

Most authors seem to indicate that increasing the OVD of asymptomatic patients does not lead to the development of temporomandibular disorder (TMD) symptoms.<sup>10</sup> According to Abduo,<sup>6</sup> since any restorative material can be applied on the occlusal surface in a space of 2 mm,<sup>11,12</sup> a 4 mm interarch space (and an OVD increase within 5 mm interincisally) should be always considered adequate for a comprehensive rehabilitation and safe from the clinical perspective, on the condition that the patient does not have TMJ problems. However, it should be noted that the studies investigating the relationship between increasing OVD and TMD symptoms were all conducted on relatively small changes in OVD, likely within the freeway space.<sup>13,14</sup> Larger OVD changes have not been well studied.<sup>10</sup> Some articles have challenged the hypothesis of the negative implications of increasing OVD even beyond the limit of the interocclusal rest space.<sup>15,16</sup> In general, their outcomes keep on reflecting the safety, patient adaptation, and predictability of increasing the OVD in relation to TMJ and masticatory muscle health, but, as observed by Abduo in 2012, the available studies about this specific topic suffer

This is an open access article under the terms of the Creative Commons Attribution-NonCommercial-NoDerivs License, which permits use and distribution in any medium, provided the original work is properly cited, the use is non-commercial and no modifications or adaptations are made.

© 2021 The Authors. *Clinical Case Reports* published by John Wiley & Sons Ltd.

from a lack of randomization and control group; in addition, significant variation exists in relation to the subjective methods to assess patient adaptation and all the available studies had a limited number of participants, so that it could be assumed that they are not completely representative of the whole population.<sup>6</sup>

Even if the currently available evidence suggests a low causal effect of the occlusion on the genesis and the development of TMD problems, that does not make it fair to suppose the total absence of any relationship.<sup>17</sup> Among the findings of the Study of Health in Pomerania (one of the largest cross-sectional investigations about occlusal parameters and TMD signs and symptoms carried out between October 1997 and May 2001 in Western Pomerania, Germany, and including 4310 individuals between 20 and 81 years of age), a robust association (odds ratio >2) between some occlusal factors and TMDs was observed, although a causal relationship could not be demonstrated because of a lack of time sequence.<sup>18</sup> Moreover, according to Türp & Schindler,<sup>19</sup> acute occlusal interventions, such as an occlusal splint placement or an irreversible prosthetic treatment, differ from a long-standing occlusal situation, where an existing occlusion with working, non-working, retrusive and protrusive altered contacts may have been emerging over a period of several years. In a randomized double-blind trial, an acute occlusal change increased the risk of developing TMD signs (such as tenderness upon palpation),<sup>20</sup> especially on patients with a former successfully treated TMD history.<sup>21</sup> The inherent adaptive capacity of the masticatory system may decrease over time and get significantly compromised.<sup>22</sup> Under these circumstances, an acute occlusal alteration might unexpectedly act like a “stumbling block,”<sup>23</sup> making it worth any possible attempt of preserving the present occlusal balance.

In many cases, the patient might show mild TMD symptom, even not related to an altered preoperative condyle-fossa relationship; nevertheless, the occlusion needs to be changed and improved, eventually increasing the OVD, in order to esthetically and successfully manage the requested restorative task. Based on the above considerations, those cases of mere malocclusion seem quite risky, as they hide the clinical hazard of lifting up the vertical dimension (modifying the mandibular position and introducing an acute occlusal change) with the imperative duty of preserving the valuable temporomandibular balance that the patient might have found, despite the long-lasting occlusal alterations.<sup>24,25</sup> An objective and predictable method, able to safely guide the clinician throughout such a tricky procedure, seems definitely required.

Over the last years, the introduction of increasingly sophisticated temporomandibular joint imaging techniques has been representing an important breakthrough in the direction of a better understanding of TMJ physiology

and a correct definition of the proper condyle-fossa relationship.<sup>26</sup> Magnetic resonance (MR) and cone beam computed tomography (CBCT) are nowadays considered suitable diagnostic choices for the assessment of the normal appearance of TMJ in healthy patients<sup>27</sup> and have been successfully used to achieve a visual representation of different pathologic conditions affecting the temporomandibular joint.<sup>28</sup> While CBCT has been recommended for the evaluation of osseous joint components, cortical bone integrity, and subcortical osseous abnormalities, MR has been acknowledged as the ideal diagnostic tool for the assessment of disc-condyle relation, soft-tissues deformity, internal derangement, and presence of abnormal fluids. MR imaging represents therefore a reliable choice to examine TMJ morphology without the radiation exposure concerns of the CBCT.

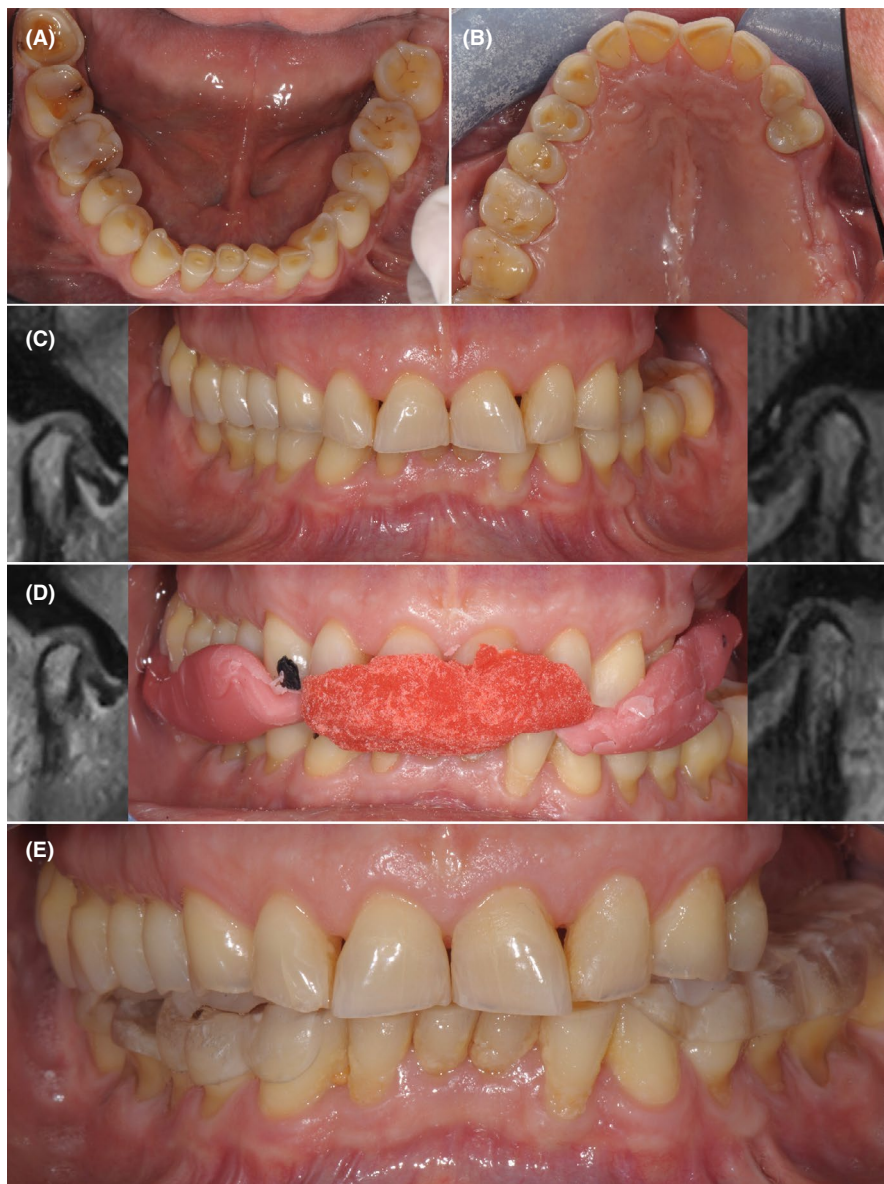
The present clinical report describes a safe clinical workflow put in place to esthetically restore the smile of a patient affected by extensive dental erosions and occlusal abnormalities. An MR imaging-based diagnostic approach was used to assess a healthy preoperative condyle-fossa relationship and to keep it unchanged throughout the whole treatment.

## 2 | CASE PRESENTATION

A 60 years-old man presented with a chief complaint concerning the unpleasant esthetic of his smile. The patient's medical history was unremarkable and he was taking no medication. The intraoral examination revealed extensive erosive tooth wear involving anterior and posterior teeth on both upper and lower arches, signs of cervical abrasion/erosion, and missing of 2.5, 2.6, 2.7 elements (Figure 1A,B). Old composite fillings were present on teeth 1.5, 1.6, 2.3, 4.6, and 4.7, but all elements were vital. Despite the evident occlusal problems, the patient did not report any spontaneous symptoms of TMD. The clinical examination revealed the presence of a mild palpation-induced pain to the masticatory muscles (lateral pterygoid and masseter) and to TMJ. The treatment plan consisted of a full-mouth adhesive and additive rehabilitation, aiming to improve the esthetics with minimal tooth preparation, after having established a new and increased OVD.

The first stage of the treatment dealt with the maxillary sinus augmentation and implants placement, in order to allow the rehabilitation of the upper left edentulous area. A lateral window sinus lift was initially performed using a granular bone substitute (Endobon Xenograft Granules, Zimmer Biomet Dental, Palm Beach Gardens) and platelet-rich plasma (PRP). After 6 months, two fixtures with a 13 mm length and a 4 mm diameter (Universal II

**FIGURE 1** Clinical procedures adopted to verify the temporomandibular joint condition while increasing the vertical dimension of occlusion. (A,B) Preoperative intraoral occlusal photographs showing generalized erosive tooth wear and occlusal abnormalities: esthetics appears negatively affected. (C) A preoperative temporomandibular joint magnetic resonance scan was taken, with the patient in maximum intercuspation, showing healthy and balanced condyle-disc-fossa relationship both on left and right side. (D) A second temporomandibular joint magnetic resonance scan was taken with patient dressing the anterior resin jig, with the aim of checking the temporomandibular joint status in the new mandibular position. (E) Temporary resin splints cemented on mandibular posterior teeth



CM Implacil De Bortoli; Implacil De Bortoli) were placed in the edentulous area following a submerged protocol.

During the submerged healing of the fixtures, all the subsequent prosthetic steps were carefully planned. The mild pain, preoperatively observed on palpation of masticatory muscles and TMJs, suggested the need of better investigating the actual TMJ status, in order to exclude the chance of additional dysfunctions affecting TMJ and the associated structures. The presence of physiological and healthy preoperative TMJ conditions was objectified by MR imaging sequences taken in maximum intercuspitation using a 3 Tesla MRI system (Philips Ingenia 3.0 T; Philips Medical Systems, The Netherlands) with 6-channel dS Flex M surface coil. T1-weighted sagittal sequences with a 2 mm slice thickness were obtained for each TMJ. Both condyles appeared well centered within the glenoid cavities, in an anterior-superior position against the slope

of the articular eminences (Figure 1C), in this specific position, the condylar movement is considered to be restricted to pure rotation about the transverse horizontal axis.<sup>29</sup> Based on the objective MR evaluation and due to the absence of severe and spontaneous TMD signs/symptoms (with the exception of mild pain on palpation), the current preoperative condyle-disc-fossa relationship was assumed as properly balanced and care was taken to preserve it unchanged throughout the treatment, trying to confine the required OVD increase within the limit of pure condylar rotation.

After having placed a standard cheek/lip retractor, the patient was asked to slightly and slowly open the mouth starting from the maximum intercuspitation, avoiding any kind of operator-guided manipulation and without any bite registration medium in between upper and lower arches. A degree of tooth separation was sought, so as to

guarantee enough interocclusal space for the restorative purpose but trying not to overcome the condylar pure rotation limits. Taking into account the restorative needs, an OVD increase of 6 mm interincisally was supposed as appropriate. An indelible marker was used to mark the upper and lower canines and central incisors, in order to make any subsequent placement of the mandible in this new position easy and repeatable. Two softened 3-layer wax wafers (3 mm each) were pushed against the cusps of left and right mandibular posterior teeth. The patient was then asked to close, while the operator guided the mandible using the marker signs on incisors and canines as a reference to avoid any undesired excursive movement. The wax wafers were removed, chilled, and re-seated in order to check fit, stability, and accuracy. Following a facebow transfer, preoperative casts were mounted on a semi-adjustable articulator (SAM 2P; SAM Präzisionstechnik GmbH) using the wax wafers as intermaxillary records. After having achieved an esthetically satisfactory full-mouth wax-up thanks to the free interocclusal space provided by the OVD increase, the wax-up on posterior teeth was removed. From the ensuing partial/anterior wax-up, upper and lower silicon keys were prepared, extending from left to right second premolar, and loaded with a tooth-colored self-curing temporary acrylic resin material (EnaTemp; Micerium S.p.A.) in the patient's mouth. Since premolars had been removed from the wax-up, the silicon keys were stable in the mouth thanks to the presence of a distal stops. The resulting anterior mock-up allowed for a basic but essential intraoral esthetic validation of the proposed restorative project.

The hypothesis that the new mandibular position, in the arbitrarily proposed OVD, was actually within the limit of condylar pure rotation still required, at that moment, an objective support. For this purpose, the mock-up was removed. An anterior jig was manufactured intraorally, by adapting an amount of self-curing low shrinkage acrylic pattern resin (TempRed; Micerium S.p.A.) at the dough stage to the upper anterior teeth and asking the patient to bite with the posterior wax wafers in place. After resin setting, the jig was removed and re-seated to check for an easy fit. The patient was then subjected to a second TMJ MR evaluation while dressing the anterior resin jig, using the same parameters and the same sagittal sequences described for the preoperative examination (Figure 1D). Comparing pre- and postoperative MRs, the condylar and disc positions appeared substantially unchanged in respect to the articular fossa, which confirmed the proposed OVD increase could be safely considered within the limits of a pure rotation.

Despite that, an additional diagnostic step aimed to clinically verify in a completely reversible way the actual patient adaptation to the new mandibular position was

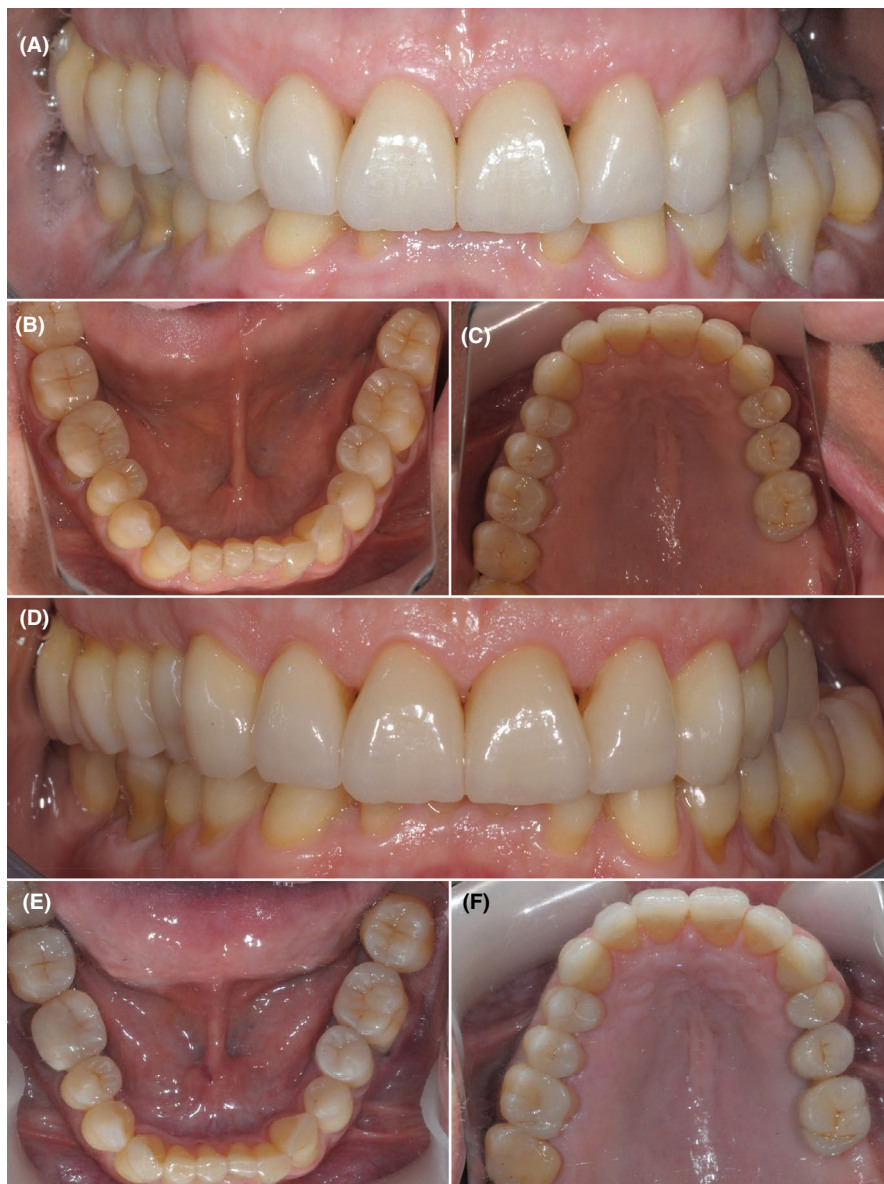
planned. Using the wax wafers and the resin jig as interocclusal records, temporary and additive posterior splints were manufactured on the preoperative casts using orthodontic acrylic resin (Orthocryl; Dentaaurum) and salt-and-pepper technique. The splints extended bilaterally from the first lower premolar to the second lower molar and were cemented intra-orally on the unprepared teeth using glass-ionomer cement (Ketac Cem; 3 M ESPE), in order to exclude the possibility of removal by the patient (Figure 1E). After two months, the patient reported a comfortable self-adaptation to the new mandibular position, no signs of TMD were detectable and muscles did not show any tenderness on palpation: these findings provided the ultimate validation required.

The subsequent prosthetic finalization was performed using the splint-induced occlusal position as intermaxillary relationship. Keeping the fixed splints in place, polyvinylsiloxane impressions of the upper and lower arches were taken. In order to avoid additional facebow transfers, the poured casts were placed on to the articulator according to the cross-mounting technique and were used to fabricate indirect resin composite palatal veneers (Enamel Plus Hri Function; Micerium S.p.A.) for the six maxillary anterior teeth and to carry out the final wax-up of the six lower anterior teeth. The palatal veneers were adhesively luted, while a lingual silicon key guided the direct composite restoration of the lower anterior teeth.

In this way, an anterior occlusal contact was re-established and the open-bite was closed, allowing a safe removal of the left-side fixed splint and the consequent restoration of both upper and lower left premolars and molars. Sound posterior teeth were left unprepared. Old fillings and/or decays were removed; the resulting cavities were filled with direct composite build-ups and included into minimally invasive indirect overlay preparations. Polyvinylsiloxane impressions of the upper and lower arches were taken, keeping the right-side fixed splint in place. Resin-based composite (Enamel Plus Hri Function) indirect restorations were manufactured, using standard laboratory procedures, adhesively luted, and subjected to minimal intraoral occlusal corrections; in the same session, the gold composite implant-supported fixed dental prostheses replacing teeth number 2.5 and 2.6 were delivered. With steady and definitive occlusal contacts on left and anterior sectors, the right-side fixed splint was removed and both upper and lower right premolars and molars were restored as just described for the left side. Eventually, with the aim of enhancing the esthetics of the anterior group, the six maxillary anterior teeth were subjected to a minimal veneer preparation and restored with adhesively luted buccal lithium-disilicate veneers.<sup>30</sup>

After one week, the patient was recalled in order to collect postoperative clinical photographs (Figure 2A–C).

**FIGURE 2** Intraoral details of the delivered final rehabilitation. (A–C) Postoperative frontal and occlusal view. (D–F) Follow-up after 5 years: intraoral frontal and occlusal photographs



Subsequently, the patient was scheduled for yearly recalls and was instructed to contact the clinic in case of any possible problem involving the treated teeth and the delivered restorations. After 5 years follow-up, the achieved esthetic and functional outcome appeared successfully preserved (Figure 2D–F) and the patient was still completely satisfied with the clinical result. Shallow wear facets were observed on the occlusal surfaces of premolars and on the incisal margins of lower incisors after 5 years of clinical service, probably due to the minimal persistence of some parafunctional activities, such as grinding and clenching.

### 3 | DISCUSSION

A full-mouth adhesive rehabilitation of a patient showing generalized erosive tooth wear and a severe malocclusion

was performed using MR imaging to keep under control the TMJ conditions throughout the treatment.

The presence of a mild tenderness on palpation of masticatory muscles in the absence of spontaneous preoperative symptoms confirms that an OVD loss or a malocclusion is not always associated with a severe clinical TMJ impairment. Mild TMJ symptoms, such as muscle tenderness, can be related to grinding/bruxism parafunctions, rather than to the OVD loss itself. Nevertheless, when in similar situations a full-mouth rehabilitation is required for esthetic purposes, it could be wise to limit the introduction of additional occlusal changes since they could become detrimental if the TMJ was just precariously balanced.<sup>20–23</sup>

This could be rashly and wrongly considered an easy task, while is in truth a very tough clinical challenge, since every mandible repositioning procedure is likely to introduce a certain extent of undesired disc/condyle

displacement, possibly disrupting the previous musculoskeletal balance. A proper compromise should be found, between an effective OVD increase and the safe preservation of the pre-existing TMJ conditions. Three-dimensional imaging (MR) appears essential to reach such a compromise.

After having confirmed the presence of a healthy pre-operative condyle-disc-fossa relationship by means of an objective MR examination, according to the proposed clinical workflow, a new mandibular position was arbitrarily supposed, at an increased OVD, taking advantage by the fact that, physiologically, the first phase of mouth opening is mainly due to a pure rotation of the mandible.<sup>31,32</sup>

This concept has been for years the basis of the jaw movement description in terms of rotation and translation. However, the classical assumption that the pure rotation strictly corresponds to the first 20–25 mm of incisal opening<sup>31,32</sup> has been often source of misinterpretation. Löter et al. observed that already during the first interval of opening a displacement of the condyles may occur, even if they definitely demonstrated how near intercuspal contact position and close to the maximum mouth opening the condylar displacements are smaller than in the other movement intervals.<sup>33</sup> The actual limit for a mouth opening movement occurring with no (or with a minimal) condyle displacement should be more conveniently considered as a patient-dependent variable, realistically increased in case of worn dentition and consequent loss of the original vertical dimension. A three-dimensional imaging evaluation of the TMJ is the only objective way to irrefutably verify or reject the hypothesis that the condyle stands still during the mandibular movements.

In the present clinical report, the new mandibular position was determined avoiding any operator-guided recording technique. Since the introduction of the Lucia jig in<sup>34</sup> different kind of operator-guided (such as Dawson's bimanual manipulation method, chin-point and three-finger chin-point guidance method, leaf-gauge method, and power-centric method) or patient-guided (such as Schuyler method, Gothic arch tracing method, and myo-monitor method) centric relation recording techniques have been successfully employed by every respective supporter and simultaneously opposed by dissidents. As a consequence, several different techniques nowadays exist, which have been proposed over the past decades in order to accomplish exactly the same task: steadily placing the condyle into the “right” position.

Interestingly, the concept itself of centric relation underwent a remarkable evolution over years, moving from “the most posterior relation of the lower jaw from which lateral movements can be made” (according to Boucher),<sup>35</sup> to the “position of the mandible placing both condyles

into their anterior uppermost position” (as independently stated by both Ramsfjord and Ash in 1993)<sup>36</sup> and to the “maxillomandibular relationship in which the condyles articulate in the anterior-superior position against the posterior slopes of the articular eminences and the mandible is restricted to a purely rotary movement” (as defined by the Glossary of Prosthetic Terms, 9<sup>th</sup> edition).<sup>29</sup> The real impetus for that shift in centric relation definition has been precisely given by the introduction (and the subsequent wide spread) of sophisticated three-dimensional TMJ imaging, which could finally reveal the actual condylar position.<sup>26</sup> As a consequence, without any prejudice to the traditional recording techniques that keep on being definitely useful, three-dimensional imaging (such as MR) should be nowadays considered the most reliable method to irrefutably confirm (or reject) the hypothesis that the conditions described in the latest “centric relation” definitions are actually fulfilled.

A second MR with the patient dressing the resin jig as interocclusal record may provide an objective confirmation of altered/unaltered TMJ conditions compared to the start point. In case of satisfactory MR validation of the proposed OVD increase, the use of temporary and additive fixed splints represents an additional non-invasive diagnostic step aimed at warding off any risk of irreversible TMJ impairment due to the recently introduced acute occlusal change.<sup>19,20,23</sup> If any TMJ problem or muscular reaction was detected over this reversible 2 months-lasting phase, the initial occlusal conditions could be easily restored by simply removing the fixed splints. Among the several advantages provided by this clinical workflow, the immediate proof of a possible condyle displacement and the objective awareness about the actual jaw/condyle/disc positions before the beginning of any irreversible therapy appear particularly important.

In the present clinical report, after 2 months of temporary and reversible splint-based treatment, the patient confirmed a comfortable self-adaptation to the new OVD and this allowed a safe and definitive prosthetic finalization, preserving the splint-induced intermaxillary position. An accurate disc and condyle position control (by means of MR) and an appropriate muscle and TMJ deconditioning (thanks to the fixed bites) definitely enhanced the predictability and the long-term stability of the achieved results, as confirmed by the 5 years follow-up. The wear facets observed after 5 years on premolars and on lower incisors confirm the possible persistence of some parafunctional activities, which might have a mainly psychosomatic etiology, and suggest that rather seldom bruxism is completely resolved following an occlusal/restorative treatment. As a consequence, especially when dealing with extensive occlusal rehabilitations, the use of restorative materials showing reduced abrasiveness and a wear resistance

comparable to the natural enamel (like some modern resin-based composites and lithium-disilicate glass-ceramics) should be always preferred by clinicians,<sup>37–40</sup> in order to avoid excessive wear, to limit the occurrence of reiterate and undesirable restoration fractures/chippings and with the aim of ultimately preserving an appropriate occlusal balance.

In conclusion, when raising up the OVD, keeping the vertical dimension increase within the limits of a pure condylar rotation may allow the preservation of unaltered condyle-disc-fossa relationships, avoiding the introduction of possibly detrimental interferences to a preoperatively confirmed TMJ balance. Three-dimensional imaging (such as MR) is the only available technique to objectively confirm a steady disc and condyle position in the glenoid cavity throughout the whole treatment. Without an objective and imaging-based approach, the predictability of VDO increase procedures may be strongly influenced by the clinician experience.

### CONFLICT OF INTEREST

The authors declare no conflict of interest.

### AUTHOR CONTRIBUTIONS

All authors were involved in the writing, revision, and final review of the manuscript.

### ETHICAL APPROVAL

The patient has provided written informed consent for the publication of this case report.

### DATA AVAILABILITY STATEMENT

The data that support the findings of this study are available from the corresponding author upon reasonable request.

### ORCID

Francesco De Angelis  <https://orcid.org/0000-0001-7369-2667>

### REFERENCES

- D'Arcangelo C, Vadini M, D'Amario M, Chiavaroli Z, De Angelis F. Protocol for a new concept of no-prep ultrathin ceramic veneers. *J Esthet Restor Dent*. 2018;30(3):173-179.
- Johansson A, Johansson AK, Omar R, Carlsson GE. Rehabilitation of the worn dentition. *J Oral Rehabil*. 2008;35(7):548-566.
- Johansson A, Omar R. Identification and management of tooth wear. *Int J Prosthodont*. 1994;7(6):506-516.
- Keough B. Occlusion-based treatment planning for complex dental restorations: part 1. *Int J Periodontics Restorative Dent*. 2003;23(3):237-247.
- Abduo J. Safety of increasing vertical dimension of occlusion: a systematic review. *Quintessence Int*. 2012;43(5):369-380.
- Abduo J, Lyons K. Clinical considerations for increasing occlusal vertical dimension: a review. *Aust Dent J*. 2012;57(1):2-10.
- Manfredini D, Poggio CE. Prosthodontic planning in patients with temporomandibular disorders and/or bruxism: a systematic review. *J Prosthet Dent*. 2017;117(5):606-613.
- Spreafico RC. Composite resin rehabilitation of eroded dentition in a bulimic patient: a case report. *Eur J Esthet Dent*. 2010;5(1):28-48.
- Vailati F, Belser UC. Full-mouth adhesive rehabilitation of a severely eroded dentition: the three-step technique. part 1. *Eur J Esthet Dent*. 2008;3(1):30-44.
- Moreno-Hay I, Okeson JP. Does altering the occlusal vertical dimension produce temporomandibular disorders? a literature review. *J Oral Rehabil*. 2015;42(11):875-882.
- Goodacre CJ, Campagni WV, Aquilino SA. Tooth preparations for complete crowns: an art form based on scientific principles. *J Prosthet Dent*. 2001;85(4):363-376.
- Poyser NJ, Briggs PF, Chana HS, Kelleher MG, Porter RW, Patel MM. The evaluation of direct composite restorations for the worn mandibular anterior dentition-clinical performance and patient satisfaction. *J Oral Rehabil*. 2007;34(5):361-376.
- Tryde G, McMillan DR, Stoltze K, Morimoto T, Spanner O, Brill N. Factors influencing the determination of the occlusal vertical dimension by means of a screw jack. *J Oral Rehabil*. 1974;1(3):233-244.
- Helsing G, Ekstrand K. Ability of edentulous human beings to adapt to changes in vertical dimension. *J Oral Rehabil*. 1987;14(4):379-383.
- Ormianer Z, Palty A. Altered vertical dimension of occlusion: a comparative retrospective pilot study of tooth- and implant-supported restorations. *Int J Oral Maxillofac Implants*. 2009;24(3):497-501.
- Carlsson GE, Ingervall B, Kocak G. Effect of increasing vertical dimension on the masticatory system in subjects with natural teeth. *J Prosthet Dent*. 1979;41(3):284-289.
- Pullinger AG, Seligman DA. Quantification and validation of predictive values of occlusal variables in temporomandibular disorders using a multifactorial analysis. *J Prosthet Dent*. 2000;83(1):66-75.
- Hensel E, Gesch D, Biffar R, et al. Study of health in pomerania (ship): a health survey in an east german region. objectives and design of the oral health section. *Quintessence Int*. 2003;34(5):370-378.
- Turp JC, Schindler H. The dental occlusion as a suspected cause for TMDs: epidemiological and etiological considerations. *J Oral Rehabil*. 2012;39(7):502-512.
- Le Bell Y, Jamsa T, Korri S, Niemi PM, Alanen P. Effect of artificial occlusal interferences depends on previous experience of temporomandibular disorders. *Acta Odontol Scand*. 2002;60(4):219-222.
- Niemi PM, Le Bell Y, Kylmala M, Jamsa T, Alanen P. Psychological factors and responses to artificial interferences in subjects with and without a history of temporomandibular disorders. *Acta Odontol Scand*. 2006;64(5):300-305.
- Sessle BJ. Biological adaptation and normative values. *Int J Prosthodont*. 2003;16 Suppl(7):72-73. discussion 89-90.
- Dibbets J, Tunke C. Kiefergelenksprobleme und die stolpersteintheorie. *Inf Orthod Kieferorthop*. 2006;38(3):185-188.
- Vanini L, D'Arcangelo C. *Estetica Funzione Postura*. Acme; 2018:600.

25. D'Arcangelo C, Vanini L, Vadini M, D'Amario M, De Angelis F. E.F.P. Clinical approach (Esthetic-function-posture). *Dent Cadmos*. 2018;86(6):484-498.
26. Rinchuse DJ, Kandasamy S. Centric relation: a historical and contemporary orthodontic perspective. *J Am Dent Assoc*. 2006;137(4):494-501.
27. Stoll ML, Guleria S, Mannion ML, et al. Defining the normal appearance of the temporomandibular joints by magnetic resonance imaging with contrast: a comparative study of children with and without juvenile idiopathic arthritis. *Pediatr Rheumatol Online J*. 2018;16(1):8.
28. Tamimi D, Jalali E, Hatcher D. Temporomandibular Joint Imaging. *Radiol Clin North Am*. 2018;56(1):157-175.
29. The Glossary of Prosthodontic Terms. Ninth Edition. *J Prosthet Dent*. 2017;117(5S):e1-e105.
30. D'Arcangelo C, De Angelis F, Vadini M, D'Amario M. Clinical evaluation on porcelain laminate veneers bonded with light-cured composite: results up to 7 years. *Clin Oral Investig*. 2012;16(4):1071-1079.
31. Rayne J. Functional anatomy of the temporomandibular joint. *Br J Oral Maxillofac Surg*. 1987;25(2):92-99.
32. Hylander WL. Functional anatomy. In: Sarnat BG, Laskin DM, eds. *The Temporomandibular Joint A Biological Basis for Clinical Practice*, 4th ed. WB Sanders Company; 1992:60-92.
33. Lotters FJ, Zwijnenburg AJ, Megens CC, Naeije M. Relationship between condylar and incisor point displacement during habitual maximum open-close movements. *J Oral Rehabil*. 1996;23(8):548-554.
34. Lucia VO. A technique for recording centric relation. *J Prosthet Dent*. 1964;14(3):492-505.
35. Boucher CO. Occlusion in prosthodontics. *J Prosthet Dent*. 1953;3(5):633-656.
36. The Glossary of Prosthodontic Terms. *The Journal of Prosthetic Dentistry*. 2005;94(1):10-92. <http://dx.doi.org/10.1016/j.prosdent.2005.03.013>
37. D'Arcangelo C, Vanini L, Rondoni GD, De Angelis F. Wear properties of dental ceramics and porcelains compared with human enamel. *J Prosthet Dent*. 2016;115(3):350-355.
38. D'Arcangelo C, Vanini L, Rondoni GD, et al. Wear properties of a novel resin composite compared to human enamel and other restorative materials. *Oper Dent*. 2014;39(6):612-618.
39. D'Arcangelo C, Vanini L, Rondoni GD, Vadini M, De Angelis F. Wear evaluation of prosthetic materials opposing themselves. *Oper Dent*. 2018;43(1):38-50.
40. De Angelis F, D'Arcangelo C, Maliskova N, Vanini L, Vadini M. Wear properties of different additive restorative materials used for onlay/overlay posterior restorations. *Oper Dent*. 2020;45(3):E156-E166.

**How to cite this article:** D'Arcangelo C, Vadini M, Buonvivere M, De Angelis F. Safe clinical technique for increasing the occlusal vertical dimension in case of erosive wear and missing teeth. *Clin Case Rep*. 2021;9:e04747. <https://doi.org/10.1002/ccr3.4747>