



# Acute transient macular detachment after uneventful cataract surgery in a highly myopic eye

Tommaso Verdina<sup>a,b,\*</sup>, Tomaso Caporossi<sup>b,c</sup>, Gian Maria Cavallini<sup>a</sup>, Rodolfo Mastropasqua<sup>a</sup>

<sup>a</sup> Institute of Ophthalmology, University of Modena and Reggio Emilia, Modena, Italy

<sup>b</sup> Centro Oculistico Diagnostico Chirurgico, Firenze, Italy

<sup>c</sup> Department of Ophthalmology, Catholic University of Sacred-Heart Foundation "Policlinico Universitario A. Gemelli" IRCCS, Rome, Italy

## ARTICLE INFO

### Keywords:

Cataract  
High myopia  
Vitreomacular traction  
Macular detachment

## ABSTRACT

**Purpose:** We report a case of a highly myopic patient who presented a serous macular detachment at 24 hours after uncomplicated cataract surgery.

**Observations:** Surprisingly, after six days from surgery, a reabsorption of the detachment was noticed and the macular area returned to be anatomically normal without any surgical intervention. This early postoperative complication could be caused by changes in the vitreoretinal interface and ocular fluid dynamics or to a rupture of blood-retinal barriers due to postoperative inflammation.

**Conclusions and importance:** Our case reports on the occurrence of an early transient macular detachment after uneventful cataract surgery in a highly myopic eye. This finding suggests the importance of an OCT-based control in the immediate postoperative hours.

## Introduction

High myopia is defined as axial length greater than or equal to 26 mm and it is an established risk factor for pseudophakic retinal detachment as previously described.<sup>1,2</sup> These data refer to a long-term follow-up and a rhegmatogenous retinal detachment. Retinal foveal elevation following cataract surgery caused by vitreomacular traction has been already reported.<sup>3,4</sup> However, those cases were not highly myopic eyes.

We describe an unusual case of an extreme highly myopic patient who presented a macular detachment after 24 hours from uncomplicated cataract surgery.

## Case description

A 55 years-old man was referred to our service for a general ophthalmological visit. No significant general diseases nor family history for ocular diseases were registered. Best corrected visual acuity (BCVA) was 20/25 with refraction of  $-15.00$  sphere diopters (D) in the right eye (RE) and 20/40 with  $-22.00$ D in the left eye (LE). The anterior segment biomicroscopy revealed a nuclear sclerosis of the lens without any other remarkable alterations. A myopic chorioretinopathy was

evidenced bilaterally without any vitreoretinal tractions, posterior vitreous detachment (PVD) nor retinal tears at fundus examination. A macular optical coherence tomography (OCT, Cirrus 4000 HD-OCT, Carl Zeiss Meditec, Dublin, CA) was performed which evidenced a normal foveal profile (Fig. 1). A IOL master (Carl Zeiss Meditec AG, Germany) was performed showing an axial length of 30.44mm in RE and 34.65mm in LE. Cataract surgery was performed uneventfully in both eyes at one week distance (firstly LE) to each other with a coaxial technique with main incision 2.2 mm and topical anesthesia with Oxybuprocaine Hydrochloride 0.4% (Novesina 0, 4%, Novartis Farma, Origgio, Italy). Posterior capsule was intact at the end of surgery in both eyes. During surgery the patient did not present blood pressure elevations. A MA60 intraocular lens (Alcon, Fort Worth, TX, USA) was implanted bilaterally with a  $+1.00$  D in LE and  $+8.00$  D in RE. Intracameral cefuroxime (Aprokam®, Thea Laboratories, France) at the dose of 1mg/0.1 ml was injected in the anterior chamber at the end of each surgery, as per ESCRS cataract guidelines.<sup>5</sup> Post-operative therapy consisted of netilmicin/dexamethasone eyedrops 4 times a day for 15 days.

At 1-day follow-up from RE intervention, the patient referred blurry vision in the RE and the BCVA was 20/40 with  $-2.00$ D. Anterior chamber was quiet and IOL well positioned with intraocular pressure of 12 mmHg. Fundoscopy revealed macular thickening without any

\* Corresponding author. Institute of Ophthalmology, University of Modena and Reggio Emilia, Via del Pozzo 71, 41100, Modena, Italy.

E-mail address: [tommaso.verdina@gmail.com](mailto:tommaso.verdina@gmail.com) (T. Verdina).

<https://doi.org/10.1016/j.ajoc.2021.101117>

Received 1 February 2021; Received in revised form 20 April 2021; Accepted 29 April 2021

Available online 6 May 2021

2451-9936/© 2021 The Authors.

Published by Elsevier Inc.

This is an open access article under the CC BY-NC-ND license

(<http://creativecommons.org/licenses/by-nc-nd/4.0/>).

evidence of PVD; no peripheral choroidal detachment was evidenced. An OCT-scan revealed the presence of a serous macular detachment (Fig. 0.2) with a hyper-reflectivity of the inner retinal layers.

Observation was carried out in the immediate post-operative follow up. We prescribed topical (Bromfenac 0.09% eye drops twice/day) and systemic (Indomethacin 50mg oral capsules to be assumed twice/day) non-steroidal anti-inflammatory drugs along with oral acetazolamide and rest in bed other than the antibiotic/steroid drops already prescribed after surgery.

Surprisingly, after six days, the OCT revealed an almost complete reabsorption of the serous macular detachment (with a very little fluid still present only in the inferior part of the macula) and the macular area returned to be anatomically normal (Fig. 3) without any evidence of a PVD at funduscopy. BCVA was 20/20 with  $-2.00D$  refraction. No metamorphopsia or decreased visual acuity was encountered at 1 month from surgery.

## Discussion

We describe the presence of an early macular detachment after 24 hours from uncomplicated cataract surgery in an extreme highly myopic eye.

Macular elevation following cataract surgery caused by vitreomacular traction has been already reported.<sup>3</sup> Cataract-related acute vitreomacular traction was also reported in a small case series of five patients by Panagiotidis et al. at postoperative one day following routine uncomplicated cataract surgery, which resolved within 10 days without surgical intervention.<sup>4</sup> However, those cases were not high myopic patients. Moreover, after edema resolution, in 2 cases the authors found significant retinal pigment epithelium changes in the macular area resulting in permanent metamorphopsia and in 2 cases retinal thickness was decreased compared to normal in the macular area.<sup>4</sup>

In our case spontaneous resolution occurred within one week without any visual or anatomical consequences and without the evidence of PVD. After an accurate fundus examination, the patient did not present any retinal hole, tear or vitreoretinal abnormalities in the macular area. An accurate OCT analysis did not show any para vascular inner retinal abnormalities or tears at the edges of the myopic staphyloma as supposed in case of altered vitreoretinal interface. The OCT, at 24 hours from surgery, presented a “mustache” pattern (Fig. 2) or previously defined “A-shaped pattern”.<sup>6</sup>

We assume that this early postoperative complication could be caused by changes in the vitreoretinal interface. Cataract surgery induces structural and molecular changes in the vitreous body due to the sudden volume change induced and consequent loss of stabilization from the crystalline lens.<sup>2</sup> In highly myopic eyes the sudden volume change induced by the surgery could cause a transient hypotony and this could be the cause of the exudation associated with an antero-posterior hyaloid face contraction of vitreous cortex. The return into normal ocular fluid dynamics could be the cause of the spontaneous resolution

within few days.

Another possible cause of macular detachment could be an exudation due to rupture of blood-retinal barriers due to postoperative inflammation. However, this is unlikely to be the cause of the detachment as Irvine-Gass syndrome should be coming out at least two to three weeks after the surgery or even later as it is more common in complicated cases.<sup>7</sup>

Consequently to our finding, we assume that in highly myopic eyes it should be important to perform OCT in the immediate postoperative period (within 24 hours) in order to find any precocious alterations and monitor them. The temporary visual loss associated with acute macular detachment could go unnoticed as visual acuity can rapidly improve after one week.

It should be also important to avoid excessive depth changes of the anterior chamber during phacoemulsification that could cause tractions not only to the periphery but also to the macular region causing anatomical alterations in the immediate postoperative or even intraoperatively.

Finally, it is surprising that this finding occurred in only one eye and especially in the RE which was the less myopic one.

This report has some limitations to be considered. Firstly, we do not have any fundus color retinography, OCT-angiography or fluorescein angiography. These imaging modalities could have been contributive to determine or refute if there was a transient blood-ocular barrier breakdown. Then, the concomitant use of topical and systemic NSAIDs prescribed at 1-day follow-up could have influenced the reabsorption of the serous detachment.

In conclusion, this case confirms the role of vitreo-foveal adhesion in the early postoperative period after cataract surgery and the importance of an OCT-based control within 24 hours in highly myopic eyes. Controlled clinical trials will be needed in the future to better investigate the causes and the incidence of early macular detachment after cataract surgery in a large cohort of patients with high myopia and relate them to anterior chamber depth changes and phacoemulsification time.

## Patient consent

Written consent to publish this case report has been obtained from the patient. This report does not contain any personal identifying information.

## Funding

No funding or grant support.

## Authorship

All authors attest that they meet the current ICMJE criteria for Authorship.

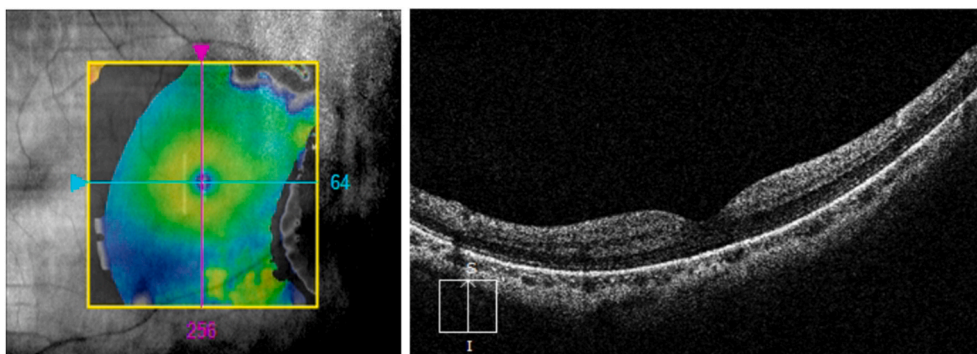


Fig. 1. Macular OCT pre intervention in the right eye.

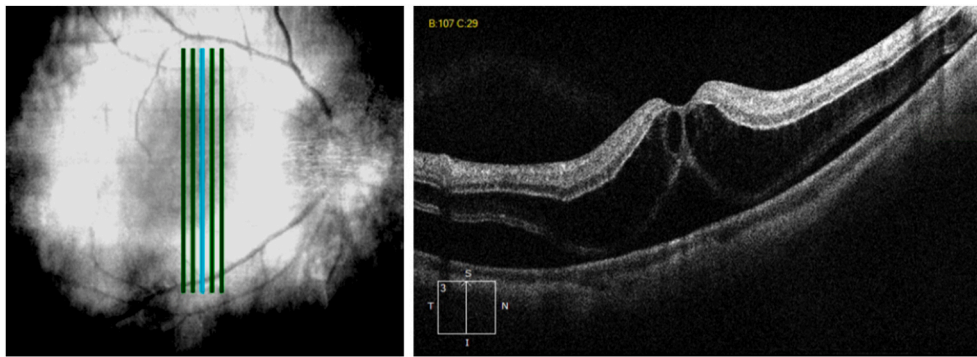

Fig. 2. Macular OCT at 24h after cataract surgery showing macular thickening with intraretinal and subretinal fluid.

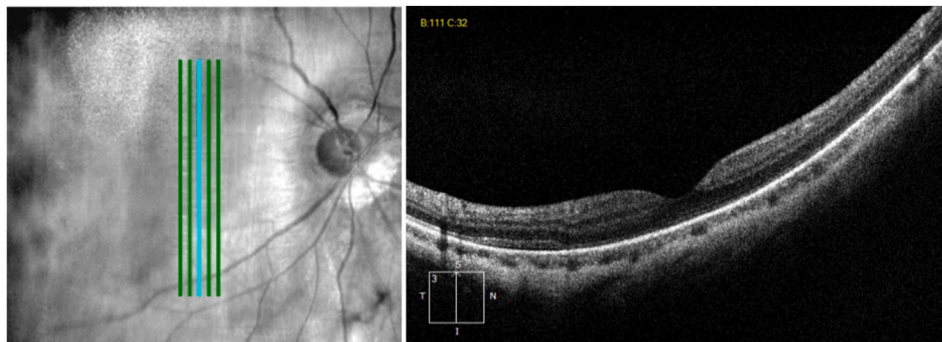


Fig. 3. Macular OCT at one week after surgery. The same vertical section showing an almost complete resolution of the serous macular detachment and the restoration of a normal foveal profile.

#### Data availability statement

All data are available on a reasonable request to the corresponding author.

#### Statement of ethics

The research was conducted ethically in accordance with the World Medical Association Declaration of Helsinki. The patient has given a written informed consent to publish the case (including publication of images).

#### Author contributions

Dr. Tommaso Verdina collected the data; all authors contributed drafting and revising the article, gave final approval of the version to be published, and agree to be accountable for all aspects of the work.

#### Declaration of competing interest

The authors have no financial disclosures:

#### Acknowledgements

None.

#### References

- McCarty CA, Livingston PM, Taylor HR. Prevalence of myopia in adults: implications for refractive surgeons. *J Refract Surg.* 1997;13(3):229–234.
- Haug SJ, Bhisitkul RB. Risk factors for retinal detachment following cataract surgery. *Curr Opin Ophthalmol.* 2012 Jan;23(1):7–11. <https://doi.org/10.1097/ICU.0b013e32834cd653>.
- Falcone PM. Vitreomacular traction syndrome confused with pseudophakic cystoid macular edema. *Ophthalmic Surg Laser.* 1996;27:392–394.
- Panagiotidis D, Karagiannis D, Theodossiadis P, et al. Cataract-related acute vitreomacular traction syndrome. *Eur J Ophthalmol.* Jan-Feb 2011;21(1):20–23. <https://doi.org/10.5301/ejo.2010.521>.
- Barry P, Cordovés L, Gardner S. ESCRS guidelines for prevention and treatment of endophthalmitis following cataract surgery: data, dilemmas and conclusions. Available at: [www.es CRS.org/endophthalmitis/guidelines](http://www.es CRS.org/endophthalmitis/guidelines); 2013.
- Costen MTJ, Williams CPR, Asteriades S, Luff AJ. An unusual maculopathy after routine cataract surgery. *Eye.* 2007;21:1416–1418, 10.
- Yonekawa Y, Kim IK. Pseudophakic cystoid macular edema. *Curr Opin Ophthalmol.* 2012;23(1):26–32.