

Journal: *Journal of Public Health and Emergency*

Manuscript ID: JPHE-2023-01

doi: 10.21037/jphe-2023-01

Title: Preface for the special series on “Management of COVID-19 in ICU: What’s New A Year Later?”

Corresponding authors: Luigi Vetrugno and Cristian Deana

Dear Drs. Vetrugno and Deana,

The proof of your manuscript is attached on the following pages. Please read through the document carefully to check for accuracy, reference citations, and figure and tables. Please also be aware a professional copyeditor may have edited your manuscript to comply with the JPHE style requirements.

In addition to proofing the article, the following queries have arisen during the preparation of your paper. Please address the queries listed below by making the appropriate changes in the text.

If you have any other revisions that you would like to make, this will be the last opportunity to do so before the article is published. In particular, please ensure that the author’s names and affiliations have been identified correctly, and the address of the corresponding author is correct.

If the changes cannot be easily described through email, please annotate this proof according to the annotation guidelines as detailed on the following page.

Query reference	Query	Author’s response
Q1	Please note that alterations cannot be made after you have approved for publication, irrespective of whether it is Online First.	
Q2	Please check the authors’ names [Author SURNAMES (family names) have been highlighted in red], the affiliations, and the correspondence details.	
Q3	Please check the Acknowledgements section and the Footnote.	
Q4	For standardization, the texts/data appeared on the figures may be re-formatted during typesetting. Please check if all the texts/data are correct.	
Q5	Please have a final double check for all the details including any data or numbers described in the text, abstract, figure and table (e.g., percentage).	
Q6	As the Helvetica Neue LT Pro font is used in typesetting, where the letter “c”, “o” and “i”, “l” may look similar in normal reading mode, please zoom in on the text for distinguishing.	

Once you have completed your revisions and/or addressed all the queries, or if you are satisfied with the proof in its existing form, please email: [caowy@amegroups.com](mailto:caowy@amegroups.com).

**To ensure the timely publication of your article,  
please respond within 48 hours.**

## Making corrections

Use Adobe Reader – available for free from <http://get.adobe.com/reader/> – to open the attached document.

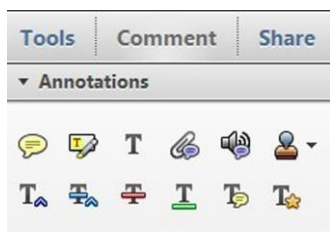

Figure 1 Adobe Acrobat X

Adobe Professional 7:

*Tools* → *Commenting* → *show Commenting Toolbar*


Adobe Reader 8:


*Tools* → *Comments & Markup* → *show Comments and Markup Toolbar*


Adobe Reader 10 and above:


*Comment* → *choose either Sticky Note or Highlight Text*

**In-text edits** Select the appropriate symbol and then click and drag over the text to be modified.

**Replace** : denotes where the text should be replaced with an alternative option

**Strikethrough** : crosses out the text

**Underline** : underlines the text

**Add note to text** : links selected text with a pop-up note

**Sticky notes** **To make a note:** choose the Sticky Note option and then click on a desired location



**Changing the name:** double-click and choose Options → Sticky Note Properties → General → insert desired name

**To move:** click anywhere (apart from the text field) and drag

**To resize:** click on the right or left hand order and drag

**To close:** click the box on the upper right corner; this does NOT delete your note

**To delete:** click and press the Delete keyboard button or right click and select delete from the drop-down menu

**Highlighting** **This allows you can highlight parts of the text.**



**To highlight:** select Highlight and then click and drag over the text to be highlighted. When finished, click on Highlight again to turn off the option.

**To change the colour:** double-click on the highlighted text and choose Options → Properties → Appearance → Color

Saving your changes:

Click on *File* → *Save* before closing the document.

For more detailed instructions on using Adobe Acrobat, please refer to

<http://www.adobe.com/support/acrobat/gettingstarted/>

## Preface for the special series on “Management of COVID-19 in ICU: What’s New A Year Later?”

In 2020, the coronavirus pandemic brought about dramatic changes to our daily lives. Millions of people were infected with severe acute respiratory syndrome coronavirus 2 (SARS-CoV-2), the pathogenic agent of coronavirus disease 2019 (COVID-19). Some patients required hospital admission, and the most severe cases required admission to the intensive care unit (ICU). Hospitals needed to reorganize their wards, and at the peak of pandemic many ICUs experienced bed shortages (1). In this preface, we would like to comment on the three articles published in *Journal of Public Health and Emergency* discussing the management of COVID-19 patients in the ICU.

In the first manuscript, Dr. Divella investigates the mechanisms underlying acute and chronic pain in COVID-19, and stresses how systemic inflammation and cytokine storm were critical players in its pathophysiology, especially in patients with moderate to severe symptoms (2). Dr. Divella also emphasizes that pain was reported across the entire disease spectrum, with headache, myalgia, and arthralgia being the most frequent symptoms in the acute phase of COVID-19. At the height of the pandemic, the number of people in the population suffering from chronic pain also increased due to the pandemic’s impact on healthcare systems, which had to postpone or cancel all elective surgical procedures, including pain management services and surgical procedures such as total joint arthroplasty. Other forms of non-COVID-19-related chronic pain also increased during the pandemic due to the impact of COVID-19 on the healthcare systems, which had to postpone or cancel all elective surgical procedures, including pain management services and surgical procedures such as total joint arthroplasty. Pain suffered in the ICU also had negative impacts on patient quality of life, as was recently demonstrated by our group (3). Moreover, the pandemic demonstrated that a significant number of patients contracting COVID-19 went on to exhibit long-term effects, known as post-COVID conditions (PCC) or long-COVID. The symptoms, which cannot be explained by other causes, (usually) start within three months of infection and generally last for months (4). At the present time, with the bulk of the pandemic behind us, evidence shows that being fully vaccinated reduces the risk of developing long-COVID (5).

The second manuscript addresses the use of prone positioning as a critical rescue maneuver in the fight against COVID-19. As described by Dr. Lassola, prone position proved to be essential for improving oxygenation and reducing mortality in COVID-19 acute respiratory distress syndrome (C-ARDS). It improves resting lung volume in the dorso-caudal regions by reducing the superimposed pressure of the heart and the abdomen (6). The prone position also improves ventilation/perfusion mismatch, with perfusion remaining preferentially distributed in the dorsal lung regions with more homogeneous aeration of the alveolar units. A PaO<sub>2</sub>/FiO<sub>2</sub> value below 150 mmHg, measured with a positive end-expiratory pressure (PEEP) level of at least 5 mmH<sub>2</sub>O, represents a reasonable criterion for prone positioning in C-ARDS, with the goal of minimizing ventilation damage in the early phase. In cases of severe hypoxemia, this maneuver is unanimously considered a life-saving therapy, especially when performed by expert and standardized teams. Indeed, the most recent trials revealed a positive relationship between longer durations of pronation and favorable outcomes (PROSEVA study) (7). Other promising results suggest that the prone position can even be used in patients suffering from acute hypoxemic respiratory failure due to COVID-19 and in those receiving non-invasive respiratory support, such as high-flow nasal cannula and helmet non-invasive ventilation (NIV), for at least eight hours a day (8).

Finally, the third article addresses the use of ultrasound in COVID-19. Maringelli *et al.* explored the role of lung, heart, vascular, and diaphragm ultrasound in COVID-19 patients with cardiovascular instability and assessed the associated complications (9). The benefits offered by ultrasound during the pandemic were enormous, with lung ultrasound quickly identifying COVID-19 interstitial pneumonia at home. It was also a valuable tool for monitoring patient complications in the ICU. Although lung ultrasound cannot replace the computed tomography (CT) scan, its use was fundamental during the height of the pandemic. For instance, Dr. Roberto Cosentini, head of the Emergency Department at the main hospital in Bergamo, Italy (the Province of Bergamo was one of the most stricken by the epidemic), mentioned that they were receiving up to 60–80 COVID-19 admissions per day, most of which were concentrated in afternoon (10). It was, therefore, impossible to obtain a CT scan for each patient. By consequence, ultrasound became the most used diagnostic tool for COVID-19. Cardiac ultrasound was used in COVID-19 patients to look at the direct involvement of cardiac function, myocardial depression and pericardial effusion, or in patients with prolonged ventilation to demonstrate ventilator-induced diaphragm dysfunction after prolonged mechanical ventilation and weaning failure (11-14). Furthermore, due to the thrombotic

48 tendency of COVID-19 patients, vascular ultrasound was used to exclude deep venous thrombosis.

49 We would like to conclude this editorial by honoring one of the authors of this last article, who sadly passed away last  
50 September. Prof. Nicola Brienza was an esteemed colleague and great friend. He will be deeply missed. Critical care medicine  
51 has lost one of its true leaders.

52

### 53 Acknowledgments

54 *Funding:* None.  
55

56

### 57 Footnote

58 *Provenance and Peer Review:* This article was commissioned by the editorial office, *Journal of Public Health and Emergency* for the  
59 series “Management of COVID-19 in ICU: What’s New A Year Later?”. The article did not undergo external peer review.  
60

61

62 *Conflicts of Interest:* Both authors have completed the ICMJE uniform disclosure form (available at <https://jphe.amegroups.com/article/view/10.21037/jphe-2023-01/coif>). The series “Management of COVID-19 in ICU: What’s New A Year Later?”  
63 was commissioned by the editorial office without any funding or sponsorship. LV served as an unpaid Guest Editor of the  
64 series and serves as an unpaid editorial board member for the *Journal of Public Health and Emergency*. CD served as an unpaid  
65 Guest Editor of the series. The authors have no other conflicts of interest to declare.  
66

67

68 *Ethical Statement:* The authors are accountable for all aspects of the work in ensuring that questions related to the accuracy or  
69 integrity of any part of the work are appropriately investigated and resolved.  
70

71

72 *Open Access Statement:* This is an Open Access article distributed in accordance with the Creative Commons Attribution-  
73 NonCommercial-NoDerivs 4.0 International License (CC BY-NC-ND 4.0), which permits the non-commercial replication and  
74 distribution of the article with the strict proviso that no changes or edits are made and the original work is properly cited (including  
75 links to both the formal publication through the relevant DOI and the license). See: <https://creativecommons.org/licenses/by-nc-nd/4.0/>.  
76

77

### 77 References

- 78 1. Deana C, Rovida S, Orso D, et al. Learning from the Italian experience during COVID-19 pandemic waves: be prepared and  
79 mind some crucial aspects. *Acta Biomed* 2021;92:e2021097.
- 80 2. Divella M. COVID-19 and pain: any relation? *J Public Health Emerg* 2022;6:17.
- 81 3. Deana C, Vetrugno L, Cortegiani A, et al. Quality of Life in COVID-Related ARDS Patients One Year after Intensive Care  
82 Discharge (Odissea Study): A Multicenter Observational Study. *J Clin Med* 2023;12:1058.
- 83 4. Deana C, Verriello L, Pauletto G, et al. Insights into neurological dysfunction of critically ill COVID-19 patients. *Trends*  
84 *Anaesth Crit Care* 2021;36:30-8.
- 85 5. Byambasuren O, Stehlik P, Clark J, et al. Effect of COVID-19 vaccination on long covid: systematic review. *BMJ Medicine*  
86 2023;2:e000385.
- 87 6. Lassola S. Pronation in acute respiratory distress syndrome (ARDS) secondary to COVID-19. *J Public Health Emerg* 2022;6:18.
- 88 7. Guérin C, Reignier J, Richard JC, et al. Prone positioning in severe acute respiratory distress syndrome. *N Engl J Med*  
89 2013;368:2159-68.
- 90 8. Ding L, Wang L, Ma W, et al. Efficacy and safety of early prone positioning combined with HFNC or NIV in moderate to  
91 severe ARDS: a multi-center prospective cohort study. *Crit Care* 2020;24:28.
- 92 9. Maringelli G, Arcamone E, Brienza N. Ultrasound in COVID-19: only lung? *J Public Health Emerg* 2022;6:16.
- 93 10. Vetrugno L, Baciarello M, Bignami E, et al. The "pandemic" increase in lung ultrasound use in response to Covid-19: can we  
94 complement computed tomography findings? A narrative review. *Ultrasound J* 2020;12:39.  
95

11. Vetrugno L, Orso D, Corradi F, et al. Diaphragm ultrasound evaluation during weaning from mechanical ventilation in COVID-19 patients: a pragmatic, cross-section, multicenter study. *Respir Res* 2022;23:210. 96  
97
12. Corradi F, Isirdi A, Malacarne P, et al. Low diaphragm muscle mass predicts adverse outcome in patients hospitalized for COVID-19 pneumonia: an exploratory pilot study. *Minerva Anestesiol* 2021;87:432-8. 98  
99
13. Cammarota G, Rossi E, Vitali L, et al. Effect of awake prone position on diaphragmatic thickening fraction in patients assisted by noninvasive ventilation for hypoxemic acute respiratory failure related to novel coronavirus disease. *Crit Care* 2021;25:305. 100  
101
14. Corradi F, Vetrugno L, Orso D, et al. Diaphragmatic thickening fraction as a potential predictor of response to continuous positive airway pressure ventilation in Covid-19 pneumonia: A single-center pilot study. *Respir Physiol Neurobiol* 2021;284:103585. 102  
103  
104



Luigi Vetrugno



Cristian Deana

**Luigi Vetrugno**<sup>1,2</sup> 105

<sup>1</sup>Department of Medical, Oral and Biotechnological Sciences, Gabriele d'Annunzio University of Chieti Pescara, Chieti, Italy; 106

<sup>2</sup>Department of Anesthesiology, Critical Care Medicine and Emergency, SS Annunziata Hospital, Chieti, Italy. 107

(Email: luigi.vetrugno@umich.it) 108

**Cristian Deana**<sup>3</sup> 109

<sup>3</sup>Department of Anesthesia and Intensive Care, Health Integrated Agency Friuli Centrale, Academic Hospital of Udine, Udine, Italy. 110

(Email: deana.cristian@gmail.com) 111

Received: 05 March 2023; Accepted: 09 March 2023. 112

doi: 10.21037/jphe-2023-01 113

View this article at: <https://dx.doi.org/10.21037/jphe-2023-01> 114

115

116

117

doi: 10.21037/jphe-2023-01

Cite this article as: Vetrugno L, Deana C. Preface for the special series on "Management of COVID-19 in ICU: What's New A Year Later?". *J Public Health Emerg* 2023.