J. Biol. Res. 2011 n.1 - Vol. LXXXIV - Rubbettino - Soveria Mannelli

A Probable Case of Scheuermann's Disease in a Juvenile Male From the Late Roman Necropolis of Torrenueva (III – IV Bc, Granada, Spain)

S. López-Lázaro[1], J. Viciano[1], A. Amores[1], J. Jiménez-Triguero[2]

[1] Department of Legal Medicine, Toxicology and Physical Anthropology, Medicine Faculty, University of Granada, Granada, 18012, Spain. E-mail: slopezlazaro@ugr.es
[2] GESPAD Al-Andalus S.L. Archaeology, Granada, 18010, Spain

KEY WORDS: juvenile kyphosis, osteochondrosis, vertebral wedging, Schmörl's nodes.

Introduction

Osteochondrosis is a term used to describe a group of disorders that affect the growing skeleton (Atanda *et al.*, 2011). Scheuermann's disease (SD) is a juvenile osteochondrosis of the vertebral column characterized by a kyphotic deformity of the spine that develops in early adolescence (Ali *et al.*, 2000; Lowe and Line, 2007). The etiology of SD is still unknown; however, several causes such as juvenile osteoporosis or hereditary and biomechanical factors have been suggested (Gavin, 2003). The criteria for diagnosis include: wedging of 5° or more in at least three adjacent vertebral bodies, Schmörl's nodes and the presence of an anterior extension of the epiphysial ring of the vertebral body (Digiovanni *et al.*, 1989; Scoles *et al.*, 1991). Although the SD is well-known clinically, it has rarely been reported in archaeological remains (Anderson and Carter, 1994).

Materials and Methods

The skeletal remains of a juvenile individual were exhumed in the late roman necropolis of Torrenueva (III–IV BC, Granada, Spain) in good condition and largely complete. The subject of this report was sexed as male, following standard descriptive criteria (Ferembach *et al.*, 1980) from cranial and pelvic features. The estimated age (13–16 years old) was based using morphological and metric methods (Scheuer and Black, 2000; Ubelaker *et al.*, 1989).
A macroscopic study of skeleton was performed, as well as a more detailed radiographic study, to detect any abnormality or pathology on the bones. The following vertebrae measurements were taken using a digital caliper in order to calculate the wedging of the vertebral bodies (Scoles *et al.*, 1991): anterior and posterior height of vertebral body, and maximum anteroposterior diameter of the vertebral body in the midsagittal plane. The amount of wedging at each vertebral body was calculated using the formula: $Wedging = 2 \tan^{-1} (Y/X)$; where $Y = (posterior\ height - anterior\ height)/2$ and $X = anteroposterior\ length$.

Results

The skeleton was examined and sings of osteochondrosis in the vertebral column and upper and lower limbs were observed, among other pathologic evidences. It was recognised a kyphosis located on thoracolumbar spine between T5–T9. The T3–T12 thoracic vertebrae and L1–L2 lumbar vertebrae bodies were wedged more than 5° and the vertebral bodies of T5–T8 had anterior extensions of the epiphyseal ring. With the exception of T3, T6 and L1, the rest of thoracic and lumbar vertebrae had Schmörl's nodes on the superior and/or inferior plates. The wedging affects the surface of the left medial-lateral vertebral bodies causing a kyphoscoliosis to the left (Fig.1). The different measurements of each thoracic and lumbar vertebra, the amount of wedging and the presence/absence of anterior extensions and Schmörl's nodes are presented in Tab.1.

Fig. 1 *(right). Lateral view of the thoracic kyphotic spine.*

	Posterior Height	Anterior Height	Maximum Anteroposterior Diameter	Vertebral Wedging	Anterior extensions	Schmörl Nodes
T3	18.11	16.14	15.60	7.23	Absence	Absence
T4	17.31	15.66	17.78	5.31	Absence	Presence
T5	15.49	12.36	20.87	8.58	Presence	Presence
T6	15.47	6.45	21.26	23.94	Presence	Absence
T7	16.16	10.44	24.82	13.16	Presence	Presence
T8	17.31	12.53	23.83	11.45	Presence	Presence
T9	18.19	13.75	23.70	10.72	Absence	Presence
T10	19.95	17.25	24.80	6.24	Absence	Presence
T11	20.28	18.15	24.03	5.08	Absence	Presence
T12	23.55	18.34	25.16	11.84	Absence	Presence
L1	24.89	20.80	24.92	9.34	Absence	Absence
L2	25.58	20.07	24.65	12.74	Absence	Presence

Tab.1. *Different measurements (in mm), vertebral body wedging (in degrees) and the presence/absence of anterior extensions and Schmörl's nodes.*

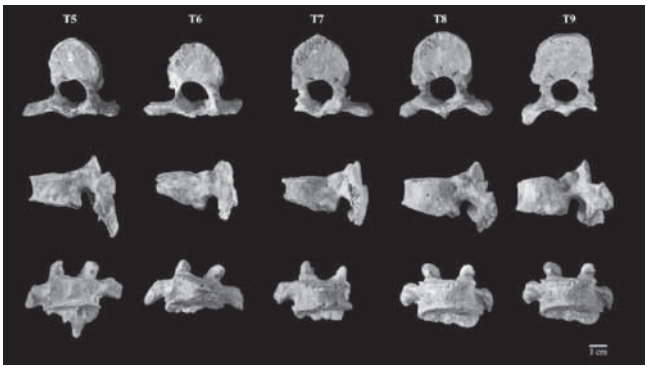

Fig. 2 *(left). Wedge-shaped vertebral bodies of T5–T9. Superior, lateral and anterior view.*

Discussion

Researches such as that of Scoles (1991) or Digiovanni (1989) show an abnormal growth of the spine in young individuals, which results in an extension of cancellous bone at the anterior margin of the vertebral bodies and that occurs in individuals with SD and is absent in healthy individuals. In our case, the T5–T8 vertebrae have this extension.

The combination of SD symptoms - wedging of the vertebral body, narrowing of the intervertebral disc space, irregularity of the vertebral body - predispose the individuals to develop Schmörl's nodes (Faccia and Williams, 2008). With the exception of the vertebrae T3, T6 and L1, the rest of vertebrae have Schmörl's nodes, showing a clear relationship between the two diseases, due to these nodes are typical of adulthood.

Regarding the differential diagnosis, we must not confuse the SD with other syndromes or diseases, such as postural kyphosis, congenital kyphosis, skeletal dysplasia, tumors and infections (tuberculosis, polio, etc.) or traumatic compression fractures.

The combination of several important pathognomonic signs and other evidences of osteochondrosis in the upper and lower limbs, confirmed the hypothesis that the individual may be a probable case of Scheuermann's disease.

References

Ali R.M., Green D.W., Patel T.C. 2000. Scheuermann's kyphosis. *Curr. Opin. Orthop.*, 11: 131-136.

Anderson T., Carter A.R. 1994. A possible example of Scheuermann's disease from Iron Age, Deal, Kent. *J. o. P.,* 6: 57-62.

Atanda A. Jr., Shah S.A., ÒBrien K. 2011. Osteochondrosis: common causes of pain in growing bones. *Am. Fam. Physician.*, 83: 285-291.

Digiovanni B.F., Scoles P.V., Latimer B.M. 1989. Anterior extension of the thoracic vertebral bodies in Scheuermann's kyphosis. An anatomic study. *Spine,* 14: 712-716.

Faccia K., Williams R. 2008. Schmorl's nodes: Clinical significance and implications for the Bioarchaeological Record. *Int. J. Osteoarchaeol.,* 18: 28-44.

Ferembach D., Schwidetzky L., Stloukal M. 1980. Recommendations for Age and Sex Diagnoses of Skeletons. *J. Hum. Evol.,* 9: 517-549.

Gavin T.M. 2003. The etiology and natural history of Scheuermann's kyphosis. *J. Prosthet. Orthot.,* 15: S11-S16.

Lowe T.G., Line B.G. 2007. Evidence based medicine: analysis of Scheuermann kyphosis. *Spine,* 32: 115-119.

Scheuer L., Black S. 2000. *Developmental Juvenile Osteology*. Ed. Academic Press. USA.

Scoles P.V., Latimer B.M., Digiovanni B.F., Vargo E, Bauza S, Jellema L.M. 1991. Vertebral alterations in Scheuermann's kyphosis. *Spine,* 16: 509-515.

Ubelaker D.H. 1989. *Human skeletal remains: excavation, analysis, interpretation, 2nd edition*. Smithsonian Manuals on Archaeology. Taraxacum. Press: Washington, DC.