

Available online at [www.sciencedirect.com](http://www.sciencedirect.com)

journal homepage: [www.elsevier.com/locate/radcr](http://www.elsevier.com/locate/radcr)

## Case Report

# Successful lung response after surgical repair in an infant with right-sided congenital diaphragmatic hernia ☆,☆☆,★

Giorgia Gasparroni, MD<sup>a,1</sup>, Marika Perrotta, MD<sup>a,1</sup>, Valentina Chiavaroli, PhD<sup>b,\*</sup>,  
Altea Petrucci, MD<sup>b</sup>, Simona Di Credico, MD<sup>b</sup>, Paola Cicioni, MD<sup>b</sup>, Angelika Mohn, Prof<sup>a</sup>,  
Gabriele Lisi, PhD<sup>c</sup>, Pierluigi Lelli Chiesa, Prof<sup>c</sup>, Susanna Di Valerio, MD<sup>b</sup>

<sup>a</sup> Department of Pediatrics, University of Chieti, Chieti, Italy

<sup>b</sup> Neonatal Intensive Care Unit, Pescara Public Hospital, Pescara, Italy

<sup>c</sup> Department of Pediatric Surgery, University of Chieti and Pescara Public Hospital, Chieti-Pescara, Italy

### ARTICLE INFO

#### Article history:

Received 17 May 2020

Revised 6 June 2020

Accepted 7 June 2020

Available online 3 July 2020

#### Keywords:

Bochdalek hernia

Newborn

Neonatal surgery

Respiratory outcome

### ABSTRACT

Congenital diaphragmatic hernia is a rare condition associated with pulmonary complications as the abdominal viscera herniated into the chest may affect lungs development. We present the case of a male newborn baby with a prenatal diagnosis of a posterolateral defect (Bochdalek hernia) involving the right side. The infant underwent surgical repair at 3 days of life, and the post-surgery chest X-ray did not reveal morpho-structural alterations of the lungs and diaphragmatic profile. Our clinical case shows that patients may have a better lung outcome despite an initial unfavorable picture. Prenatal diagnosis is essential in identifying infants with congenital diaphragmatic hernia, especially those cases at higher risk for the worse outcomes, to optimize their clinical and surgical management.

© 2020 The Authors. Published by Elsevier Inc. on behalf of University of Washington.

This is an open access article under the CC BY-NC-ND license.

(<http://creativecommons.org/licenses/by-nc-nd/4.0/>)

## Introduction

Congenital diaphragmatic hernia is a rare condition affecting approximately 1 per 2500–5000 births, which has been classified into posterolateral, anterior or central [1]. The posterolat-

eral defect (Bochdalek hernia) occurs in 70%–75% of cases, anterior defects (Morgagni hernia) in 23%–28% of cases, and central defects in the remaining 2%–7% of cases. More often the posterolateral defect occurs on the left side (85%), although it can involve the right side (13%) or be bilateral (2%). Equivalent survival has been reported for left-sided compared to right-

☆ Patient consent: Consent to publish the case report was not obtained. This report does not contain any personal information that could lead to the identification of the patient.

☆☆ Funding: This case report did not receive any specific grant from funding agencies in the public, commercial, or not-for-profit sectors.

\* Competing Interests: The authors have declared that no competing interests exist.

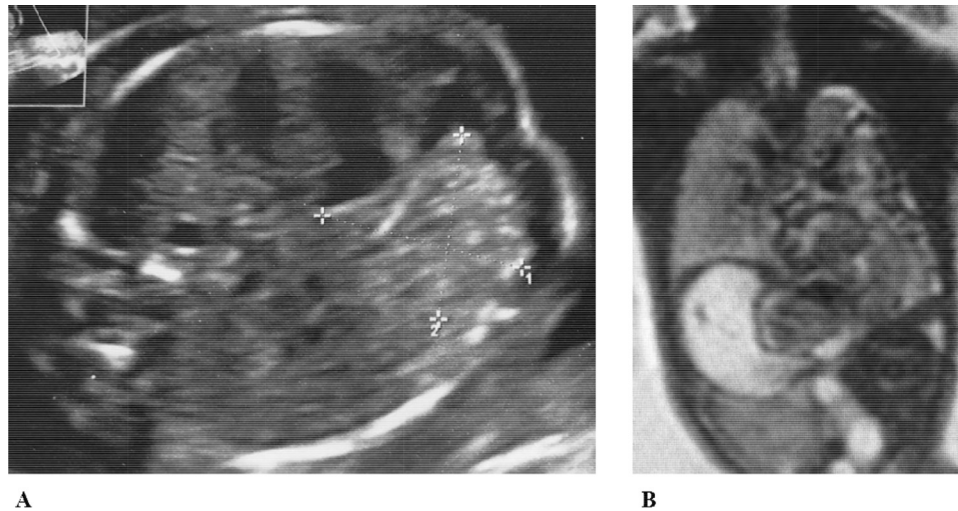
\* Corresponding author.

E-mail address: [valentinachiavaroli@hotmail.it](mailto:valentinachiavaroli@hotmail.it) (V. Chiavaroli).

<sup>1</sup> These authors contributed equally to this work.

<https://doi.org/10.1016/j.radcr.2020.06.020>

1930-0433/© 2020 The Authors. Published by Elsevier Inc. on behalf of University of Washington. This is an open access article under the CC BY-NC-ND license. (<http://creativecommons.org/licenses/by-nc-nd/4.0/>)



**Fig. 1 – Chest images from prenatal ultrasound (A) and magnetic resonance imaging (B)**

sided congenital diaphragmatic hernia [2], although the latter has been associated with high incidence of pulmonary complications [3].

Here, we report the case of a Bochdalek hernia involving the right side, which was diagnosed in utero.

### Case report

A male newborn baby was delivered by planned caesarean section at 36 weeks and 6 days' gestational age due to prenatal diagnosis of right posterolateral congenital diaphragmatic hernia, which was identified by ultrasound during the second trimester of pregnancy (Fig. 1A). At 21 weeks of gestation, fetal magnetic resonance imaging showed intestinal loops, likely to be colic, in the right hemithorax, associated with compression and cranial displacement of the lung, intrathoracic position of the ipsilateral kidney, and anterior and left dislocation of the heart (Fig. 1B). At 28 weeks of gestation, the observed-to-expected lung-head ratio was 78.2%.

At birth, the baby had spontaneous respiratory activity and vigorous crying, with an Apgar score of 7 and 8 at 1- and 5-minute, respectively. He was immediately intubated, and treated with synchronized intermittent positive pressure ventilation, with continuous monitoring of vital parameters. A central venous line and a nasogastric tube were placed, sedation as well as hemodynamic support with inotropic agents were provided, and total parenteral nutrition was initiated. Chest X-ray, performed soon after birth, revealed multiple bowel loops herniated in the right hemithorax and mediastinum and, partially, in the left hemithorax. Of note, an abnormally small right lung volume, suggestive of pulmonary hypoplasia, was observed together with multiple areas of atelectasis of the lungs, likely due to compression (Fig. 2A).

At 3 days of life, after achieving physiologic stabilization, the infant underwent laparotomic. surgical exploration that showed a large diaphragmatic defect of 5 cm × 2 cm, with absence of the right posterior diaphragmatic flap. The herniated

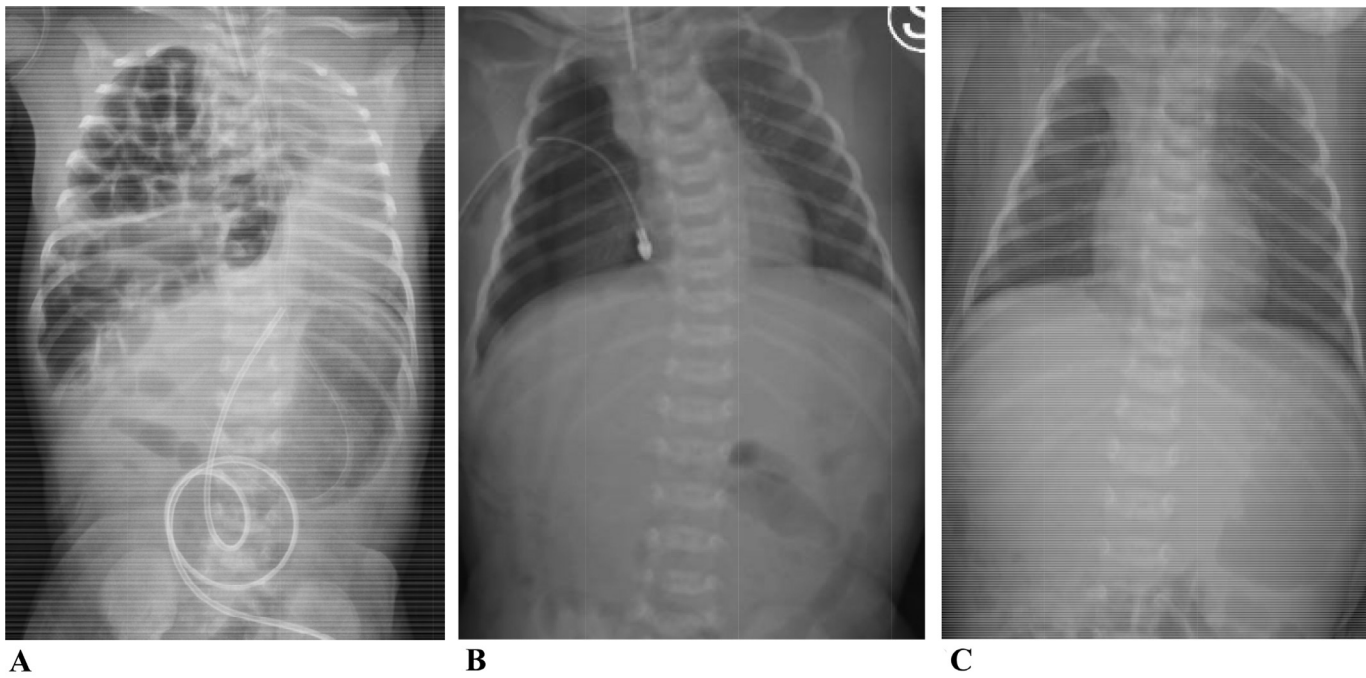
abdominal viscera (right colon, right portion of the transverse colon, ileum and distal jejunum, and right kidney) were repositioned into the abdominal cavity, and a patch repair of the right posterolateral diaphragmatic hernia was performed with expanded polytetrafluoroethylene. Notably, the post-surgery chest X-ray did not reveal any morpho-structural alterations of the lungs and the diaphragmatic profile. Namely, the right lung appeared well developed, thus excluding the previous suspect of pulmonary hypoplasia (Fig. 2B).

After surgery, the patient's conditions progressively improved and he was extubated in the tenth day of life with normal respiratory parameters afterwards. At 12 days of life, thoracic drainage was removed and enteral nutrition was introduced. A further chest X-ray was performed at 17 days of life, which confirmed normal findings (Fig. 2C). The infant was discharged at twenty days of life in good general condition, with a program of multidisciplinary follow-up.

### Discussion

Bochdalek hernia is associated with high morbidity and mortality due to the passage of abdominal organs into the thoracic cavity through a diaphragmatic defect. Intrathoracic herniation of kidneys, such as in our patient, is very rare, with a reported incidence of 0.25%. Of importance, the abdominal viscera herniated into the chest compete for areas that would normally accommodate the lungs, thus adversely affecting their growth and development [4]. Indeed, lungs may be severely compromised in newborns, with pulmonary hypoplasia and/or persistent pulmonary hypertension being among the most unfortunate outcomes [5].

Prenatal diagnosis is essential in identifying and managing infants with congenital diaphragmatic hernia, especially those cases at higher risk for the worse outcomes, to optimize their clinical and surgical management [6]. Several prenatal factors may be considered in the evaluation of the defect, such as coexistence of liver herniation, the observed-to-expected



**Fig 2 – Chest X-ray (A) before surgery showing herniated bowel loops in the right hemithorax and mediastinum and, partially, in the left hemithorax, with multiple areas of atelectasis of the lungs and a small right lung volume; (B) after surgery showing the absence of the previously herniated viscera and a right lung normally developed; and (C) at 17 days of life confirming normal findings**

lung-head ratio by ultrasound for the estimation of likelihood of pulmonary hypoplasia, and assessment of fetal lung volumes by magnetic resonance imaging [6]. An observed-to-expected lung-head ratio <45% has been reported to predict poor outcome in right-sided congenital diaphragmatic hernia, while an observed-to-expected lung-head ratio  $\leq$ 25% predicts poor outcome in left sided congenital diaphragmatic hernia (25% survival) [6]. In our case, despite an observed-to-expected lung-head ratio of approximately 78%, the chest X-ray performed after birth was suggestive of pulmonary hypoplasia and a large diaphragmatic defect that needed patch repair was detected during surgical exploration. However, a normal lung development was observed soon after surgical repair of the defect.

In these patients, surgery should be deferred until clinical conditions are declared stable, thus allowing to relocate viscera into their physiological position. Depending on the size, diaphragmatic defects can be repaired primarily or, if large, a permanent patch closure is required [6].

Multidisciplinary approach and post-discharge follow-up of infants with diagnosis of congenital diaphragmatic hernia are of fundamental importance [7]. Indeed, survivors may suffer of long-term sequelae, including respiratory issues (eg, chronic lung disease). Nevertheless, most infants improve over time [6,7], as lung development continues after birth into early childhood [8]. Of note, crucial processes take place up to young adulthood, such as classical and continued alveolarization and microvascular maturation (including the extracellular matrix) [8].

In summary, our clinical case shows that some patients may have a much better lung outcome despite their initial unfavorable picture. Of importance, a close multidisciplinary follow-up is mandatory for congenital diaphragmatic hernia survivors.

## REFERENCES

- [1] Kotecha S, Barbato A, Bush A, Claus F, Davenport M, Delacourt C, et al. Congenital diaphragmatic hernia. *Eur Respir J* 2012;39(4):820–9 Epub 2011/10/29PubMed PMID: 22034651. doi:10.1183/09031936.00066511.
- [2] Sperling JD, Sparks TN, Berger VK, Farrell JA, Gosnell K, Keller RL, et al. Prenatal diagnosis of congenital diaphragmatic hernia: does laterality predict perinatal outcomes? *Am J Perinatol* 2018;35(10):919–24 Epub 2018/01/06PubMed PMID: 29304545; PubMed Central PMCID: PMC6033692. doi:10.1055/s-0037-1617754.
- [3] Partridge EA, Peranteau WH, Herkert L, Rendon N, Smith H, Rintoul NE, et al. Right- versus left-sided congenital diaphragmatic hernia: a comparative outcomes analysis. *J Pediatric Surg* 2016;51(6):900–2 Epub 2016/06/28PubMed PMID: 27342009. doi:10.1016/j.jpedsurg.2016.02.049.
- [4] Tovar JA. Congenital diaphragmatic hernia. *Orphanet J Rare Dis* 2012;7:1 Epub 2012/01/05PubMed PMID: 22214468; PubMed Central PMCID: PMC3261088. doi:10.1186/1750-1172-7-1.
- [5] Ameis D, Khoshgoo N, Keijzer R. Abnormal lung development in congenital diaphragmatic hernia. *Semin Pediatric Surg* 2017;26(3):123–8 Epub 2017/06/24PubMed PMID: 28641748. doi:10.1053/j.sempedsurg.2017.04.011.
- [6] Puligandla PS, Skarsgard ED, Offringa M, Adatia I, Baird R, Bailey M, et al. Diagnosis and management of congenital diaphragmatic hernia: a clinical practice guideline. *CMAJ: Can Med Assoc J* 2018;190(4):E103–Ee12 Epub 2018/01/31PubMed PMID: 29378870; PubMed Central PMCID: PMC6033692. doi:10.1503/cmaj.170206.
- [7] Lally KP, Engle W. Postdischarge follow-up of infants with congenital diaphragmatic hernia. *Pediatrics* 2008;121(3):627–32 Epub 2008/03/04PubMed PMID: 18310215. doi:10.1542/peds.2007-3282.
- [8] Schittny JC. Development of the lung. *Cell Tissue Res* 2017;367(3):427–44 Epub 2017/01/31PubMed PMID: 28144783. doi:10.1007/s00441-016-2545-0.