Knee Surg Sports Traumatol Arthrosc (2012) 20:1953–1957
DOI 10.1007/s00167-011-1793-5

SHOULDER

Bipolar fresh osteochondral allograft for the treatment of glenohumeral post-traumatic arthritis

Sandro Giannini · Roberto Buda · Marco Cavallo · Alberto Ruffilli · Brunella Grigolo · Pier Maria Fornasari · Francesca Vannini

Received: 29 April 2011 / Accepted: 14 November 2011 / Published online: 24 November 2011

Abstract
Purpose Surgical management of end-stage glenohumeral osteoarthritis represents a challenge in young patients. Bipolar fresh osteochondral allograft (BFOA) represents a fascinating option to prosthetic substitution. Aim of this report is to describe an original technique for BFOA implantation in the shoulder and to describe the clinical and histological results at 30-month follow-up.
Methods A 47-year-old man received BFOA of the shoulder. Clinical and radiographical evaluations were carried out periodically up to 30 months.
Results The clinical score increased from 40 to 78 points (Constant Score), decreased from 64 points to 10 (DASH Disability/Symptom Score) and from 94 points to 0 (DASH Work module Score). Radiographically arthritis and partial reabsorption of the implanted surfaces were evident.
Conclusions The clinical result obtained in this patient seems to support the applicability of BFOA in the shoulder with severe post-traumatic arthritis and with intact rotator cuff. Although unrelated to the clinical result, the occurrence of arthritis of the implanted surfaces is cause of concern.
Level of evidence Case report, Level V.

S. Giannini · R. Buda · M. Cavallo · A. Ruffilli · F. Vannini (✉)
Clinical Orthopaedic and Traumatology Unit II, Rizzoli Orthopaedic Institute, Bologna, Italy
e-mail: france_vannini@yahoo.it

B. Grigolo
Immunorheumatology and Tissue Engineering Lab, Rizzoli Orthopaedic Institute, Bologna, Italy

P. M. Fornasari
Immunohematology, Transfusional Medicine Service and Musculoskeletal Tissue Bank, Rizzoli Orthopaedic Institute, Bologna, Italy

Keywords Shoulder arthritis · Bipolar fresh osteochondral allograft · Total replacement

Introduction

Osteoarthritis of the glenohumeral joint is one of the most common etiologies of shoulder pain [24]. Although surgical options have expanded over time, the management of end-stage glenohumeral osteoarthritis still represents a challenge in young patient population [2].

In patients with intact rotator cuff, the most used surgical options are represented by total shoulder arthroplasty and hemiarthroplasty with or without biologic glenoid resurfacing, even in patients younger than 55 years [19, 26].

Nevertheless, the experience of shoulder arthroplasty in young patients has been marked by a high percentage of unsatisfactory results, although recent reports show favorable outcomes in the short term to midterm [15, 21, 23].

Bipolar fresh osteochondral allograft (BFOA) has been firstly proposed for the ankle and knee joint and represents a fascinating option for the biological joint reconstruction [3–5, 9, 10, 13, 16].

The rationale of BFOA is to provide viable cartilage that can survive transplantation, supported by an intact subchondral bony structure which is progressively integrated and replaced by host bone over time [6, 11, 13].

To our knowledge, there is no experience in literature about a procedure of bipolar total allograft applied to the shoulder [1, 13, 17, 20].

Aim of this study is to describe an original technique of total bipolar fresh allograft of the shoulder joint and to report the clinical and histological results obtained in one case at 2-year follow-up.

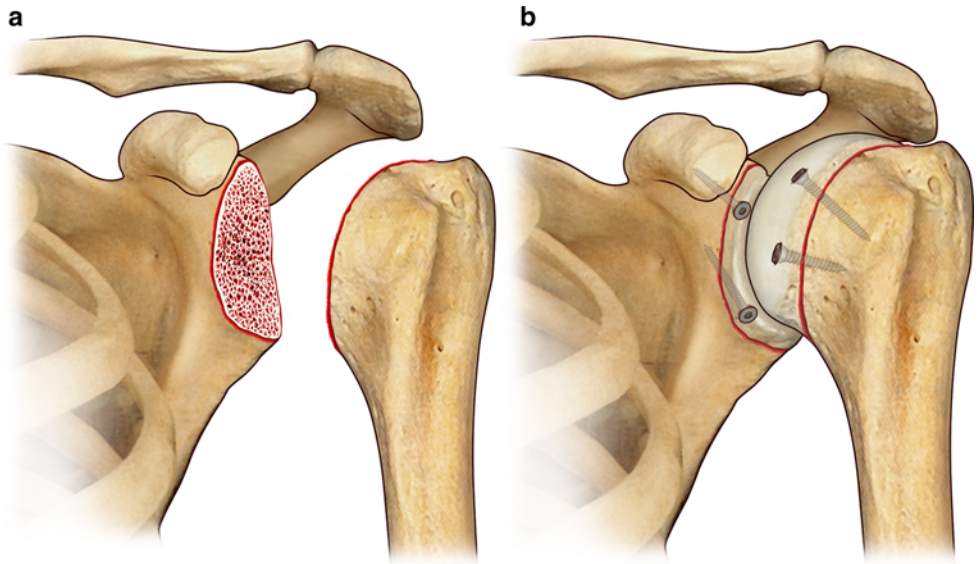

Fig. 1 Scheme showing the cut of the recipient surfaces and the allograft positioning

Case report

A 47-year-old man was referred for the evaluation of longstanding left shoulder pain and mechanical symptoms at authors' institution. He had undergone a repair for recurrent left shoulder instability with Latarjet procedure 8 years before, still symptoms persisted. An arthritis of the glenohumeral surfaces was evident at the radiographs, while the ROM was near to complete, although painful. A substitution of the bare articular surfaces with a fresh bipolar allograft was indicated as a surgical option (Fig. 1a, b). The procedure was approved by the ethical committee of the institution, and informed consent to the procedure was obtained by the patient.

The shoulder was examined in order to assess the pain and the functional impairment. Clinical evaluation before allograft reconstruction was performed and rated according to Constant Score, DASH Disability/Symptom Score and DASH Work module Score.

Radiographic evaluation was performed with standard radiographs (Fig. 2) and a CT scan of the affected shoulder in order to digitally measure the shoulder size. The superoinferior and anteroposterior diameters of the glenoid were taken into account along with the diameter of the humeral head considered as a sphere, and used to match the donor size with the recipient. The candidate was then inserted in a waiting list until the availability of an appropriate-sized donor. The donor was identified through the Bone Bank program for musculoskeletal tissue transplantation. With a standard surgical procedure, in a sterile regimen, the entire shoulder joint was harvested "en bloc" from the donor. Once harvested, a mini-incision was performed in the capsule in order to visually check the status of the cartilage and to permit the diffusion of the storing medium. The joint was then placed in a sterile container with L-glutamine, NaHCO3 and antibiotics solution and then stored at 4°C. An MRI was finally performed on the harvested shoulder in order to verify articular cartilage integrity, while the adequacy of shoulder size for the patient was verified through a CT scan.

Fig. 2 Preoperative radiographs of the left shoulder

Allograft implantation was performed 10 days after the harvest.

Fig. 3 Intraoperative view of the prepared graft

The surgical session consisted of two steps: the first for the graft preparation and the second for the graft implantation.

Step 1. On a separate surgical table, all soft tissues were carefully removed from the harvested shoulder, taking care not to damage the cartilage. Then, the articular surfaces of the glenoid and the humeral head were accurately cut with a standard pneumatic saw, maintaining intact the whole articular surface and about 10–12 mm of subchondral bone. The prepared articular surfaces (Fig. 3) were then temporarily placed in a container with saline solution.

Step 2. The patient was placed in beach-chair position under general anesthesia. A standard deltoideo-pectoral approach was performed. With a blunt dissection, the cephalic vein was identified and dislocated laterally. The subscapular muscle was then identified and detached from its insertion.

The capsule was opened and the humeral head was dislocated anteriorly. Under fluoroscopic control, two parallel Kirschner wires were placed in the humeral neck (perpendicular to the axis of the neck) and two Kirschner wires were placed in the base of the glenoid, parallel to the articular surface, in order to define the plane for the bony cut. The cut was then made using a standard pneumatic saw. The articular surfaces of the humeral head and the glenoid were removed and replaced with the previously prepared allograft components (Fig. 4).

The newly implanted glenoid was fixed with two small-fragment screws, whereas the humeral head was fixed with twist-off screws (Citieffe, Calderara di Reno, Bo, Italy). The joint was reduced and fluoroscopic control was performed in order to verify the correct placement of the graft; moreover, the range of motion of the shoulder was checked.

Finally, the subscapular muscle was reinserted, one drainage was placed, and a routine suture was performed. Postoperative radiographs were taken (Fig. 5).

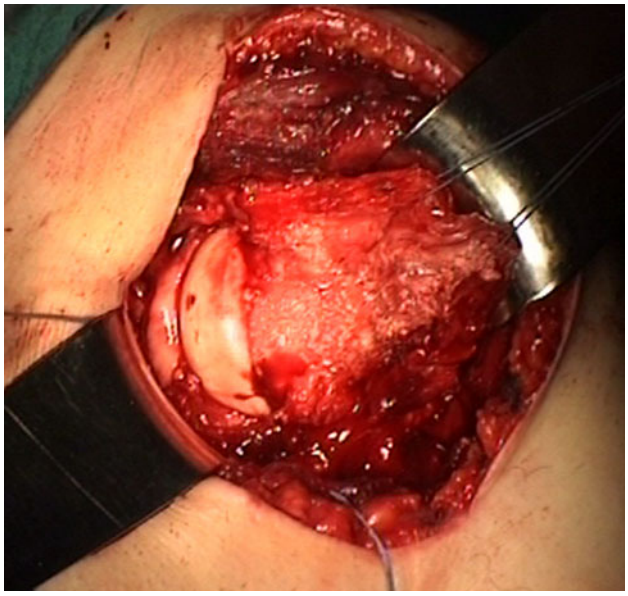

Fig. 4 Intraoperative view of the graft placed in the recipient site

Fig. 5 Postoperative radiographs of the left shoulder

A low postoperative immunosuppressive protocol was carried out. This included Cyclosporin 3 mg/Kg die for 6 months and Deltacortene 10 mg per day for the 1st month then 5 mg per day for 2 months.

Nine months after surgery, the patient underwent a second surgery for hardware removal and bioptic evaluation of the implanted allograft.

Biopsy of cartilage, bone and synovial tissue was taken, and immunological and immunohistochemical analyses of the specimens were carried out.

Results

No intraoperative or postoperative complications occurred.

At 30-month follow-up, the patient had full range of painless motion with no additional complains of rest pain or pain related to activities; the Constant Score increased from 40 to 78 points, the DASH Disability/Symptom Score decreased from a preoperative score of 64 points to 10 and the DASH Work module Score decreased from 94 points to 0.

The patient declared to be satisfied of the treatment and the result.

Integration of the graft with bone consolidation was evident at 5 months radiographs follow up. Nevertheless, arthritis and partial reabsorption of the implanted surfaces were evident at final follow-up (Fig. 6).

Immunohistochemical analysis of the bioptic specimens revealed vital cartilage with a high proteoglycan content, normal cellular distribution and type 2 collagen expression. Moreover, on the bony interface, the biopsy demonstrated the complete osteointegration between the graft and the patient. Finally, analysis of synovial biopsy revealed limited number of macrophages, without prominent perivascular inflammatory cell infiltrates or lymphoid aggregates.

Discussion

The most important finding of the present study was the applicability of BFOA in the shoulder with severe post-traumatic arthritis and with intact rotator cuff, representing a fascinating possible alternative to traditional prosthetic substitution.

Fig. 6 30-month follow-up radiographs of the left shoulder showing arthritis and moderate reabsorption of the allograft

The applicability of BFOA has been established in the ankle joint, while in the other joints, only the use of partial or monopolar allografts has been reported to date [1, 3, 7, 8, 10, 22]. Particularly in the shoulder, the concept of allograft implantation is well established in the treatment of shoulder instability [25] and in revision shoulder arthroplasty [6]; otherwise, no reports exist regarding a bipolar total fresh allografting.

The arthritic shoulder may represent an ideal indication for the substitution by BFOA since it is a non-weight-bearing joint, but it is subject to compressive and shear forces which may easily be cause of mobilization of prosthetic components [12].

The allograft, instead, has the capability to be fully integrated by the recipient and maintains a biomechanics of the shoulder as close as possible to normal.

Based on the idea of a role of the immunological system in the aggression to the transplanted cartilage, an immunosuppressive therapy was performed in order to prevent that damage, resulting in arthritis [14, 18]. The protocol we used was a light immunosuppressive therapy, already in use for rheumatologic disease and performed for 6 months. This protocol was easily tolerated by the patient and no adverse event was noticed; nevertheless, the protective effect against arthritis occurrence was of scarce efficacy. Further studies are required in order to understand how to prevent arthritic changes in transplanted cartilage.

BFOA is a technically demanding surgery, requiring a multidisciplinary approach and a bone bank facility. The relevance of this work is that the results obtained support the applicability of BFOA in the shoulder in a larger case series, as an interesting surgical alternative to traditional arthroplasty in severe post-traumatic shoulder arthritis in young active patients.

Conclusion

The clinical results obtained in the case described were extremely satisfactory in terms of pain resolution, range of motion, overall function of the transplanted shoulder, patient's satisfaction and quality of life. The histological results also confirmed a good survivorship of the chondrocytes at 19 months after implantation and a nice integration of the graft. Nevertheless, despite correct positioning and size, at 2-year follow-up, the radiographical results were disappointing, even if uncorrelated with the clinical result.

References

1. Armitage MS, Faber KJ, Drosdowech DS, Litchfield RB, Athwal GS (2010) Humeral head bone defects: remplissage, allograft, and arthroplasty. Orthop Clin North Am 41:417–425
2. Bailie DS, Llinas PJ, Ellenbecker TS (2008) Cementless humeral resurfacing arthroplasty in active patients less than fifty-five years of age. J Bone Joint Surg Am 90:110–117
3. Bugbee WD, Convery FR (1999) Osteochondral allograft transplantation. Clin Sports Med 18:67–75
4. Chu CR, Convery FR, Akeson WH, Meyers M, Amiel D (1999) Articular cartilage transplantation. Clinical results in the knee. Clin Orthop Relat Res 360:159–168
5. Convery FR, Meyers MH, Akeson WH (1991) Fresh osteochondral allografting of the femoral condyle. Clin Orthop Relat Res 273:139–145
6. Czitrom AA, Keating S, Gross AE (1990) The viability of articular cartilage in fresh osteochondral allografts after clinical transplantation. J Bone Joint Surg Am 72:574–581
7. Emmerson BC, Görtz S, Jamali AA, Chung C, Amiel D, Bugbee WD (2007) Fresh osteochondral allografting in the treatment of osteochondritis dissecans of the femoral condyle. Am J Sports Med 35:907–914
8. Evans KN, Providence BC (2010) Case report: fresh-stored osteochondral allograft for treatment of osteochondritis dissecans the femoral head. Clin Orthop Relat Res 468:613–618
9. Garrett JC (1986) Treatment of osteochondral defects of the distal femur with fresh osteochondral allografts: a preliminary report. Arthroscopy 2:222–226
10. Giannini S, Buda R, Grigolo B, Bevoni R, Di Caprio F, Ruffilli A, Cavallo M, Desando G, Vannini F (2010) Bipolar fresh osteochondral allograft of the ankle. Foot Ankle Int 31:38–46
11. Gross AE, Silverstein EA, Falk J, Falk R, Langer F (1975) The allotransplantation of partial joints in the treatment of osteoarthritis of the knee. Clin Orthop Relat Res 108:7–14
12. Hopkins AR, Hansen UN, Amis AA, Knight L, Taylor M, Levy O, Copeland SA (2007) Wear in the prosthetic shoulder: association with design parameters. J Biomech Eng Apr 129:223–230
13. Kim CW, Jamali A, Tontz W Jr, Convery FR, Brage ME, Bugbee W (2002) Treatment of post-traumatic ankle arthrosis with bipolar tibiotalar osteochondral shell allografts. Foot Ankle Int 23:1091–1102
14. Langer F, Gross AE (1974) Immunogenicity of allograft articular cartilage. J Bone Joint Surg Am 56:297–304
15. Levy JC, Virani NA, Frankle MA, Cuff D, Pupello DR, Hamelin JA (2008) Young patients with shoulder chondrolysis following arthroscopic surgery treated with total shoulder arthroplasty. J Should Elbow Surg 17:380–388
16. Mahomed MN, Beaver RJ, Gross AE (1992) The long-term success of fresh, small fragment osteochondral allografts used for intraarticular post-traumatic defects in the knee joint. Orthopedics 15:1191–1199
17. McCulloch PC, Kang RW, Sobhy MH, Hayden JK, Cole BJ (2007) Prospective evaluation of prolonged fresh osteochondral allograft transplantation of the femoral condyle: minimum 2-year follow-up. Am J Sports Med 35:411–420
18. Meehan R, McFarlin S, Bugbee W, Brage M (2005) Fresh ankle osteochondral allograft transplantation for tibiotalar joint arthritis. Foot Ankle Int 26:793–802
19. Orfaly RM, Rockwood CA Jr, Esenyel CZ, Wirth MA (2003) A prospective functional outcome study of shoulder arthroplasty for osteoarthritis with an intact rotator cuff. J Should Elbow Surg 12:214–221
20. Provencher MT, Leclere LE, Ghodadra N, Solomon DJ (2010) Postsurgical glenohumeral anchor arthropathy treated with a fresh distal tibia allograft to the glenoid and a fresh allograft to the humeral head. J Should Elbow Surg 19:e6–e11
21. Raiss P, Aldinger PR, Kasten P, Rickert M, Loew M (2008) Total shoulder replacement in young and middle aged patients with glenohumeral osteoarthritis. J Bone Joint Surg Br 90:764–769
22. Shasha N, Aubin PP, Cheah HK, Davis AM, Agnidis Z, Gross AE (2002) Long-term clinical experience with fresh osteochondral allografts for articular knee defects in high demand patients. Cell Tissue Bank 3:175–182
23. Sperling JW, Cofield RH, Rowland CM (2004) Minimum fifteen-year followup of Neer hemiarthroplasty and total shoulder arthroplasty in patients aged fifty years or younger. J Should Elbow Surg 13:604–613
24. Weinstein DM, Bucchieri JS, Pollock RG, Flatow EL, Bigliani LU (2000) Arthroscopic debridement of the shoulder for osteoarthritis. Arthroscopy 16:471–476
25. Weng PW, Shen HC, Lee HH, Wu SS, Lee CH (2009) Open reconstruction of large bony glenoid erosion with allogeneic bone graft for recurrent anterior shoulder dislocation. Am J Sports Med 37:1792–1797
26. Wiater JM, Fabing MH (2009) Shoulder arthroplasty: prosthetic options and indications. J Am Acad Orthop Surg 17(7):415–425