# Osteochondral Lesions of the Knee: A New One-Step Repair Technique with Bone-Marrow-Derived Cells

By Roberto Buda, MD, Francesca Vannini, MD, PhD, Marco Cavallo, MD, Brunella Grigolo, PhD, Annarita Cenacchi, MD, and Sandro Giannini, MD

Osteochondral lesions of the knee are defects of the cartilaginous surface and underlying subchondral bone, most frequently traumatic in origin[1]. These lesions are predominantly located on the medial femoral condyle, and associated ligamentous or meniscal pathology is reported in 40% of cases[2,3] (Fig. 1). Biomechanical studies have demonstrated increased stress concentration on the rim of the osteochondral defect, which may have important implications for cartilage longevity[4]. Due to poor hyaline cartilage repair capability, larger osteochondral lesions of the knee are associated both with immediate significant clinical impairment and with symptoms appearing approximately one decade earlier than the degenerative cartilage changes that are associated with idiopathic osteoarthritis[5].

Surgery is frequently needed to treat knee symptoms in patients with osteochondral lesions of the knee and to restore

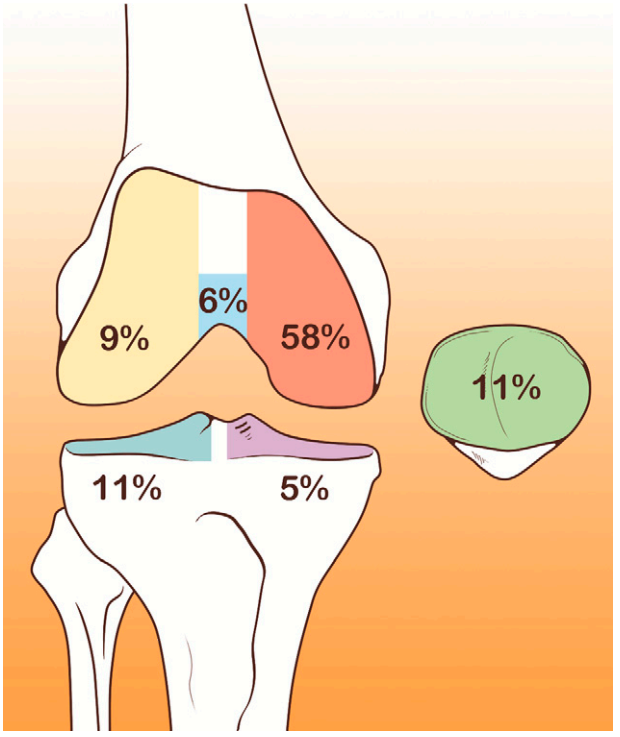


Fig. 1

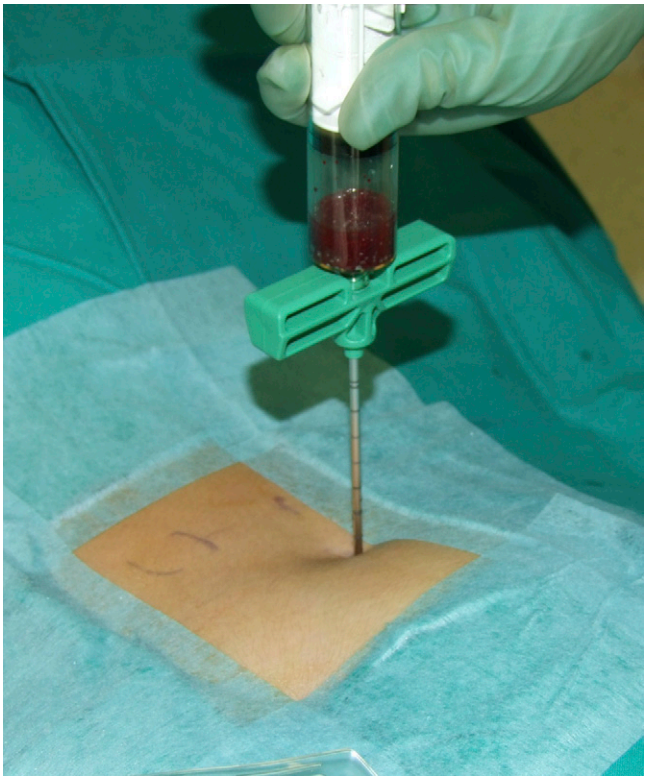

Fig. 2

**Fig. 1** Osteochondral lesions can affect all areas of articular cartilage, but the femoral condyle is most often involved. **Fig. 2** Bone marrow is aspirated from the posterior iliac crest.

**Disclosure:** The authors did not receive any outside funding or grants in support of their research for or preparation of this work. Neither they nor a member of their immediate families received payments or other benefits or a commitment or agreement to provide such benefits from a commercial entity.

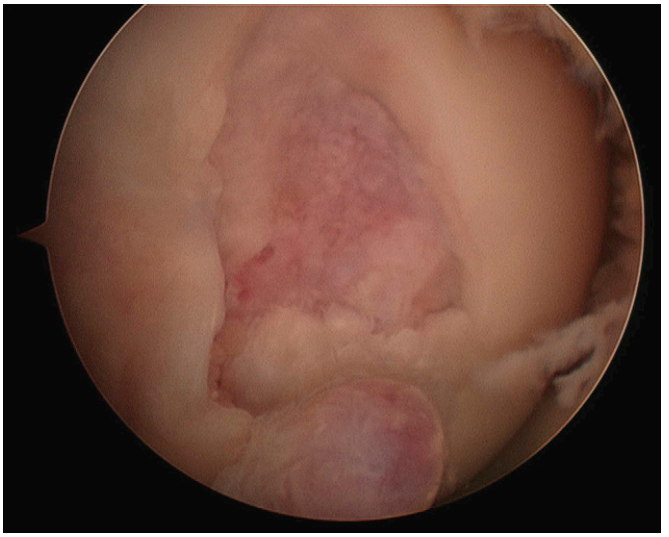

Fig. 3

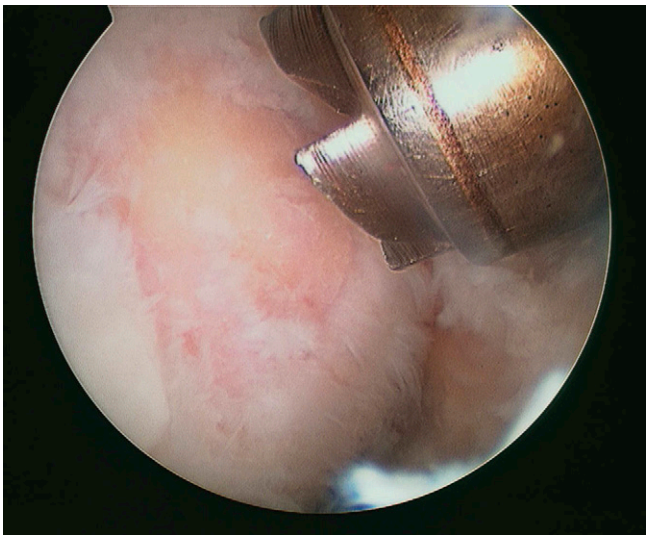

Fig. 4

**Fig. 3** Arthroscopic view showing the osteochondral lesion. **Fig. 4** Arthroscopic view showing a low-profile drill being used to debride the osteochondral lesion.

the cartilage on the articular surface, which lessens the risk of the development of osteoarthritis[6-8]. Various surgical options have been proposed for osteochondral repair[6-9] but only a few have shown the ability to provide repair of the lesion site with hyaline cartilage[5,10-12]. Traditionally, hyaline cartilage repair has been achieved through cartilage replacement (osteoarticular transfer system [OATS; Arthrex, Naples, Florida], which is a type of mosaicplasty)[13] or cartilage regeneration through autologous chondrocyte implantation[6,14]. Cartilage replacement procedures have the advantage of repairing cartilage defects with use of already mature autologous cartilage cells; however, donor-site pathology, discontinuity in the orientation of the cartilage plugs, and fibrocartilage in the gaps are disadvantages of these techniques[13]. Cartilage regeneration by autologous chondrocyte implantation provides continuous cartilage repair with no or minimal donor-site pathology. For the past sixteen years in which autologous chondrocyte implantation has been used, several studies have reported successful treatment of lesions ranging in size from 0.7 $cm^2$ to 22.0 $cm^2$, with stable and satisfactory results over time[6,7,15-18]. However, since autologous chondrocyte implantation treatment requires two operative procedures and is therefore associated with higher costs, new methods of cartilage regeneration have been sought.

Recently, bone-marrow-derived mesenchymal stem cells have been identified as a new option for the treatment of osteochondral defects, and a new one-step technique for bone-marrow-derived mesenchymal stem-cell transplantation has been proposed[19]. After encouraging results were obtained in the ankle[19], bone-marrow-derived mesenchymal stem-cell transplantation is now being utilized for osteochondral lesions of the knee.

The aim of this study was to investigate the validity of the "one-step" technique in repair of osteochondral lesions of the knee and to present the results of a series of twenty patients who were consecutively treated.

## Materials and Methods

Between April 2006 and May 2007, twenty patients (twelve males, eight females) who had osteochondral lesions of the knee underwent the one-step procedure. In eighteen patients, the lesions were posttraumatic in origin, whereas, in two patients, the lesions were due to osteochondritis dissecans. The treatment was indicated in patients who had grade-III or grade-IV osteochondral lesions (according to the classification system of the International Cartilage Repair Society [ICRS])[20] involving the femoral condyle, with clinical symptoms of pain, swelling, locking, or giving-way.

The medial femoral condyle was involved in fourteen patients and the lateral femoral condyle was involved in four

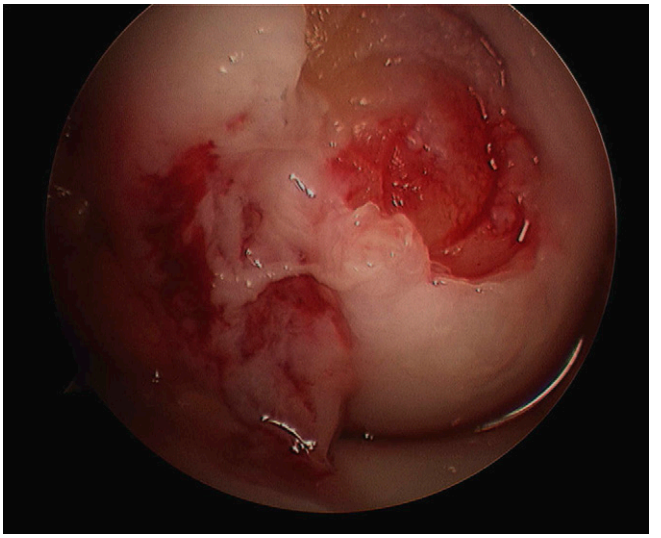

Fig. 5

Arthroscopic view demonstrating a circular area after debridement, with healthy cartilage margins for biomaterial implantation.

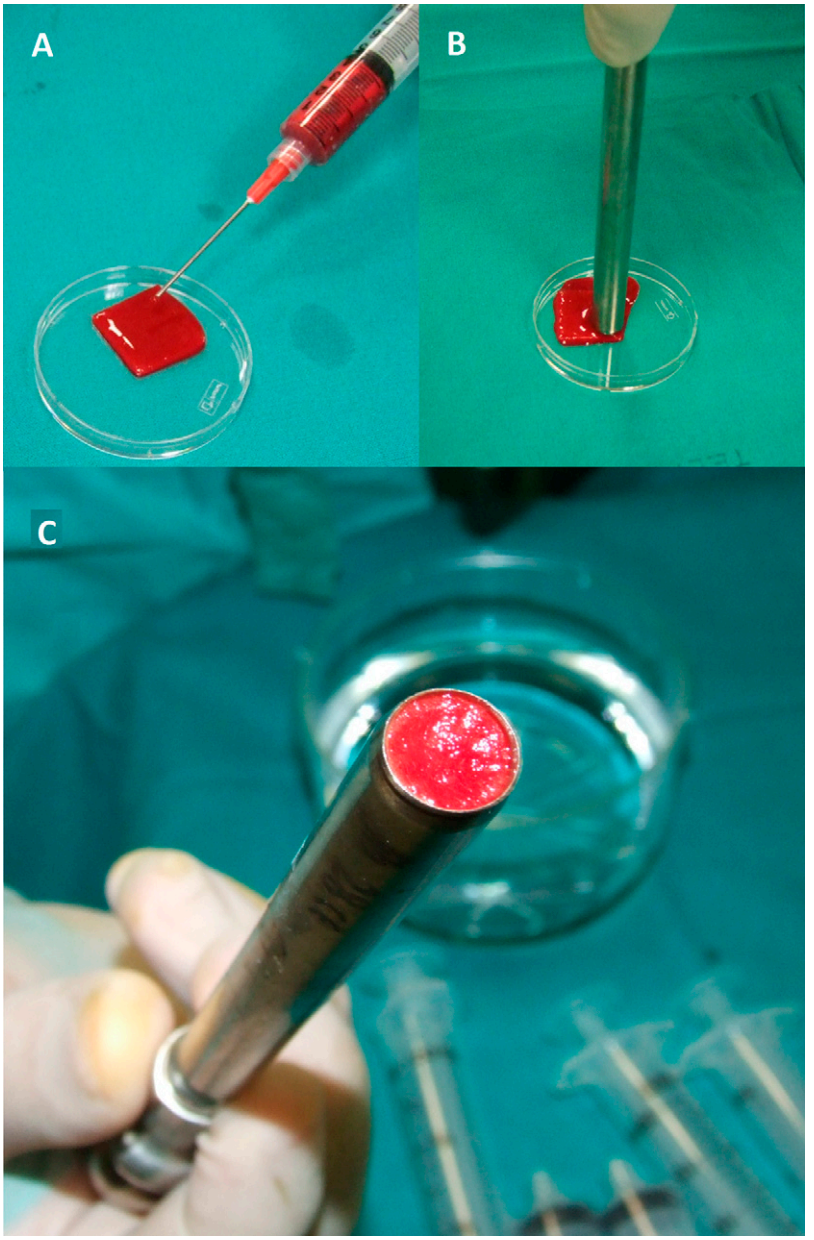


Fig. 6
The scaffold is filled with 2 mL of bone-marrow concentrate (A) and loaded onto the delivery device (B, C). The delivery device was used to cut the scaffold and load the biomaterial. More than one patch may be obtained from each scaffold.

patients. In two patients, both the medial and the lateral femoral condyle had cartilage defects.

Associated comorbidities were meniscal injury in seven (four injuries affecting the medial meniscus and three injuries affecting the lateral meniscus), anterior cruciate ligament injuries in two, femorotibial malalignment in three, and osteophyte presence in three.

A partial meniscectomy was performed in six cases, whereas the meniscus was repaired in one patient. In the patients with anterior cruciate ligament injuries, anterior cruciate ligament reconstruction was accomplished with semitendinosus and gracilis tendon grafts and an "over-the-top" technique. In the three patients who had femorotibial malalignment, a high tibial osteotomy was performed, whereas, in the three patients with osteophytes, the osteophytes were tangentially resected. One patient had a previous surgical procedure for attempted cartilage repair by microfracture.

Exclusion criteria were an age younger than fifteen years or older than fifty years, diffuse osteoarthritis, comorbidities with general medical conditions (e.g., diabetes or rheumatoid

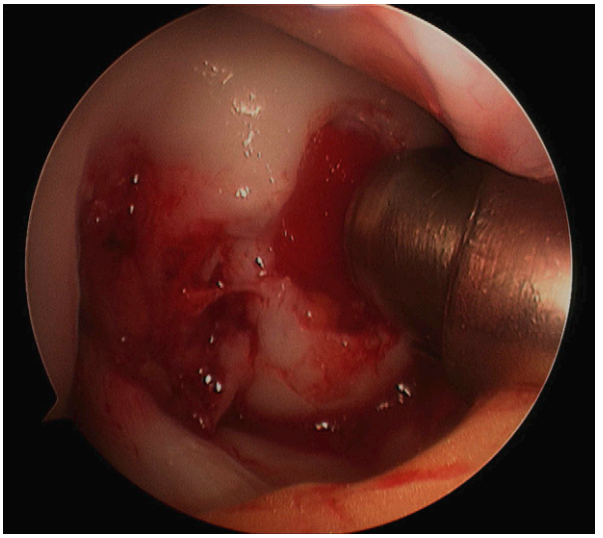

Fig. 7

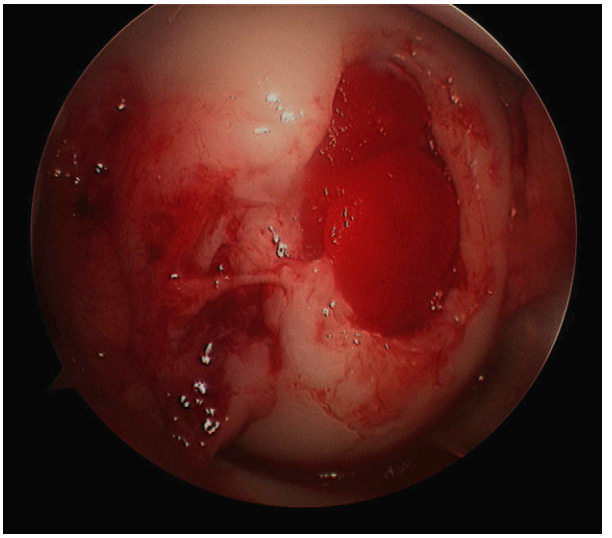

Fig. 8

**Fig. 7** Arthroscopic view of the biomaterial positioned in the cartilage lesion. **Fig. 8** Arthroscopic view of multiple scaffold cuts positioned to fill the entire defect.

arthritis), hematological disorders, and infections. The study protocol was approved by an independent Ethical Committee, and signed informed consent for participation in this investigation was obtained from all of the included patients.

### *Surgical Technique*

#### Platelet Gel Production

120 mL of the patient's venous blood was harvested and processed the day before surgery with use of the Vivostat System (Vivostat, Alleroed, Denmark) in order to provide 6 mL of platelet-rich fibrin gel[19,21,22].

#### Aspiration of Bone Marrow

A total of 60 mL of bone marrow aspirate was harvested from the posterior iliac crest, with the patient positioned prone and under spinal or general anesthesia. The bone-marrow harvesting was performed with a marrow needle (size 11 G × 100 mm) inserted 3 cm deep into the marrow of the iliac crest. Five milliliters of bone marrow was aspirated into a 20-mL plastic syringe that was internally coated with calcium-heparin solution, and the procedure was repeated, with several perforations made into different points in the iliac crest through the same skin opening, until a total of 60 mL of bone marrow

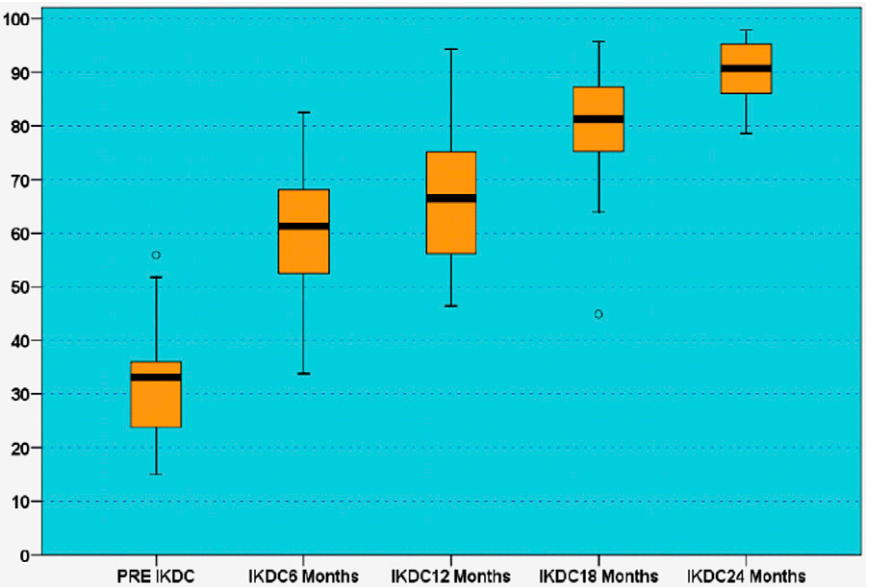


Fig. 9

IKDC evaluation preoperatively and at the time of follow-up showed increased clinical improvement over time.

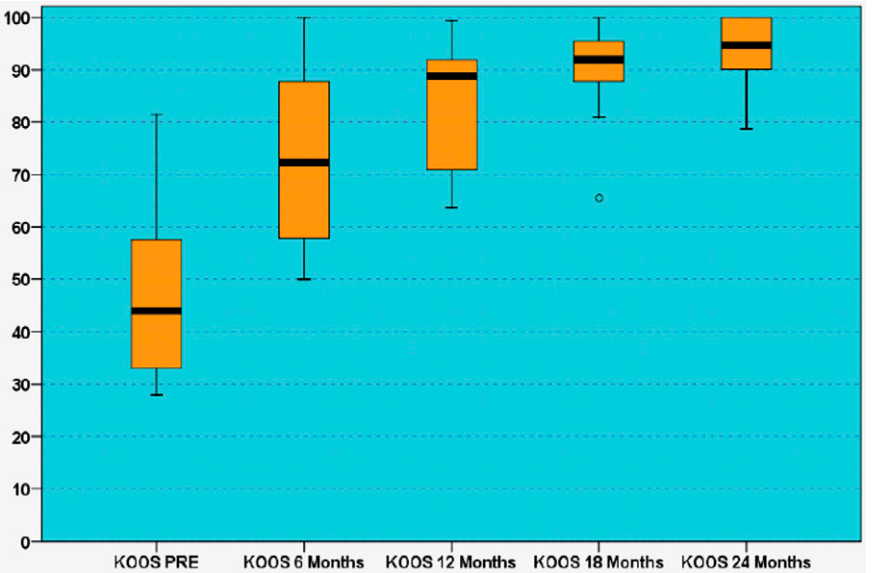


Fig. 10

KOOS evaluation preoperatively and at the time of follow-up showed increased clinical improvement over time.

aspirate was collected. The marrow was aspirated in small fractions from different points to maximize the harvesting of the marrow stromal cells and to reduce dilution by peripheral blood (Fig. 2).

**Concentration of Bone Marrow**

The harvested bone marrow was processed directly in the operating room, by removing most of the erythrocytes and plasma. A cell separator (SmartPReP; Harvest Technologies, Plymouth, Massachusetts), consisting of a centrifuge and a disposable double chamber device, provided 6 mL of concentrate containing nucleated cells after fifteen minutes of multiple centrifugation cycles.

**Transplantation of Arthroscopic Bone-Marrow-Derived Mesenchymal Stem Cells**

After the bone-marrow harvesting phase, a standard knee arthroscopy was performed, with the patient in the supine po-

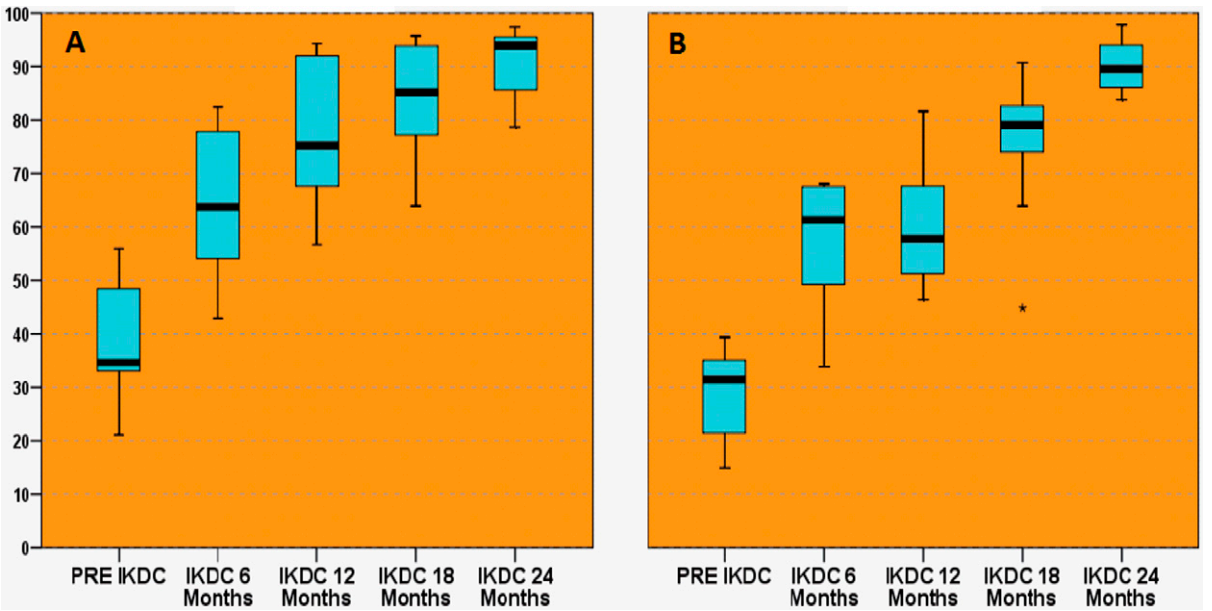


Fig. 11

IKDC outcome in (A) patients with no associated procedures and (B) patients with associated procedures. Associated procedures significantly decreased the IKDC score at twelve months, while no differences were found at the time of final follow-up.

sition. The cartilage lesion was identified (Fig. 3), and a flipped cannula was inserted into the portal ipsilateral to the lesion to enable insertion of the surgical instruments and to retract the fat pad from the operative field[14]. A specifically designed low-profile drill (Fig. 4) was used to debride the lesion, resulting in a circular area with regular healthy cartilage margins for biomaterial implantation (Fig. 5).

A hyaluronic acid membrane (Hyalofast; Fidia Advanced Biopolymers, Abano Terme, Italy) was used for cell support. The scaffold was filled with 2 mL of bone-marrow concentrate (Fig. 6, *A*) and loaded onto the delivery device (Fig. 6, *B* and *C*), which was used to position the biomaterial within the defect (Fig. 7). Multiple stamp-sized pieces of membrane can be overlapped in order to cover the whole area (Fig. 8). A layer of platelet-rich fibrin was finally applied onto the implanted material in order to provide growth factors. The stability of implanted stamps was evaluated from flexion to extension through the arthroscope.

### *Postoperative Treatment*

On the day after surgery, gradual passive and active mobilization of the knee was begun, with no weight-bearing allowed. Four weeks postoperatively, the patient was advanced to muscular reinforcement exercises, closed kinetic-chain proprioceptive rehabilitation, static and walking exercises with partial and gradual weight-bearing, and swimming. Ten weeks after the surgery, the patient advanced to exercises that focused on recovery of muscular function; these included open kinetic-chain rehabilitation exercises, walking with full weight-bearing, and cycling. Six months after the operation, light running was permitted, and, at twelve months postoperatively, the patient was permitted to resume high-impact sports.

### *Follow-up Evaluation*

**Clinical**

Assessment was performed before surgery and at six, twelve, eighteen, and twenty-four months postoperatively; this as-

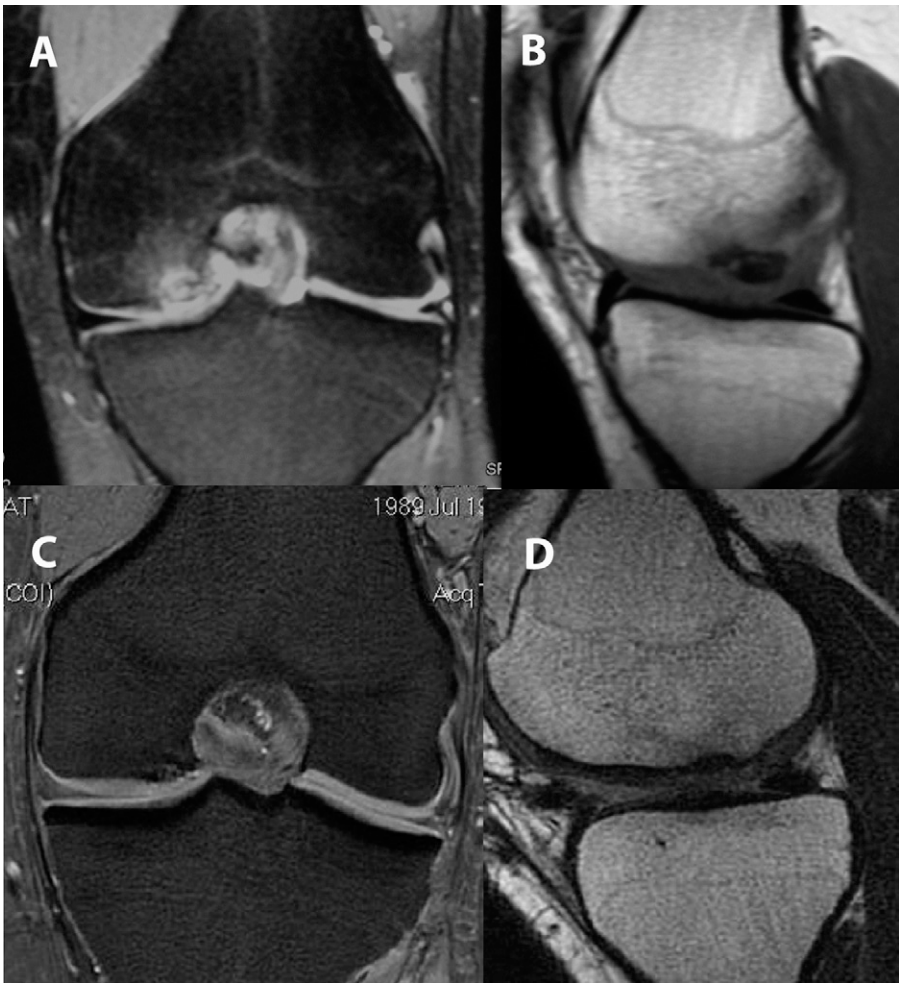


Fig. 12

*A* and *B:* Preoperative magnetic resonance imaging. Fat-saturated proton-density fast-spin-echo coronal view (A) and T1-weighted fast-spin-echo sagittal view (B) of a patient with osteochondritis dissecans of the medial femoral condyle. *C* and *D*: Postoperative magnetic resonance imaging. Fat-saturated proton-density fast-spin-echo coronal view (C) and gradient echo sagittal view (D) of the same patient at the time of follow-up at twenty-four months.

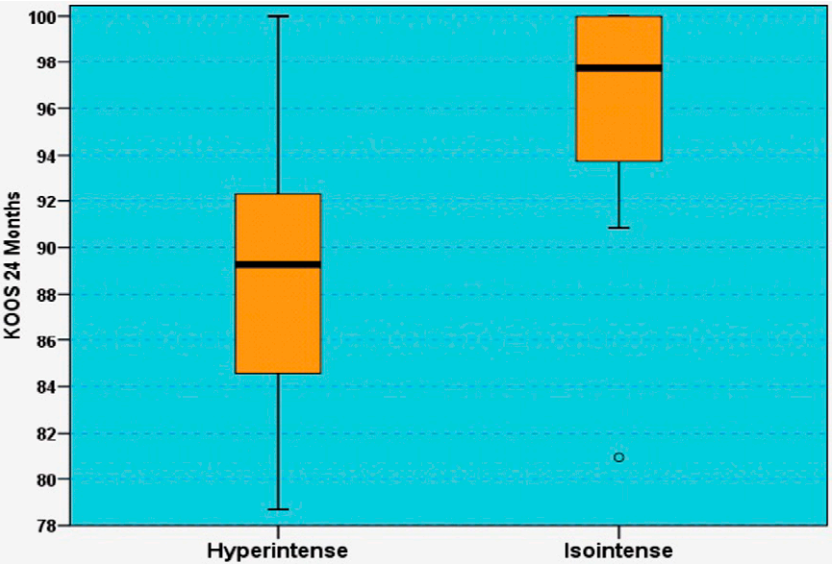


Fig. 13

Patients with a hyperintense signal on magnetic resonance imaging at the time of final follow-up had a lower KOOS score than patients with an isointense signal did.

sessment consisted of clinical evaluation with the International Knee Documentation Committee (IKDC) subjective questionnaire and the Knee Injury and Osteoarthritis Outcome Score (KOOS) questionnaire, which were to be completed by the patients[23,24].

**Magnetic Resonance Imaging**

A magnetic resonance imaging scan was acquired for all patients in the study preoperatively, at six months, at twelve months, and at the time of final follow-up. Imaging sequences were carried out according to the cartilage repair tissue grading scale (the MOCART scoring system)[25].

**Biopsy**

After obtaining approval from the local ethics committee and informed consent from the patients, the first two consecutive patients underwent a second-look arthroscopy and a biopsy twelve months after surgery. The cartilage specimens underwent hematoxylin and eosin and safranin-O staining as well as collagen type-I and II immunohistochemical analyses.

Biopsy samples were fixed in 10% buffered formalin, washed, and decalcified with a 4% HCl, 5% formic acid solution until the sample became decalcified. The samples were then dehydrated through a graded series of alcohols and embedded in paraffin. Four-micrometer-thick sections were obtained from the specimens, and the slides were stored at room temperature until analysis. Slides were stained with 0.001% fast green and 0.1% safranin-O (Sigma, St. Louis, Missouri) to visualize the proteoglycan content of the extracellular matrix and to highlight the presence of hyaline-like tissue, and with hematoxylin and eosin to evaluate the cellular component.

Histochemical analysis was performed with hematoxylin and eosin, safranin-O, and alcian-blue staining, and immunohistochemical analysis was carried out with mouse monoclonal anti-human type-I collagen (MAB1340; Chemicon International, Temecula, California) and mouse monoclonal anti-human type-II collagen antibody (MAB1330; Chemicon International).

For immunohistochemical analyses, the slides were incubated with the primary antibodies to anti-human type-I or type-II collagens diluted 1:20 in 0.04 M Tris-buffered saline solution (pH 7.6) containing 1% bovine serum albumin and 0.1% Triton X-100 for one hour at room temperature. The slides were washed three times with 0.04 M Tris-buffered saline solution (pH 7.6) and incubated with goat anti-mouse and anti-rabbit immunoglobulins labeled with dextran molecules-alkaline phosphatase (EnVision; Dako, Carpinteria, California) at room temperature for thirty minutes. After three washes with 0.04 M Tris-buffered saline solution (pH 7.6), the reactions were developed with use of the new fuchsin kit (New Fuchsin Substrate System, Dako) in the presence of 5 mM levamisole (Sigma) to block endogenous alkaline phosphatase. Negative staining controls were performed either by omitting the primary antibody or by using a control isotype-matched antibody. Slides were counterstained with hematoxylin and mounted in glycerol gel. All of the samples were visualized with a Zeiss Axio Scope microscope (Carl Zeiss, Oberkochen, Germany).

**Statistical Analysis**

The Wilcoxon test, the Mann-Whitney test, and the Student paired t test were used to test for significant differences between baseline and various follow-up measurements. A p value of $<0.05$ was considered significant.

***Source of Funding***

No external funding source was used in this investigation.

**TABLE I Different Parameters of the MOCART Score Were Evaluated at the Final Follow-up**

| Degree of Defect Repair | Integration to the Surrounding Cartilage | Surface of the Repaired Tissue | Structure of the Repaired Tissue | Signal Intensity DPFSE* | Subchondral Lamina | Subchondral Bone | Adhesions | Effusion |
|---|---|---|---|---|---|---|---|---|
| Complete (14) | Complete (16) | Intact (14) | Homogeneous (6) | Isointense (13) | Intact (6) | Intact (6) | No (20) | No (17) |
| Hypertrophy (4) | Incomplete (2) | Damaged (6) | Inhomogeneous (14) | Hyperintense (7) | Not intact (14) | Not intact (14) | Yes (0) | Yes (3) |
| Incomplete (2) | Defect visible (2) | | | Hypointense (0) | | | | |

*DPFSE = proton-density fast-spin-echo magnetic resonance imaging.

## Results

### *Clinical*

The mean IKDC score (and standard deviation) was 32.9 ± 14.2 before surgery and 90.4 ± 9.2 at a mean of 29.0 ± 4.1 months ($p < 0.0005$), while the KOOS score was 47.1 ± 14.9 before surgery and 93.3 ± 6.8 at a mean of 29.0 ± 4.1 months ($p < 0.0005$).

The age of the patient at the time of surgery, the sex of the patient, and the size of the cartilage defect did not affect the results. The clinical improvement was significant with regard to both IKDC and KOOS scores at each follow-up visit, with increased clinical improvement over time (Figs. 9 and 10). Associated procedures significantly decreased the IKDC score at twelve months ($p < 0.0005$), while no differences were found at the time of final follow-up (Fig. 11).

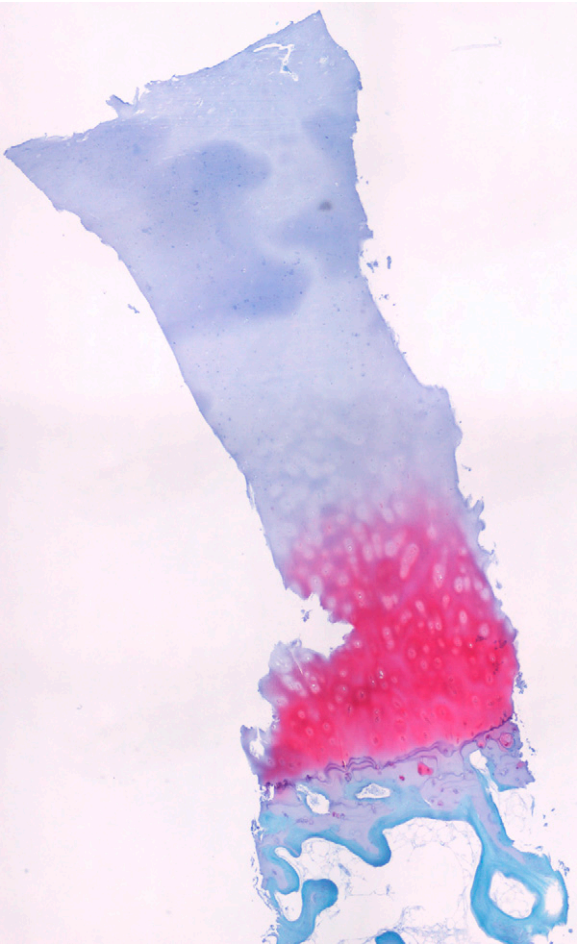

Fig. 14

Safranin-O staining (original magnification, ×40) of one representative case. The extracellular matrix is positive in the medium and deep zones for proteoglycans (in red) while a wide layer of the superficial zone is composed of collagen fibers. The subchondral bone and the tidemark are evident.

### *Imaging*

The control magnetic resonance imaging at the follow-up times of twelve and twenty-four months showed regeneration of the subchondral bone and the cartilaginous tissue in the different parameters of the MOCART score (Fig. 12, Table I).

A significant relationship was found between the KOOS score at twenty-four months and signal intensity ($p < 0.03$). Patients with a hyperintense signal (seven patients) had a mean KOOS score of 89 ± 7 at the twenty-four-month follow-up period, while patients with an isointense signal (thirteen patients) had a mean KOOS score of 96 ± 5 (Fig. 13).

No other significant relationships were found between clinical score and MOCART parameters.

### *Histological Analysis*

Safranin-O staining of the regenerated tissue that was performed at twelve months showed a proteoglycan-rich matrix, particularly in the middle and deep zones. The superficial layer was almost regular. The subchondral bone and the tidemarks were evident (Fig. 14). Hematoxylin and eosin staining showed the presence of cells homogeneously distributed throughout the tissue. In both specimens, immunohistochemical analysis showed a positivity for type-II collagen throughout the entire thickness of the biopsies, while analysis for type-I collagen was negative (data not shown).

### *Complications*

Neither intraoperative nor postoperative complications were observed in this series.

## Discussion

The autologous chondrocyte implantation technique, introduced in 1994 by Brittberg et al., has been proven to

regenerate cartilage tissue with biomechanical properties that are comparable with those of the surrounding healthy cartilage and that are biomechanically superior to the regenerated cartilage induced by other techniques[26-33].

In various studies, reliable and durable clinical results have been reported with use of open-field surgery and, more recently, with use of matrix-based techniques, which permitted evolution to an entirely arthroscopic technique[6-18]. Still, the need for two surgical procedures and the high costs associated with cell expansion have been major drawbacks of autologous chondrocyte implantation, which led to the search for new methods of cartilage repair[34,35].

Mesenchymal stem cells represent 2% to 3% of the total mononuclear cells in bone marrow and have the ability to differentiate into various lineages, including osteoblasts and chondroblasts[36-41]. The rationale of the "one-step technique" is based on the idea of transplanting the entire bone-marrow cellular pool instead of isolated and expanded mesenchymal stem cells[19]. This allows cells to be processed directly in the operating room, without the need for a laboratory phase, and allows bone-marrow-derived mesenchymal stem cell transplantation to be performed in "one step" rather than the two steps that are required for autologous chondrocyte implantation[42-44].

In the present study, the results that we obtained with use of the one-step technique in the repair of osteochondral lesions of the knee closely resemble those obtained with autologous chondrocyte implantation in similar lesions[6,7,13,31].

We found a significant improvement in both the IKDC score and the KOOS score from the time of testing before the operation to the time of testing at each of the follow-up visits ($p < 0.0005$). Patients with associated procedures experienced a delay in clinical improvement between six and twelve months, although the findings at the time of final follow-up were not affected.

Magnetic resonance imaging examination showed satisfactory growth of bone and cartilage, nearly complete defect filling, and satisfactory integration of the graft in 80% of patients at the time of follow-up. Of the various magnetic resonance imaging parameters, only signal intensity was significantly correlated to the KOOS score at the follow-up period of twenty-four months. A larger number of patients may be required in order to further investigate the correlation between magnetic resonance imaging findings and clinical data.

Both the histochemical as well as the immunohistochemical biopsy specimens showed regenerated cartilage tissue in an advanced remodeling phase. Immunohistochemical analysis confirmed the presence of proteoglycans and type-II collagen, which are well-recognized markers of hyaline cartilage. Although the number of patients who were treated was limited, the clinical, imaging, and histological results to date are satisfactory for a high percentage of these patients.

Although further studies with longer follow-up are required to confirm our results, the one-step technique was demonstrated to be a good and reliable option for the treatment of osteochondral lesions of the knee and it overcame the major drawbacks of previous techniques, with comparable clinical results. ■

Roberto Buda, MD
Francesca Vannini, MD, PhD
Marco Cavallo, MD
Brunella Grigolo, PhD
Annarita Cenacchi, MD
Sandro Giannini, MD
II Clinic of Orthopaedics and Traumatology (R.B., F.V., M.C., and S.G.), Laboratory of Immunorheumatology and Tissue Regeneration (B.G.), and Service of Immunohematology and Transfusional Medicine (A.C.), Rizzoli Orthopaedic Institute,
Via G.C. Pupilli 1, 40136, Bologna, Italy.
E-mail address for F. Vannini: france_vannini@yahoo.it

## References

**1.** Widuchowski W, Widuchowski J, Trzaska T. Articular cartilage defects: study of 25,124 knee arthroscopies. Knee. 2007;14:177-82.

**2.** Curl WW, Krome J, Gordon ES, Rushing J, Smith BP, Poehling GG. Cartilage injuries: a review of 31,516 knee arthroscopies. Arthroscopy. 1997;13:456-60.

**3.** Hjelle K, Solheim E, Strand T, Muri R, Brittberg M. Articular cartilage defects in 1,000 knee arthroscopies. Arthroscopy. 2002;18:730-4.

**4.** Papaioannou G, Demetropoulos CK, King YH. Predicting the effects of knee focal articular surface injury with a patient-specific finite element model. Knee. 2010;17:61-8.

**5.** Hangody L, Vásárhelyi G, Hangody LR, Sükösd Z, Tibay G, Bartha L, Bodó G. Autologous osteochondral grafting—technique and long-term results. Injury. 2008;39 Suppl 1:S32-9.

**6.** Ferruzzi A, Buda R, Faldini C, Vannini F, Di Caprio F, Luciani D, Giannini S. Autologous chondrocyte implantation in the knee joint: open compared with arthroscopic technique. Comparison at a minimum follow-up of five years. J Bone Joint Surg Am. 2008;90 Suppl 4:90-101.

**7.** Marcacci M, Kon E, Delcogliano M, Filardo G, Busacca M, Zaffagnini S. Arthroscopic autologous osteochondral grafting for cartilage defects of the knee: prospective study results at a minimum 7-year follow-up. Am J Sports Med. 2007;35:2014-21.

**8.** Gobbi A, Bathan L. Biological approaches for cartilage repair. J Knee Surg. 2009;22:36-44.

**9.** Gobbi A, Nunag P, Malinowski K. Treatment of full thickness chondral lesions of the knee with microfracture in a group of athletes. Knee Surg Sports Traumatol Arthrosc. 2005;13:213-21.

**10.** Peterson L, Brittberg M, Kiviranta I, Akerlund EL, Lindahl A. Autologous chondrocyte transplantation. Biomechanics and long-term durability. Am J Sports Med. 2002;30:2-12.

**11.** Magnussen RA, Dunn WR, Carey JL, Spindler KP. Treatment of focal articular cartilage defects in the knee: a systematic review. Clin Orthop Relat Res. 2008;466:952-62.

**12.** Basad E, Ishaque B, Bachmann G, Stürz H, Steinmeyer J. Matrix-induced autologous chondrocyte implantation versus microfracture in the treatment of cartilage defects of the knee: a 2-year randomised study. Knee Surg Sports Traumatol Arthrosc. 2010;18:519-27.

**13.** Hangody L, Ráthonyi GK, Duska Z, Vásárhelyi G, Füles P, Módis L. Autologous osteochondral mosaicplasty. Surgical technique. J Bone Joint Surg Am. 2004;86 Suppl 1:65-72.

**14.** Marcacci M, Kon E, Zaffagnini S, Filardo G, Delcogliano M, Neri MP, Iacono F, Hollander AP. Arthroscopic second generation autologous chondrocyte implantation. Knee Surg Sports Traumatol Arthrosc. 2007;15:610-9.

**15.** Kon E, Gobbi A, Filardo G, Delcogliano M, Zaffagnini S, Marcacci M. Arthroscopic second-generation autologous chondrocyte implantation compared with microfracture for chondral lesions of the knee: prospective nonrandomized study at 5 years. Am J Sports Med. 2009;37:33-41.

**16.** Nehrer S, Domayer S, Dorotka R, Schatz K, Bindreiter U, Kotz R. Three-year clinical outcome after chondrocyte transplantation using a hyaluronan matrix for cartilage repair. Eur J Radiol. 2006;57:3-8.

**17.** Ossendorf C, Kaps C, Kreuz PC, Burmester GR, Sittinger M, Erggelet C. Treatment of posttraumatic and focal osteoarthritic cartilage defects of the knee with autologous polymer-based three-dimensional chondrocyte grafts: 2-year clinical results. Arthritis Res Ther. 2007;9:R41.

**18.** Selmi TA, Verdonk P, Chambat P, Dubrana F, Potel JF, Barnouin L, Neyret P. Autologous chondrocyte implantation in a novel alginate-agarose hydrogel: outcome at two years. J Bone Joint Surg Br. 2008;90:597-604.

**19.** Giannini S, Buda R, Vannini F, Cavallo M, Grigolo B. One-step bone marrow-derived cell transplantation in talar osteochondral lesions. Clin Orthop Relat Res. 2009;467:3307-20.

**20.** Mainil-Varlet P, Aigner T, Brittberg M, Bullough P, Hollander A, Hunziker E, Kandel R, Nehrer S, Pritzker K, Roberts S, Stauffer E; International Cartilage Repair Society. Histological assessment of cartilage repair: a report by the Histology Endpoint Committee of the International Cartilage Repair Society (ICRS). J Bone Joint Surg Am. 2003;85 Suppl 2:45-57.

**21.** Buda R, Vannini F, Grigolo B, Cenacchi A, Di Caprio F, Giannini S. Ingegneria tissutale: tecnica chirurgica. Giornale Italiano di Ortopedia e Traumatologia. 2007; 33(Suppl 1):S215-22.

**22.** Buda R, Di Caprio F, Cavallo M, Ruffilli A, Giannini S. Artroscopia della tibiotarsica: ankle arthroscopy. Giornale Italiano di Ortopedia e Traumatologia. 2009; 35(Suppl 1):S221-5.

**23.** Irrgang JJ, Anderson AF, Boland AL, Harner CD, Kurosaka M, Neyret P, Richmond JC, Shelborne KD. Development and validation of the International Knee Documentation Committee subjective knee form. Am J Sports Med. 2001;29:600-13.

**24.** Roos EM, Roos HP, Lohmander LS, Ekdahl C, Beynnon BD. Knee Injury and Osteoarthritis Outcome Score (KOOS)—development of a self-administered outcome measure. J Orthop Sports Phys Ther. 1998;28:88-96.

**25.** Welsch GH, Mamisch TC, Quirbach S, Zak L, Marlovits S, Trattnig S. Evaluation and comparison of cartilage repair tissue of the patella and medial femoral condyle by using morphological MRI and biochemical zonal T2 mapping. Eur Radiol. 2009; 19:1253-62.

**26.** Brittberg M, Winalski CS. Evaluation of cartilage injuries and repair. J Bone Joint Surg Am. 2003;85 Suppl 2:58-69.

**27.** Brittberg M, Lindahl A, Nilsson A, Ohlsson C, Isaksson O, Peterson L. Treatment of deep cartilage defects in the knee with autologous chondrocyte transplantation. N Engl J Med. 1994;331:889-95.

**28.** Brittberg M, Tallheden T, Sjögren-Jansson B, Lindahl A, Peterson L. Autologous chondrocytes used for articular cartilage repair: an update. Clin Orthop Relat Res. 2001;391 Suppl:S337-48.

**29.** Petersen L, Brittberg M, Lindahl A. Autologous chondrocyte transplantation of the ankle. Foot Ankle Clin. 2003;8:291-303.

**30.** Peterson L, Minas T, Brittberg M, Nilsson A, Sjögren-Jansson E, Lindahl A. Two- to 9-year outcome after autologous chondrocyte transplantation of the knee. Clin Orthop Relat Res. 2000;374:212-34.

**31.** Kon E, Verdonk P, Condello V, Delcogliano M, Dhollander A, Filardo G, Pignotti E, Marcacci M. Matrix-assisted autologous chondrocyte transplantation for the repair of cartilage defects of the knee: systematic clinical data review and study quality analysis. Am J Sports Med. 2009;37 Suppl 1:156S-66S.

**32.** Kon E, Delcogliano M, Filardo G, Montaperto C, Marcacci M. Second generation issues in cartilage repair. Sports Med Arthrosc. 2008;16:221-9.

**33.** Henderson I, Lavigne P, Valenzuela H, Oakes B. Autologous chondrocyte implantation: superior biologic properties of hyaline cartilage repairs. Clin Orthop Relat Res. 2007;455:253-61.

**34.** Lindahl A, Brittberg M, Peterson L. Health economics benefits following autologous chondrocyte transplantation for patients with focal chondral lesions of the knee. Knee Surg Sports Traumatol Arthrosc. 2001;9:358-63.

**35.** Minas T. Chondrocyte implantation in the repair of chondral lesions of the knee: economics and quality of life. Am J Orthop (Belle Mead NJ). 1998;27:739-44.

**36.** Bosnakovski D, Mizuno M, Kim G, Takagi S, Okumura M, Fujinaga T. Chondrogenic differentiation of bovine bone marrow mesenchymal stem cells (MSCs) in different hydrogels: influence of collagen type II extracellular matrix on MSC chondrogenesis. Biotechnol Bioeng. 2006;93:1152-63.

**37.** Dominici M, Pritchard C, Garlits JE, Hofmann TJ, Persons DA, Horwitz EM. Hematopoietic cells and osteoblasts are derived from a common marrow progenitor after bone marrow transplantation. Proc Natl Acad Sci U S A. 2004;101:11761-6.

**38.** Kacena MA, Gundberg CM, Horowitz MC. A reciprocal regulatory interaction between megakaryocytes, bone cells, and hematopoietic stem cells. Bone. 2006;39:978-84.

**39.** Longobardi L, O'Rear L, Aakula S, Johnstone B, Shimer K, Chytil A, Horton WA, Moses HL, Spagnoli A. Effect of IGF-I in the chondrogenesis of bone marrow mesenchymal stem cells in the presence or absence of TGF-beta signaling. J Bone Miner Res. 2006;21:626-36.

**40.** Lucarelli E, Beccheroni A, Donati D, Sangiorgi L, Cenacchi A, Del Vento AM, Meotti C, Bertoja AZ, Giardino R, Fornasari PM, Mercuri M, Picci P. Platelet-derived growth factors enhance proliferation of human stromal stem cells. Biomaterials. 2003;24:3095-100.

**41.** Olmsted-Davis EA, Gugala Z, Camargo F, Gannon FH, Jackson K, Kienstra KA, Shine HD, Lindsey RW, Hirschi KK, Goodell MA, Brenner MK, Davis AR. Primitive adult hematopoietic stem cells can function as osteoblast precursors. Proc Natl Acad Sci U S A. 2003;100:15877-82.

**42.** Taichman RS. Blood and bone: two tissues whose fates are intertwined to create the hematopoietic stem-cell niche. Blood. 2005;105:2631-9.

**43.** Capone C, Frigerio S, Fumagalli S, Gelati M, Principato MC, Storini C, Montinaro M, Kraftsik R, De Curtis M, Parati E, De Simoni MG. Neurosphere-derived cells exert a neuroprotective action by changing the ischemic microenvironment. PLoS One. 2007;2:e373.

**44.** Lepore AC, Han SS, Tiler-Polsz CJ, Cai J, Rao MS, Fischer I. Differential fate of multipotent and lineage-restricted neural precursors following transplantation into the adult CNS. Neuron Glia Biol. 2004;1:113-26.